






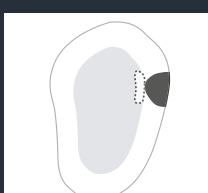

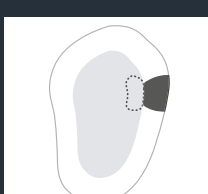
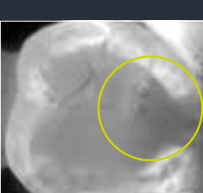



KaVo DIAGNOcam. Classification and findings.



KaVo DIAGNOcam. Classification of findings.

Description	DIAGNOcam	Clinical extent	Therapy recommendation
Healthy tooth surface.			Monitoring and prevention.
First signs of approximal enamel caries.			Caries monitoring and prevention.
Established approximal enamel caries.			Caries monitoring and prevention.
Approximal enamel caries with contact with enamel-dentine border.			Caries monitoring and prevention.
Approximal dentine caries with surface enamel-dentine border contact.			(Minimally) invasive procedure*.
Advanced approximal dentine caries.			Invasive procedure*.

(possibly achieved by dentine extension)

* Additional bitewing radiographs are useful to assess the extent of the caries in the dentine. Prevention: Plaque control, fluoride application, caries infiltration, etc.

KaVo DIAGNOcam. Clinical findings.

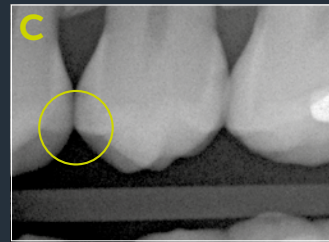
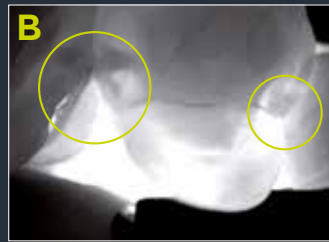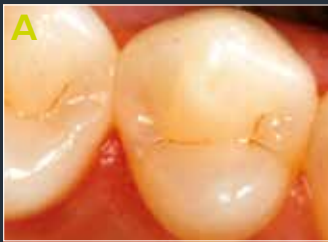Initial findings

DIAGNOcam

X-ray

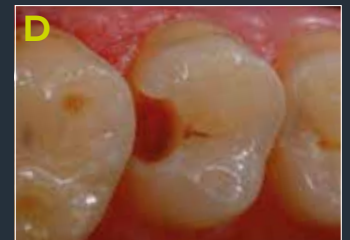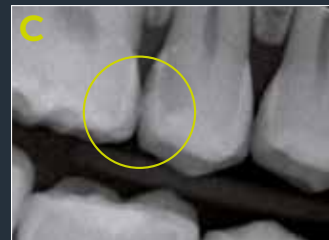
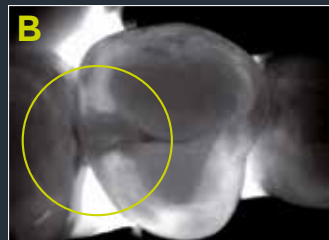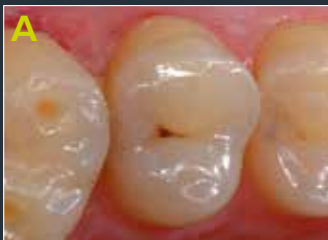Therapy

Approximal caries diagnostics on an existing premolar.



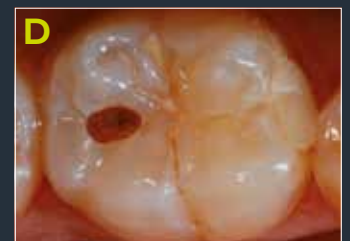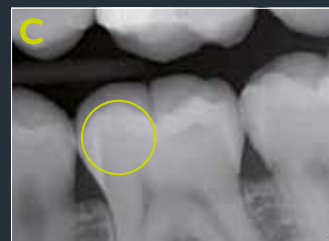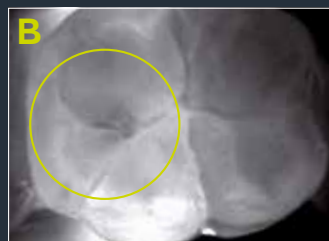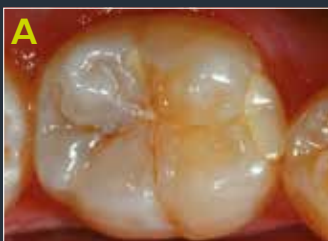A The clinical situation shows a caries-free premolar. With the DIAGNOcam, an enamel caries without involvement of the enamel-dentine border can be diagnosed on the mesial and distal surfaces (**B**). While the corresponding bitewing X-ray radiographs cannot be evaluated on the mesial surface based on the imaging conditions, the image signals an enamel caries on the distal surface (**C**). Alongside preventive support measures, caries monitoring is indicated with the help of the DIAGNOcam procedure (**D**).

Approximal caries diagnostics on an existing premolar.



A The clinical examination of premolar 15, apart from occlusal brown discoloration, does not identify any carious process. DIAGNOcam image **B**, however, shows a distal broad shadow which has already reached the enamel-dentine border. Bitewing X-ray radiograph **C** signals a carious process up to the inner dentine half. Both diagnosed lesion expansions are confirmed after opening the carious process during filling treatment (**D**).

Occlusal caries diagnostics on an existing molar (hidden caries)



A The visual examination of the occlusal surface of tooth 46 does not provide any definite evidence of the presence of discoloration or similar caused by caries. In DIAGNOcam image **B**, a shadow can be determined in the distal region of the central fissure, which is also imposed on X-ray image **C** as translucency. After opening the carious process (**D**), carious dentine can be seen.

KaVo DIAGNOcam. Clinical findings.

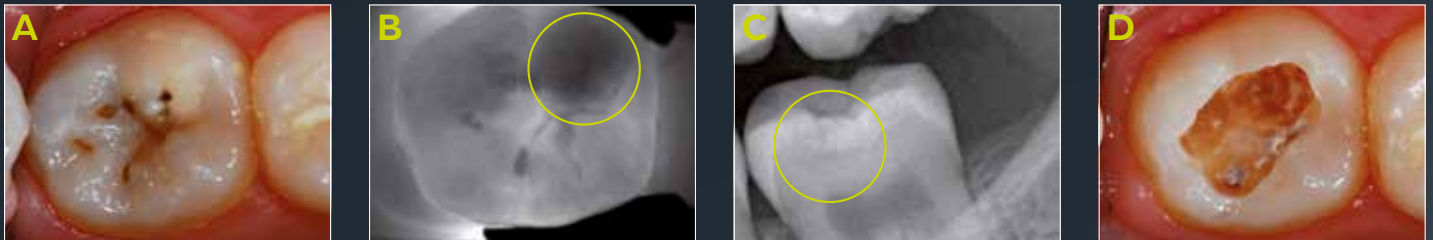
Initial findings

DIAGNOcam

X-ray

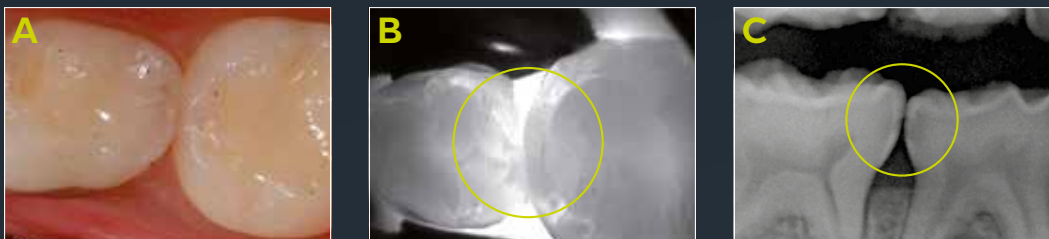Therapy

Occlusal caries diagnostics on an existing molar (hidden caries).



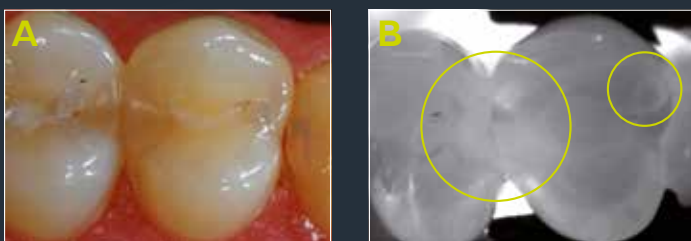
A Tooth 37 shows an established occlusal carious lesion with several localised enamel breaks. Demineralisation can be seen in the region of the mesiobuccal cusp which is imposed on DIAGNOcam image **B** as a dark shadow. **C** The corresponding X-ray image shows an advanced dentine lesion. **D** After opening the carious process, the active lesion and an undermining caries expansion can be observed.

Approximal caries diagnostics on two deciduous molars.



A The clinical examination of the approximal space between 74 and 75 demonstrates a carious process distal to 74. In DIAGNOcam image **B**, shadows can be seen mesial to 75 and distal to 74 with involvement of the enamel-dentine border. The very dark enamel layer and reduced transillumination due to resorption processes make diagnosing deciduous teeth difficult. In X-ray image **C**, a carious process with dentine involvement can be observed on both teeth.

Fissure sealant and composite filling on an initially existing molar.



A The expanded fissure sealant on tooth 36 is shown as a significantly demarcated opaque shadow in DIAGNOcam image **B**. At the mesiolingual cusp a composite filling can be seen in **A**, which is imposed on DIAGNOcam image **B** as a demarcated shadow.

Ludwig Maximilian University of Munich, 2013