

GC get connected

Your product and innovation update



2023

WORKFLOW SPECIAL

Solved with GC!



Since 1921
100 years of Quality in Dental

Contents

1. Solved with GC!	3
2. The 'MI' workflow	4
3. The 'direct anterior' workflow	6
4. The 'direct posterior' workflow	8
5. The 'prosthetic' workflow	10
6. The 'universal' workflow	12

Dear reader,

We are happy you decided to connect with us again! We have prepared a very special experience for you focusing on providing efficient, solution-oriented treatment workflows. You can catch a glimpse of these workflows, together with dedicated articles and clinical applications to navigate protocols. in this magazine.

We'd also like to take the opportunity to present a new approach within the daily adhesive protocol: GC's universal self-adhesive resin luting G-CEM ONE, which can now be combined with our popular universal bonding agent G-Premio BOND. This providing even more options and possibilities, requiring in future one bonding agent for any direct and indirect indication only.

GC is proud to announce furthermore the introduction of new Initial LiSi Block shades, for the fully crystallized lithium disilicate CAD/CAM Block. The new shades, A3.5 HT, A3.5 LT and Bleach are launched responding directly to customers' request.

I invite you to check out our workflows and treatment solutions, which will bridge frontiers and further connect for success!



Josef Richter

Chief Operating Officer & President
GC Europe AG



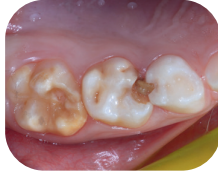Solved with GC!

By focusing on solutions rather than problems, GC helps dentists achieve success with greater efficiency and predictability. By designing products that enable simplified use, we can help you reduce your working time without compromising the final result.

As icing on the cake: all of our products are optimally coordinated. When used in combination, you take full advantage of our solution concepts.

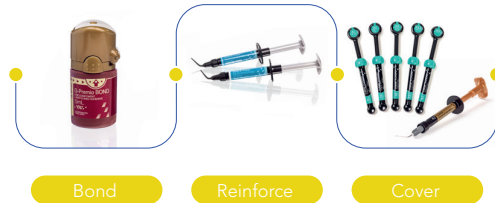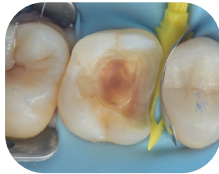Tired of repair and repeat?

Don't enter the vicious cycle, use our **MI solutions**



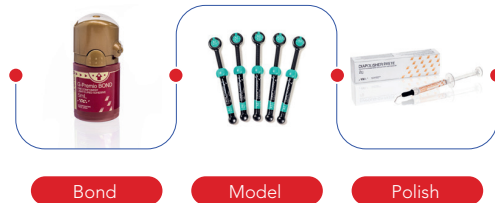
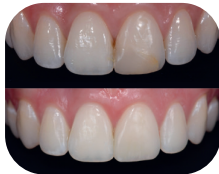Direct or Indirect? That's the question

Our **direct posterior solutions** bridge that tipping point



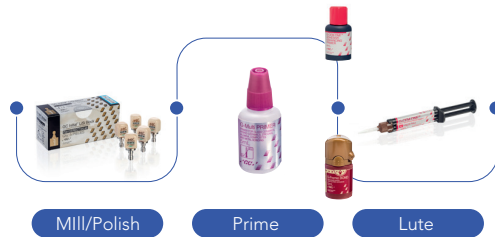
Simply craving a beautiful smile?

Achieve outstanding aesthetic results with our **direct anterior solutions**



Too much to restore, too little time?

Gain time with our **prosthetic solutions**



Want to save some space?

Cut the excess with our **universal adhesive solutions**

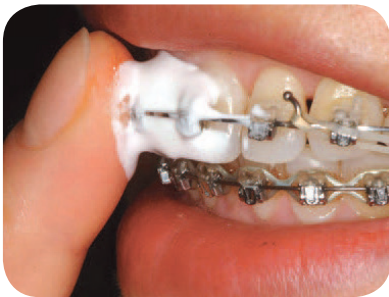
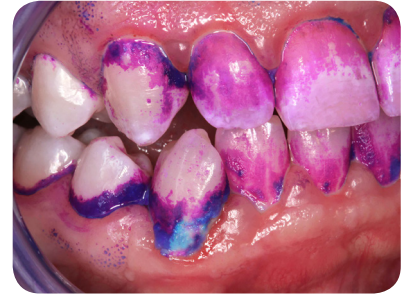
Tired of repair and repeat?

Don't enter the vicious cycle, use our **MI solutions**

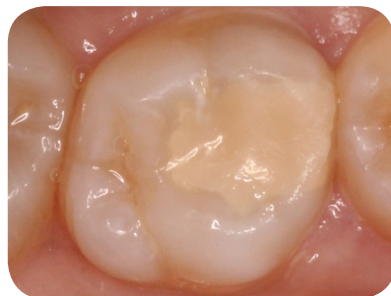1 Identify with GC Tri Plaque ID Gel

- ✓ Identify risk areas
- ✓ Increase patient compliance



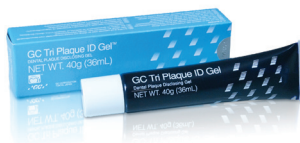2 Prevent with GC MI Paste Plus / GC Tooth Mousse

- ✓ Prevent caries in synergy with fluoride
- ✓ Supply bio-available minerals



3 Restore with EQUIA Forte HT

- ✓ Simple, minimally invasive procedure
- ✓ Cost-effective and durable



GC Tri Plaque ID Gel
Three-tone plaque disclosing gel



**GC MI Paste Plus/
GC Tooth Mousse**
Bio-available calcium and
phosphate, with/without fluoride



EQUIA Forte HT
Bulk fill glass hybrid
long-term restorative system

Solved with GC!





Dr. Khaled Aly Nour



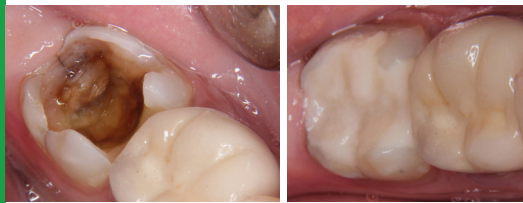Scan or click to read the full article

The SmART restorative solution: a case series.

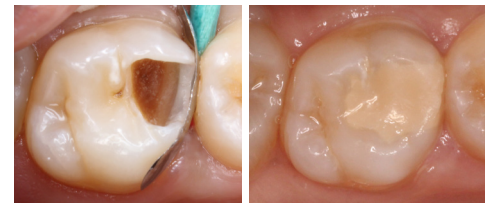By Dr Khaled Aly Nour, Egypt

The only two tools in the clinician's hand to improve the success of his treatments are: 1) the wise selection of the most suitable line of treatment and 2) his ability to manipulate the restoratives involved in a way to maximize its benefits and minimize its deficiencies.

In various clinical situations, a glass hybrid would be the wisest choice in view of the available evidence currently present in the dental literature. Choices are based on the benefits versus the costs, in terms of money and efforts as well as dental tissues.



Case: Dr Amr El-Deeb



Case: Dr Mona Galal

Amalgam: gone for good?

By Prof. Falk Schwendicke, Germany

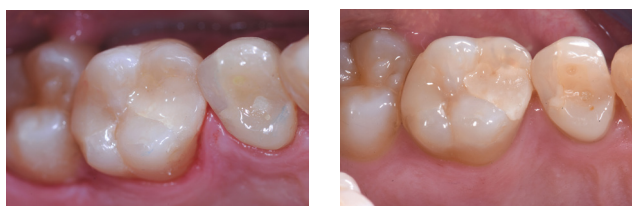For about a century, dental amalgam has been the standard restorative material for posterior caries lesions. Given the ease of placement, particularly its moisture tolerance, but also its relatively high resistance against masticatory forces and secondary caries, it remains the restorative standard in most statutory or public health insurances until today. There is not a single material fulfilling all requirements to completely replace amalgam; instead, a range of materials with different properties are available. Resin composites have a long tradition in direct restoratives, with excellent physical properties, but require a number of prerequisites and are technically demanding. Glass ionomers and glass hybrids have shown a considerable evolution over the last two decades. Evidence supports the usage of glass hybrids for both cervical and posterior load-bearing restorations, and their cost-effectiveness and applicability of these materials is likely superior to that of other materials. It is no surprise that the World Health Organisation (WHO) already considers glass ionomers and glass hybrids as "essential medicines".



Prof. Falk Schwendicke



Scan or click to read the full article



EQUIA Forte restoration at baseline (left) and after 5 years (right).
Case: Prof. M. Basso

Simply craving a beautiful smile?

Achieve outstanding aesthetics with our **direct anterior solutions**

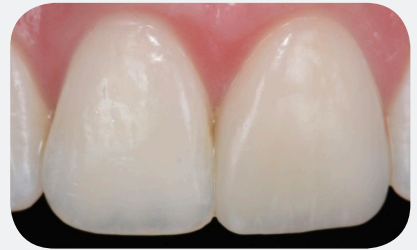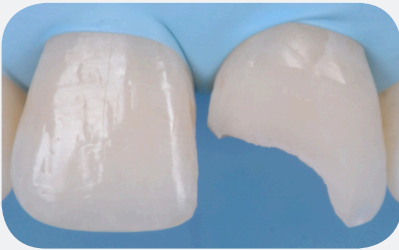
1 Bond with G-Premio BOND



- ✓ Clean application
- ✓ 300 drops/bottle
- ✓ Universal application and indications

2 Model with G-ænial A'CHORD

- ✓ Brilliant shade matching
- ✓ Easy handling with a brush or instrument



3

Polish in no time

- ✓ Easily achieved with DiaPolisher Paste
- ✓ High gloss retention



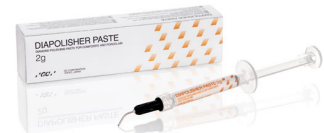G-Premio BOND

One component light-cured universal adhesive



G-ænial A'CHORD


Light-cured universal restorative composite



DiaPolisher Paste

Diamond polishing paste for composite and porcelain

Solved with GC!





Dr Andrew Chio



Dr Anthony Mak



Scan or click
to read the
full article



Dr. Javier Tapia Guadix

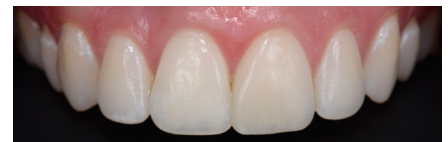
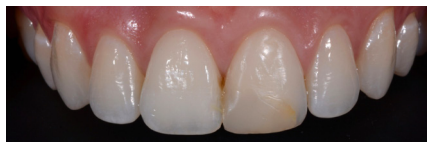
Scan or click
to watch
the interview

Class IV restoration with direct composite resin: A case study utilizing the layering-stratification technique with the G-ænial A'CHORD composite system

By Dr Anthony Mak and Dr Andrew Chio, Australia

The following case study demonstrates the use of the G-ænial A'CHORD (GC Europe) direct composite system in the restoration of a complex Class IV in a 22-year-old female patient. Pre-operatively, a thorough aesthetic assessment took place because this concerned the chief complaint of the patient, including thorough assessments of smile architecture and colour. Treatment options were discussed and the tooth was restored using composites with different opacities and a fluorescence level similar to natural teeth to achieve a natural optical blending effect.



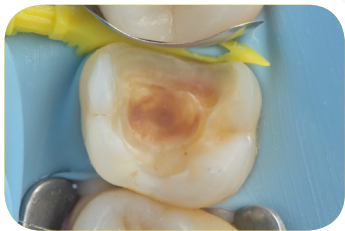Choosing the right shade for your restoration

By Dr Javier Tapia Guadix, Spain

Usually, the shade determination begins with comparing different areas of the tooth with the Vita shade guide. Despite its enormous popularity, one must keep in mind that the VITA shade guide was originally designed for metal-ceramic restorations. Other helpful tools are a custom shade guide, the composite button technique and polarized images. During the process, it's important to keep the patient's age in mind as the tooth shade tends to vary with age. Shade matching remains a difficult task. Composites exist, that really blend in and partially take the colour of the substrate due to their scattering ability, so that the entire VITA shade range can be covered with a few core shades. These materials are very helpful in obtaining a nice shade for your restorations.

Direct or Indirect? That's the question

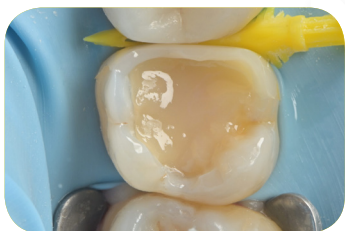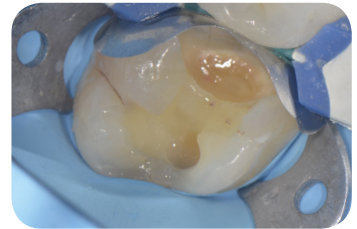
Our **direct posterior solutions** bridge that tipping point



1

Bond with **G-Premio BOND**

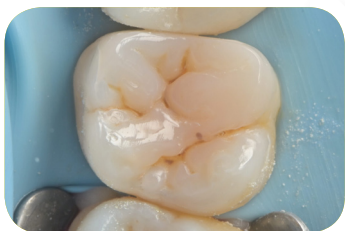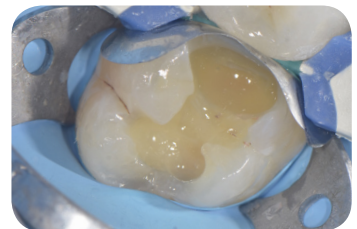
- ✓ Universal application and indications



2

Reinforce with **everX Flow**

- ✓ Strengthen your restoration from within

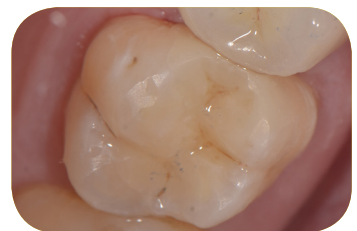

3

Cover

with **G-ænial A'CHORD**

- ✓ Easy shade matching with only 5 core shades



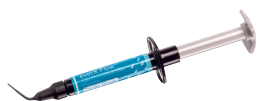with **G-ænial Universal Injectable**

- ✓ Reach every area with our strongest composite



G-Premio BOND

One component light-cured universal adhesive



everX Flow

Short-fibre reinforced flowable composite



G-ænial Universal Injectable

High-strength restorative composite



G-ænial A'CHORD

Light-cured universal restorative composite

Solved with GC!





Dr. Radoslav Asparuhov



Scan or click
to read the
full article



Dr. Stephane Browet

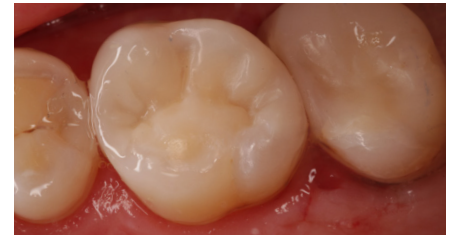
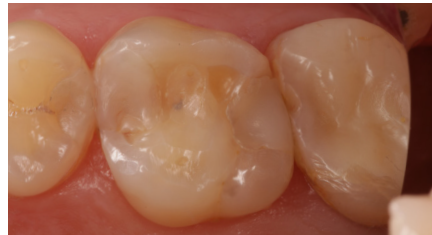
Scan or click
to watch
the interview

Restoration of proximal caries lesions in the posterior area with tight proximal contacts

By Dr Radoslav Asparuhov, Bulgaria

A patient consulted the dental office because of food impaction and moderate pain when eating sweet or sour food. The dentist discovered a large MOD restoration with discoloured margins and secondary caries, which needed replacement. Direct posterior proximal restorations can be a real challenge for the dentist. With pre-wedging, sectional matrices, centripetal build-up technique, fibre reinforcement and cusp-by-cusp coverage with a universal composite, the dentist managed to create a tight contact point to remedy the food impaction.



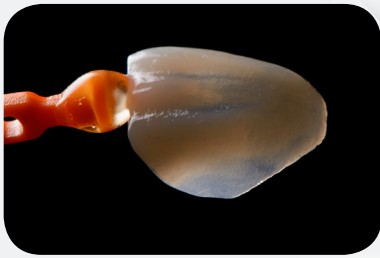Chasing cracks and deciding how to intervene

By Dr Stephane Browet, Belgium

Cracks in teeth are quite common and show a lot of variety related to the crack position and degree, which can make a correct diagnosis very hard. One of the main questions regarding an observed tooth crack is whether or not to intervene... and when. Detecting cracks starts with visual inspection; high magnification is hereby a must as it helps to judge the size, depth and width of the crack line. With D-Light Pro in the detection mode, colour response and integrity of the substrate can be verified; the third step is to use detecting dye (e.g. GC TriPlaque ID Gel) to determine if there is biofilm present in the crack line. The mix of D-Light Pro with the GC TriPlaque ID Gel gives the best outcomes in checking the integrity of the substrate. After treatment, recurrence should of course be avoided: here, everX Flow is of great help to deflect and stop cracks.

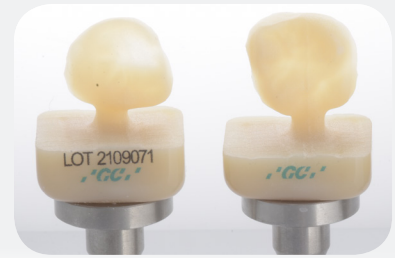Too much to restore, too little time?

Gain time with our **prosthetic solutions**

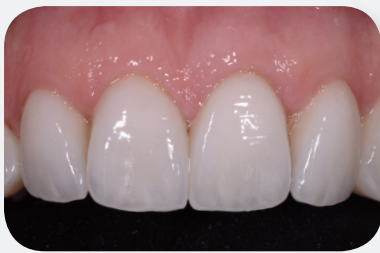

1 Mill
with **Initial LiSi Block**

- ✓ Gain time: no firing needed
- ✓ Thin, accurate margins

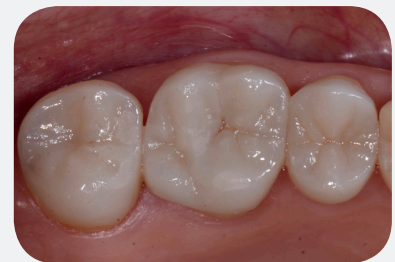

2 Optional: enhanced adhesion with **G-CEM ONE Adhesive Enhancing Primer** or **G-Premio BOND**



3 Lute
with **G-CEM ONE**

- ✓ Sets in 4 minutes only
- ✓ Universal indications



Pictures: courtesy of Dr. J. Tapia Guadix, Spain (top left), Prof. R. Sorrentino, Italy (bottom left) and Dr. C. Mazzitelli, Italy (right)



Initial LiSi Block
Fully crystallised lithium disilicate CAD/CAM Block



G-Premio BOND
One-component light-cured universal adhesive



G-CEM ONE AEP
Adhesive enhancing primer



G-CEM ONE
Universal dual-cured composite resin cement

Solved with GC!





Dr. Federico Del Bianco Dr. Claudia Mazzitelli



Scan or click to read the full article



Dr. Hendrik Zellerhoff



Scan or click to read the full article

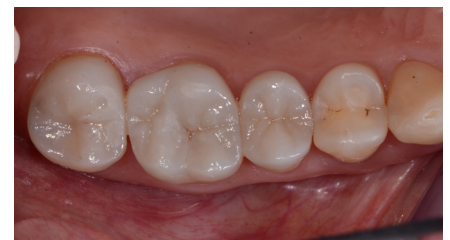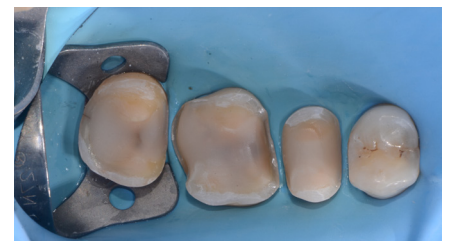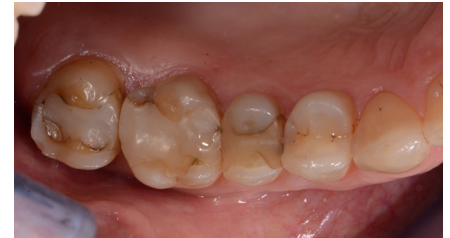The beauty of one simple solution for day-to-day procedures.

By Dr Federico Del Bianco and Dr Claudia Mazzitelli, Italy

A patient consulted because she felt discomfort during chewing and sensitivity to cold in the first quadrant (more specifically, teeth 15, 16 and 17). Cracks and marginal observation were found, as well as recurrent caries that was visible on the radiograph.

The teeth were prepared, sealed and scanned. Partial crowns were milled from Initial LiSi Blocks (fully crystallized lithium disilicate) and polished to high gloss with low speed and light pressure – no firing was necessary. The restorations were cemented with a universal, dual-cure self-adhesive resin cement G-CEM ONE.

Products with universal indications and a wide indication range offer many benefits. Initial LiSi Block and G-CEM ONE allow to simplify the workflow and reduce the inventory, while maintaining qualitative and reliable results.

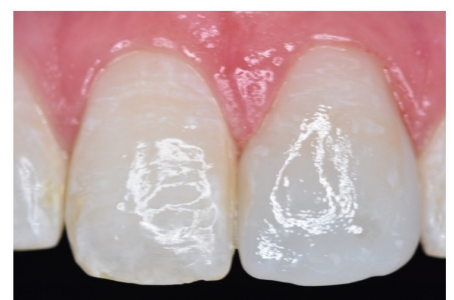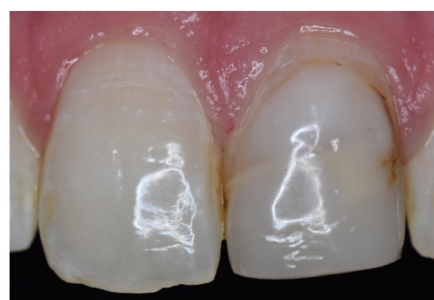


Single-visit, all-ceramic anterior tooth restorations in the dental practice.

By Dr Hendrik Zellerhoff, Germany

The patient's desire for "fast" and aesthetic restorations is increasing in everyday practice. Many patients are well informed and aware of the possibilities of digital dentistry or chairside treatment.

This patient needed tooth 21, endodontically treated, to be restored and requested explicitly to have it finished in a single appointment. This wish could be granted due to a time-efficient, chairside CAD/CAM workflow. In cases like these, the choice of materials is crucial. The neighbouring teeth with manifold colour variance posed great aesthetic challenges, but Initial LiSi Block convinced with its natural opalescence and harmonious shade effect. The before and after pictures show the potential: the difficult colour structure could be optimally reproduced. Within a very short time and in just one appointment, the patient could be taken care of.

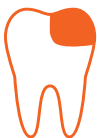

Want to save some space?

Cut the excess with our **universal adhesive solutions**

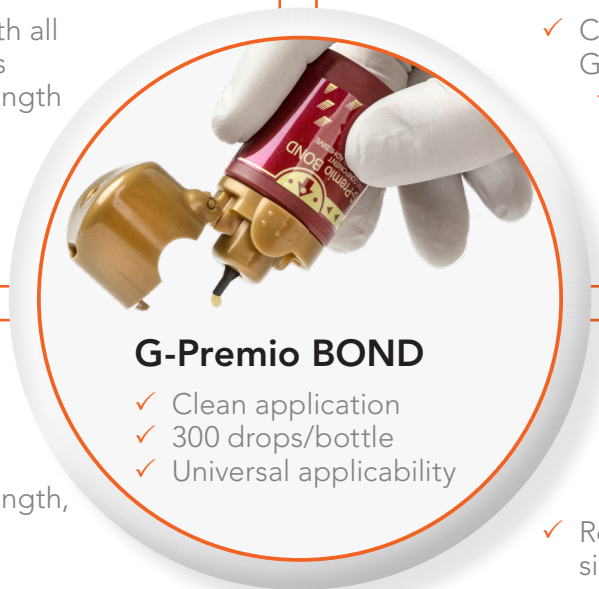Restore

- ✓ Compatible with all GC composites
- ✓ High bond strength in all etching modes



Lute

- ✓ Compatible with all GC resin cements
- ✓ Very low film thickness



G-Premio BOND

- ✓ Clean application
- ✓ 300 drops/bottle
- ✓ Universal applicability

Build up cores

- ✓ Optional dual cure mode available
- ✓ High bond strength, even in bulk-fill application



Repair

- ✓ Suitable for direct and indirect restorations
- ✓ Repair in simple steps



G-Premio BOND

One component light-cured universal adhesive



GC composite range

Light-cured restorative composites



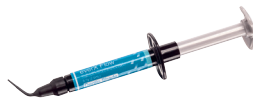G-CEM ONE

Universal dual-cured composite resin cement



GRADIA CORE

Dual-cure composite for core build-up & post cementation



everX Flow


Short-fibre reinforced flowable composite



Repair kit

Chairside kit for all intraoral repairs

Solved with GC!





Dr. Serhat Köken



Scan or click
to read the
full article



Dr. Giancarlo Pongione

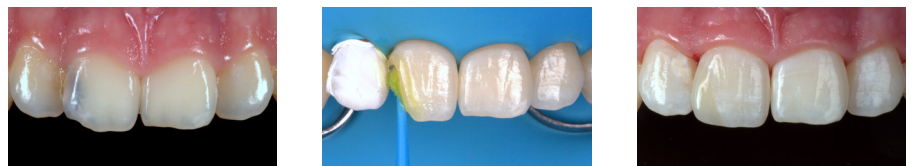

Scan or click
to read the
full article

Changing mindset towards simplified procedures with universal bonding systems

By Dr Serhat Köken, Türkiye

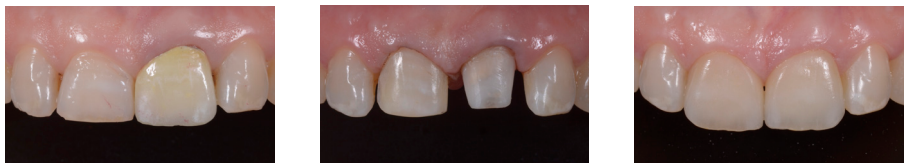G-Premio BOND is a universal bonding agent that can be used in all etching modes and for a wide range of indications. Being the successor of G-BOND, which has shown excellent long-term service in renowned long-term clinical studies, and with the combination of three functional monomers, its excellent performance is undisputed. In this anterior fibre clinical case, some of the other clinical advantages of G-Premio BOND can be clearly noticed.



One-step post-and-core build-up of an endodontically treated tooth

By Dr Giancarlo Pongione, Italy

A 48-year-old patient wanted a more beautiful smile. Tooth #21 had suffered a trauma in the past and had been treated with a PFM crown that did not match the adjacent teeth (Fig. 1). Both central incisors were restored; one with a veneer and the other one with a glass fibre post, core build-up and crown. For the post luting and core build-up, GRADIA CORE (GC) was chosen. It is a dual-cure composite that can be used as luting cement as well as for core build-up, which simplifies the procedure and minimizes treatment error. Because of the thixotropy of the material, it easily retains its shape during the build-up. However, during the fiber glass post insertion, sheer thinning occurs, which makes the material more fluid and easily adapted to the shape of the root canal. The universal adhesive G-Premio BOND, mixed with the dual-cure activator (G-Premio BOND DCA) was used in conjunction with GRADIA CORE. After the build-up, both central incisors were prepared and restored with lithium disilicate restorations.



All the tools you need within hand's reach



GET CONNECTED
SMILE
PROGRAM

Learn. Share. Earn.



Download on the
App Store

GET IT ON
Google Play

Get the app

Notes

GC EUROPE

GC EUROPE N.V.

Head Office
Researchpark
Haasrode-Leuven 1240
Interleuvenlaan 33
B-3001 Leuven
Tel. +32.16.74.10.00
Fax. +32.16.40.48.32
info.gce@gc.dental
www.gc.dental/europe

GC AUSTRIA GmbH

Swiss Office
Zürichstrasse 31
CH-6004 Luzern
Tel. +41.41.520.01.78
Fax. +41.41.520.01.77
info.switzerland@gc.dental

GC AUSTRIA GmbH

Tallak 124
A-8103 Gratwein-Strassengel
Tel. +43.3124.54020
info.austria@gc.dental

GC Europe NV

Benelux Sales Department
Researchpark
Haasrode-Leuven 1240
Interleuvenlaan 33
B-3001 Leuven
Tel. +32.16.74.18.60
info.benelux@gc.dental

GC EUROPE N.V.

East European Office
Siget 19B
HR-10020 Zagreb
Tel. +385.1.46.78.474
Fax. +385.1.46.78.473
info.eeo@gc.dental

GC FRANCE s.a.s.

8 rue Benjamin Franklin
94370 Sucy en Brie Cedex
Tél. +33.1.49.80.37.91
Fax. +33.1.45.76.32.68
info.france@gc.dental

GC Germany GmbH

Seifgrundstraße 2
D-61348 Bad Homburg
Tel. +49.61.72.99.59.60
Fax. +49.61.72.99.59.66.6
info.germany@gc.dental

GC IBÉRICA

Dental Products, S.L.
Edificio Codesa 2
Playa de las Américas 2, 1º, Of. 4
ES-28290 Las Rozas, Madrid
Tel. +34.916.364.340
Fax. +34.916.364.341
comercial.spain@gc.dental

GC ITALIA S.r.l.

Via Calabria 1
I-20098 San Giuliano
Milanese
Tel. +39.02.98.28.20.68
Fax. +39.02.98.28.21.00
info.italy@gc.dental

GC NORDIC AB

Finnish Branch
Lemminkäisenkatu 46
FIN-20520 Turku
Tel. +358.40.900.07.57
info.finland@gc.dental

GC NORDIC AB

Strandvägen 54
S-193 30 Sigtuna
Tel: +46 768 54 43 50
info.nordic@gc.dental

GC Nordic Danish Branch

Scandinavian Trade Building
Gydevang 34-41
DK-3450 Allerød
Tel. +45 51 15 03 82
info.denmark@gc.dental

GC Europe N.V.

Türkiye İrtibat Ofisi
Caferağa Mah.
Albay Faik Sözdener Cad.
İffet Gülhan İş Merkezi No:9 D:4
TR-34710 Kadıköy / İstanbul
Tel. +9002165040601
info.turkey@gc.dental

GC UNITED KINGDOM Ltd.

Coopers Court
Newport Pagnell
UK-Bucks. MK16 8JS
Tel. +44.1908.218.999
Fax. +44.1908.218.900
info.uk@gc.dental

