

Thoracolumbar Spine Surgery: A Guide to Preoperative and Postoperative Patient Care

AANN Clinical Practice Guideline Series



Spine Inc.
a Johnson & Johnson company

never stop moving®

This publication was made possible
through an unrestricted educational
grant from DePuy Spine.



8735 W. Higgins Road, Suite 300
Chicago, IL 60631-2738
888.557.2266 • International phone 847.375.4733
Fax 847.375.6430
info@aann.org | www.AANN.org

AANN Clinical Practice Guideline Series Editor

Patricia A. Blissitt, PhD RN CCRN CNRN ACNS-BC CCM CCNS

AANN Clinical Practice Guideline Series Editorial Board

Sheila Alexander, PhD RN

Patricia Zrelak PhD RN NEA-BC CNRN

Content Authors

Angela Starkweather, PhD RN ACNP-BC CNRN, Chair

Kristy Darnell, MSN RN APN CNRN

Carey Heck, MSN RN ACNP-BC CCRN CNRN

Karen Merchant, MSN RN CNRN

Charlotte S. Myers, MS RN APN-C CNRN

Kristen Smith, MSN RN ANP-BC CNRN

Content Reviewers

Narendra Ballard, MSN APN CCRN ACNP-BC RNFA

Cynthia Bautista, PhD RN CNRN

Kathy S. Bomar, BSN RN ONC CNRN

Katherine Kenny, DNP RN ANP-BC CCRN

Judi Kuric, DNP MSN RN ACNP-BC CNRN

AANN National Office

Joan Kram, MBA RN FACHE

Executive Director

Monica Piotrowski

Associate Editor

Terri Taylor

Graphic Designer

Publisher's Note

The authors, editors, and publisher of this document neither represent nor guarantee that the practices described herein will, if followed, ensure safe and effective patient care. The authors, editors, and publisher further assume no liability or responsibility in connection with any information or recommendations contained in this document. These recommendations reflect the judgment from the American Association of Neuroscience Nurses regarding the state of general knowledge and practice in our field as of the date of publication and are subject to change based on the availability of new scientific information.

Copyright © 2012, revised 2012 and 2014, by the American Association of Neuroscience Nurses. No part of this publication may be reproduced, photocopied, or republished in any form, print or electronic, in whole or in part, without written permission of the American Association of Neuroscience Nurses.

Contents

I. Introduction.....	1
A. Purpose.....	1
B. Statement of the problem.....	1
C. Critical clinical questions these guidelines are intended to answer.....	1
D. Search strategy.....	1
E. Levels of evidence supporting the recommendations.....	1
II. Thoracic and Lumbar Spine Anatomy and Pathophysiology.....	2
A. Thoracolumbar vertebrae.....	2
B. Thoracolumbar intervertebral disks.....	3
C. Thoracolumbar ligaments.....	3
D. Biomechanics of the thoracolumbar spine.....	3
E. Spinal cord segment of the thoracolumbar region.....	4
F. Thoracolumbar nerve roots.....	4
G. Thoracolumbar spinal vasculature.....	4
III. Thoracolumbar Conditions.....	4
A. Nursing responsibilities.....	4
B. Herniated nucleus pulposus of the thoracolumbar spine.....	5
C. Degenerative disk disease (DDD) of the thoracolumbar spine.....	8
D. Stenosis and spondylosis of the thoracolumbar spine.....	10
E. Spondylolisthesis and spondylolysis of the thoracolumbar spine.....	13
F. Scoliosis and kyphosis of the thoracolumbar spine.....	17
G. Fractures of the thoracolumbar spine.....	21
H. Cauda Equina Syndrome (CES).....	23
IV. Review of Diagnostic Studies.....	25
A. Nursing responsibilities.....	25
B. X ray.....	26
C. Computed Tomography (CT) Scan.....	26
D. Magnetic Resonance Imaging (MRI).....	26
E. Bone scan.....	26
F. Diskogram.....	26
G. Myelogram/postmyelogram CT.....	26
H. Electromyography/nerve conduction velocities.....	26
V. Preoperative, Intraoperative, and Postoperative Nursing Care.....	26
A. Preoperative nursing responsibilities.....	26
B. Intraoperative nursing responsibilities.....	29
C. Postoperative nursing responsibilities.....	31
References.....	36
Appendix A.....	41

Preface

In 1997 the American Association of Neuroscience Nurses (AANN) created a series of patient care guidelines, the AANN Reference Series for Clinical Practice, to meet its members' needs for educational tools. To better reflect the nature of the guidelines and the organization's commitment to developing each guideline based on current literature and evidence-based practice, the name of the series was changed in 2007 to the AANN Clinical Practice Guideline Series. Each guide has been developed based on current literature and is built upon best practices. This document represents a revision of a guideline for care of patients undergoing lumbar spine surgery that first was published in 2006 and now has been expanded to include thoracic issues. The purpose is to help registered nurses (RNs), patient care units, and institutions provide safe and effective care to patients who are undergoing thoracolumbar spine surgery.

Surgeries for thoracolumbar disorders in the United States are among the most frequently performed in the world, and direct and indirect costs of spine disorders amount to billions of dollars annually (Chou, Baisden, et al., 2009). Low back pain is the most common cause of disability in persons younger than 45 years of age (Chou, Loeser, et al., 2009; Duffy, 2010). Evidence of spinal pathology with potential or actual neurological compromise, including pain, may indicate the need for surgical interventions (Chou & Huffman, 2009).

Neuroscience nurses are pivotal throughout the perioperative period because they implement best practices when patients experience back pain or thoracolumbar spine pathology refractory to conservative management. Resources and recommendations for practice help nurses make decisions that will optimize patient outcomes.

This reference is an essential resource for nurses responsible for the perioperative care of patients with spine disorders. It is not intended to replace formal education, but rather to augment clinician knowledge and provide a readily available reference tool. Neuroscience nursing and AANN are indebted to the volunteers who devoted their time and expertise to this resource created for those who are committed to the care of neuroscience patients.

I. Introduction

A. Purpose

The purpose of this document is to provide recommendations based on current evidence that will help registered nurses (RNs), other healthcare personnel, and institutions provide safe and effective care to patients before and after thoracic or lumbar spine surgery. Because of the complex nature of spinal pathophysiology, the variety of diagnostic studies used to evaluate spinal disorders, and the spectrum of surgical approaches used for treatment, a description of the most common spinal pathologies is provided here as a resource for practicing clinicians.

The goal of the guidelines that follow is to offer evidence-based recommendations on nursing activities that have the potential to maximize patient outcomes in all cases of spinal surgery. These recommendations are not inclusive of all activities that might improve outcomes, but reflect interventions commonly found in the literature that have been scientifically examined within the past decade. Not all recommendations concern activities independently performed by nurses, but nurses are responsible for implementing and monitoring the outcomes of these activities. The evidence presented here may help neuroscience nurses make appropriate choices when caring for patients before and after thoracolumbar surgery.

B. Statement of the problem

It is estimated that more than 1 million spine surgeries are performed each year in the United States, with fusion procedures accounting for almost one-third of these (Katz, 2006). Although most spinal surgeries are elective, they are not without risk. In addition to the risks associated with anesthesia, postoperative complications include the following (Schuster, Rehtine, Norvell, & Dettori, 2010):

- unintended durotomy/cerebrospinal fluid (CSF) leak (0.3%–13% incidence)
- sensory-motor deficit (1%–8% incidence)
- deep vein thrombosis (DVT; 1%–5% incidence)
- superficial wound infections (0.9%–5% incidence)
- pseudomeningocele (0.7%–2% incidence).

The most commonly performed spine surgeries (microdiscectomy, laminectomy) have lower complication rates than multilevel or fusion procedures and, as the result of advances in technology and surgical techniques, many of these surgeries now are performed in same-day ambulatory centers or require only a short course of hospitalization (Deyo, Nachemson, & Mirza, 2004). Regardless of the surgical setting, neuroscience nurses have a critical role during

the perioperative period of patients with thoracolumbar disorders in assessing and monitoring neurological status, implementing interventions to enhance healing and recovery, and providing patient and family education. Efforts to reduce the occurrence of DVT and rates of infection while optimizing nutritional status, pain management, and physical function may improve outcomes for patients undergoing thoracolumbar surgery and reduce associated healthcare costs. These guidelines address major topics that can be applied in all thoracolumbar spine surgery cases.

C. Critical clinical questions these guidelines are intended to answer

- What are the anatomical and pathophysiological processes leading to spine disorders?
- Which surgical procedures typically are used for each specific thoracolumbar spine disorder?
- What are the nursing responsibilities in the assessment, planning, and coordination of care for patients undergoing thoracolumbar surgery?
- What are the nursing implications of diagnostic studies?
- What nursing interventions related to preoperative planning, intraoperative positioning, pain management, infection control, DVT, wound care, bladder and bowel management, bracing, nutrition, physical functioning, and rehabilitation needs should be used to enhance optimal outcomes and decrease complications?
- What resources for preoperative and postoperative care are available to clinicians, patients, and families?

D. Search strategy

A computerized search of Medline and the Cumulative Index to Nursing and Allied Health Literature was performed using the names of specific nursing interventions with particular spine pathologies and surgery as keywords. The search was restricted to works in English published between 2000 and 2011 in which the sample included patients with thoracic or lumbar spine disorders.

E. Levels of evidence supporting the recommendations

- Class I: Randomized controlled trial (RCT) without significant limitations or meta-analysis
- Class II: RCT with important limitations (e.g., methodological flaws or inconsistent results) or observational studies (e.g., cohort or case-control)
- Class III: Qualitative studies, case study, or series
- Class IV: Evidence from reports of expert committees or expert opinion of the guideline panel, standards of care, and clinical protocols.

The Clinical Practice Guidelines and recommendations for practice are established based upon evaluation of the available evidence (AANN, 2005, adapted from Guyatt & Rennie, 2002; Melnyk, 2004).

- Level 1 recommendations are supported by class I evidence.
- Level 2 recommendations are supported by class II evidence.
- Level 3 recommendations are supported by class III and IV evidence.

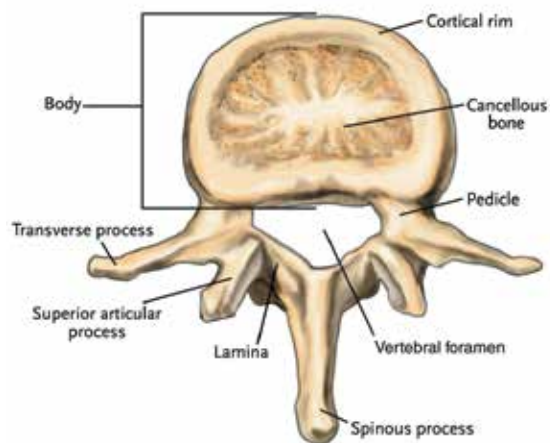
II. Thoracic and Lumbar Spine Anatomy and Pathophysiology

A. Thoracolumbar vertebrae

1. Twelve thoracic vertebrae make up the middle segment of the vertebral column between the cervical and lumbar vertebrae. The thoracic vertebrae increase in size down the length of the spine and are numbered from T1, being closest to the skull, to T12, which abuts the lumbar spine. Each thoracic vertebra has facets on the sides of the body for articulation with the heads of the ribs as well as facets on the transverse processes, except for T11 and T12, for articulation with the tubercles of the ribs. In contrast, the lumbar spine is formed by five vertebrae. The vertebrae commonly are referred to as L1 through L5. L1 is the most superior vertebra in the lumbar spine, and it abuts the thoracic spine, whereas L5 is the most inferior vertebra and abuts the sacral spine. The anterior or ventral element of each vertebra is called the vertebral body. The vertebral bodies of the middle and lower lumbar spine are more substantial in size so they can bear greater loading forces.
2. Posteriorly, or dorsally, each vertebra has a bony arch that encircles the spinal canal. It is composed of two transverse processes, two sets of facet joints, two pedicles, two laminae, and one spinous process (Duffy, 2010). The bony arch, also referred to as the posterior elements, is quite bulky. It provides the necessary support for upright posture (**Figure 1**). The noncompromised spinal canal has ample room for the cauda equina and for CSF.
3. Facet joints (bilaterally) are composed of a superior articulating process and an inferior articulating process (Hicks, Morone, & Weiner, 2009). The superior articulating process forms a joint with the inferior articulating process of the vertebra above (e.g., the superior articulating processes of L3 form two facet joints with the inferior articulating processes of L2). Facet

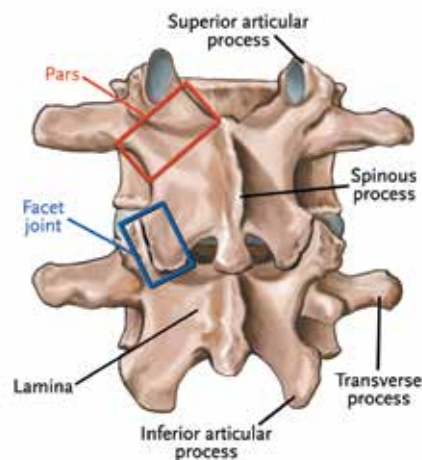
joints have a loose capsule and a synovial lining; consequently, they are apophyseal joints (**Figure 2**).

Figure 1. Lumbar vertebra



From Schnuerer, A., Gallego, J., & Manuel, C. (2003). Core Curriculum for Basic Spinal Training (2nd ed.). Memphis, TN: Medtronic Sofamor Danek. Image provided by Medtronic.

Figure 2. Lumbar spine: Posterior view

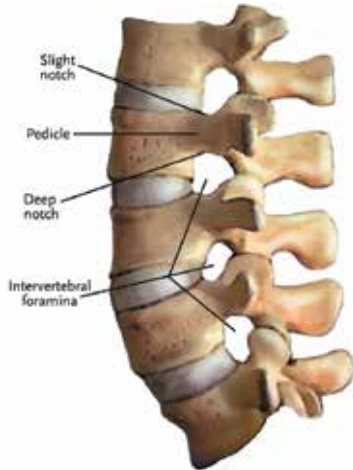

From Schnuerer, A., Gallego, J., & Manuel, C. (2003). Core Curriculum for Basic Spinal Training (2nd ed.). Memphis, TN: Medtronic Sofamor Danek. Image provided by Medtronic.

4. The nerve root canal, also called the lateral recess, is adjacent to the pedicles and facet joints in the region of the foramina. It encompasses the nerve root as it exits the spinal cord (**Figure 3**). The neural foramina, also referred to as the intervertebral foramina, is the actual far lateral exit opening of the nerve root canal (Choi, 2009). The thoracolumbar vertebral, or spinal, canal is supported anteriorly by the posterior edge of the vertebral body and the posterior longitudinal

ligament. This ligament lies on the posterior vertebral body surface. The lateral elements of the vertebral canal are the pedicles and the facet joints, with corresponding articular capsules. Posteriorly, the vertebral canal is formed by the laminae and ligamenta flava.

Figure 3. Lumbar spine: Lateral view



From Schnuerer, A., Gallego, J., & Manuel, C. (2003). Core Curriculum for Basic Spinal Training (2nd ed.). Memphis, TN: Medtronic Sofamor Danek. Image provided by Medtronic.

B. Thoracolumbar intervertebral disks

1. Each intervertebral disk in the thoracolumbar spine provides support and facilitates movement while resisting excessive movement. The disk permits slight anterior flexion, posterior extension, lateral flexion, rotation, and some circumduction (Shankar, Scarlett, & Abram, 2009).
2. The disk is the largest avascular structure in the body (Singh, Masuda, Thonar, An, & Cs-Szabo, 2009). It is composed of the nucleus pulposus and the annulus fibrosus. In people who are younger than 35 years of age the nucleus pulposus is soft and similar to crab meat in texture. With aging, the nucleus pulposus dehydrates.
3. Surrounding the nucleus pulposus is the annulus fibrosus (**Figure 4**), which is tough and fibrous. The fibers of the annulus fibrosus are concentric, like the layers of a radial tire. The concentric arrangement provides resistance and strength.
4. Each disk is bonded to the vertebral body below and above it by a thin cartilaginous plate, referred to as the endplate (**Figure 5**). The endplate resists herniation of the disk into the vertebral body and gives the disk its shape (Hicks et al., 2009).

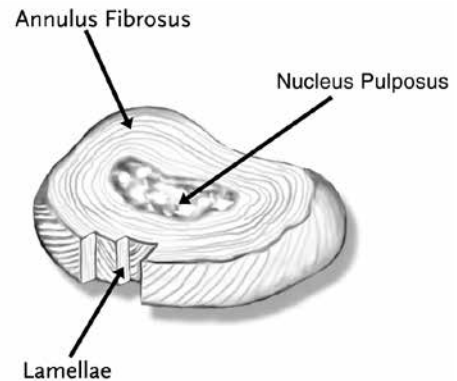
C. Thoracolumbar ligaments

1. Each disk is reinforced anteriorly by the anterior longitudinal ligament and posteriorly by

the posterior longitudinal ligament. The laminae are connected by an elastic yellow ligament called the ligamentum flavum.

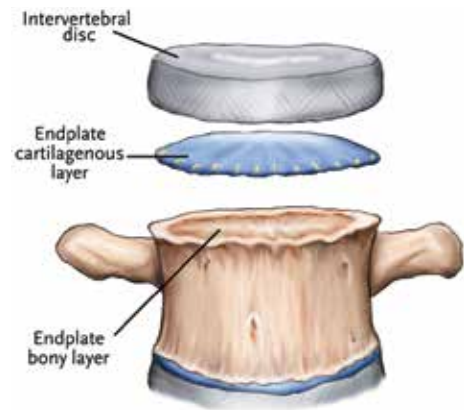
2. Each facet joint is connected to a capsular ligament. The transverse processes are connected by intertransverse ligaments. The rotator brevis and rotator longus ligaments connect the transverse processes to the laminae of the superior two vertebrae.
3. The spinous processes are connected by supraspinous and interspinous ligaments (**Figure 6**).

Figure 4. Intervertebral disk



From Schnuerer, A., Gallego, J., & Manuel, C. (2003). Core Curriculum for Basic Spinal Training (2nd ed.). Memphis, TN: Medtronic Sofamor Danek. Image provided by Medtronic.

Figure 5. Intervertebral disk in relation to endplate and vertebral body



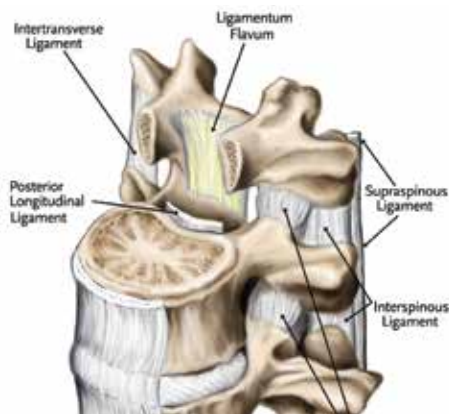
From Schnuerer, A., Gallego, J., & Manuel, C. (2003). Core Curriculum for Basic Spinal Training (2nd ed.). Memphis, TN: Medtronic Sofamor Danek. Image provided by Medtronic.

D. Biomechanics of the thoracolumbar spine

1. The functional unit of the spinal column is the motion segment. A motion segment is composed of two adjacent vertebrae, the disk between them, the facet joints connecting them, and the ligaments attached to the vertebrae (McGill & Karpowicz, 2009).

- The geometry and health of the functional units help a surgeon determine which patients will benefit from surgery and the most appropriate surgical intervention for a given patient.

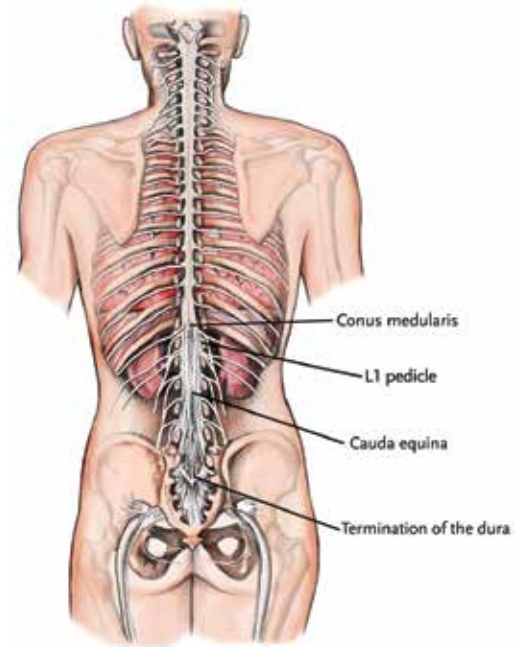
Figure 6. Ligaments of the lumbar spine



From Schnuerer, A., Gallego, J., & Manuel, C. (2003). Core Curriculum for Basic Spinal Training (2nd ed.). Memphis, TN: Medtronic Sofamor Danek. Image provided by Medtronic.

- Spinal cord segment of the thoracolumbar region
 - The spinal cord ends at approximately the L1–L2 level in an adult.
 - The conus medullaris is the end of the spinal cord.
 - The filum terminale is an extension of the pia mater, which descends below the conus medullaris and is anchored to the coccyx.
- Thoracolumbar nerve roots
 - The cauda equina is a fanning bundle of lumbar and sacral nerve roots exiting off the spinal cord at the conus medullaris. This mass of nerve roots provides communication with the lower extremities and controls bowel, bladder, and sexual function (**Figure 7**).
 - The cauda equina is relatively resistant to neurologic insults compared to the spinal cord (Shankar et al., 2009).
 - The exiting nerve root in the thoracic and lumbar spine is numbered according to the pedicle above it. For example, the L5 nerve root passes below the L5 pedicle.
- Thoracolumbar spinal vasculature
 - The abdominal aorta follows the left side of the spine until L4, where it bifurcates into the left and right common iliac arteries. The femoral arteries arise from the common iliac arteries.
 - The middle sacral, iliolumbar, and internal iliac arteries supply blood to L5 and the sacrum.
 - Segmental arteries branch off the aorta and supply the vertebral body, posterior elements, and paraspinal muscles of the lumbar spine.

Figure 7. Termination of spinal cord at conus medullaris; cauda equina; and termination of dura in coccyx



From Schnuerer, A., Gallego, J., & Manuel, C. (2003). Core Curriculum for Basic Spinal Training (2nd ed.). Memphis, TN: Medtronic Sofamor Danek. Image provided by Medtronic.

- Near the posterior wall of the vertebrae, each segmental artery bifurcates into a posterior branch and spinal branch. The spinal branch enters the vertebral canal through the intervertebral foramen and supplies portions of the posterior vertebral body. It joins other spinal branches at other levels to form the anterior spinal artery.
- The anterior spinal artery supplies the anterior two-thirds of the spinal cord.
- Segmental veins drain into the inferior vena cava (IVC), which originates at the convergence of the left and right common iliac veins at the L4 level (Becske & Nelson, 2009). The IVC terminates in the right atrium of the heart.

III. Thoracolumbar Conditions

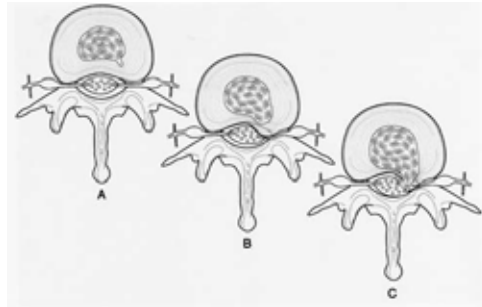
A. Nursing responsibilities

- Obtain a complete history and review of symptoms and perform a neurological exam on patients presenting with signs and symptoms associated with thoracolumbar conditions. Establish a baseline symptom assessment and neurological exam to help monitor treatment efficacy.
- Symptom assessment includes a patient's report of physical, cognitive, emotional, or behavioral symptoms. This should include an evaluation of

psychological comorbidities including depression and a thorough assessment of pain, current level of activity, and physical functioning.

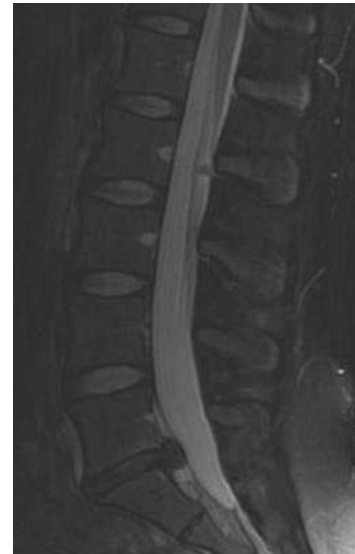3. Psychosocial factors can affect surgical outcomes. Optimizing social support and mental health is imperative (Laxton & Perrin, 2003). Screening tools to identify psychosocial risk factors of chronic low back pain and disability are available (Chou, Atlas, Stanos, & Rosenquist, 2009). Screening tools can be used to help determine the need for psychosocial interventions such as cognitive behavioral therapy.
 4. Nurses should assess patient care needs and support systems and identify potential resources for patients and families. Resources should include self-management strategies to address symptoms.
 5. Nurses should provide preoperative and postoperative teaching that describes procedure goals, the expected course of recovery and outcomes, and potential complications.
 6. Nurses should help coordinate care, which may entail referrals to other healthcare providers, transportation to and from therapies, and management of pharmacological and nonpharmacological interventions.
- B. Herniated nucleus pulposus of the thoracolumbar spine
1. Description and etiology
 - a. Intervertebral disk herniation also is known as herniated nucleus pulposus (HNP). HNP may be asymptomatic despite radiographic evidence of bulging, protrusion, or an extruded disk (**Figures 8 and 9**).
 - b. The etiology may be either spontaneous or attributable to a precipitating event. Even when a patient is symptomatic, surgical intervention often is not required.
 - c. An HNP may be symptomatic as the result of a combination of direct nerve root compression, the release of inflammatory chemicals (e.g., matrix metalloproteinases, prostaglandin E2, Interleukin-6, nitric oxide), and hypoxia of the nerve root and basal ganglion (Ireland, 2009).
 - d. Radicular pain can be accompanied by paresthesias or paresis (i.e., weakness) in the anatomic distribution of the affected nerve root (**Figure 10**). HNP-associated back or leg pain may be aggravated by coughing, sneezing, or assuming certain positions.
 3. Segmental arteries branch off the aorta and supply the vertebral body, posterior elements, and paraspinal muscles of the lumbar spine.

Figure 8. Progression of disk herniation



A. Normal disk; B. Bulging disk, pressure placed on exiting nerve root; C. Disc extrusion, disc material outside annulus. From AANN Core Curriculum for Neuroscience Nursing (4th ed.), edited by M.K. Bader & L. Littlejohns. 2004. St. Louis: Saunders. Used with Permission.

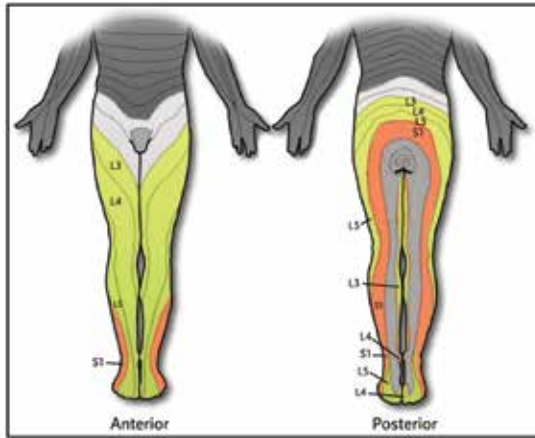
Figure 9. Lumbar spine, MRI, sagittal view; herniated disk at L5-S1



© 2011 by Andrea Strayer. Reproduced with permission.

- ii. Protrusion: Focal area of bulge or disk extension that still is attached to the disk (annulus fibrosis)
 - iii. Extruded fragment: Nucleus pulposus no longer connected to the disk
 - iv. Sequestered fragment (i.e., free fragment): Nucleus pulposus in the posterior longitudinal ligament.
- f. Nonsurgical treatment is important in the care of patients with an HNP. Many episodes of acute back pain due to HNP are self-limiting and do not require intervention (Duffy, 2010). Chou, Atlas, and colleagues. (2009) noted that 90% of acute attacks resolve with conservative management alone.

Figure 10. Dermatomal distribution of lumbar nerve roots



From Schnuerer, A., Gallego, J., & Manuel, C. (2003). Core Curriculum for Basic Spinal Training (2nd ed.). Memphis, TN: Medtronic Sofamor Danek. Image provided by Medtronic.

Table 1. Nerve roots and corresponding sensory, motor, and reflex functions

Nerve Root	Sensory	Motor	Reflex
L2	Groin area	Hip flexor (iliopsoas)	None
L3	Groin, anterior thigh	Knee extension (quadriceps)	None
L4	Anterior thigh, knee, medial calf	Knee extension (quadriceps)	Patella (knee jerk)
L5	Lateral thigh, lateral calf, top of foot	EHL (extensor hallucis longus)— raise great toe Foot dorsiflexion (anterior tibialis) Knee flexion (hamstrings)	none
S1	Posterior thigh, posterior calf, lateral aspect of foot	Foot plantarflexion (gastrocnemius)	Achilles (ankle jerk)

2. Incidence and epidemiology
 - a. Symptomatic HNP is more common in younger patients, with peak incidence among those ages 35–55 (Weinstein, Lurie, et al., 2008).
 - b. Most HNPs occur at the L4–L5 or L5–S1 levels.
 - c. The majority of lumbar HNPs occur in a posterolateral direction, compressing the ipsilateral nerve root as it exits the dural sac.
 - d. HNPs in the thoracic region are much less common due to stabilization by the rib cage, which reduces mechanical stress to the intervertebral disks (Matsumoto et al., 2010). It is estimated that fewer than 1% of the total reported disk herniations occur in the thoracic spine, with men being affected more frequently than women. This gender difference has been reported to be as high as 2:1 in respect to patients with low back pain attributable to HNP.
3. Diagnostic and physical exam findings
 - a. Magnetic resonance imaging (MRI) studies are the best diagnostic tool to evaluate the spinal structures, HNP, and nerve root compression. A computed tomography (CT) scan may be required to further evaluate bony structures in some patients.
 - b. Motor weakness, sensory changes, or alteration in deep tendon reflexes are noted. (Refer to **Table 1** for more information.)
 - c. Neurological dysfunction and symptoms should correlate with the location of the HNP on diagnostic tests.

- d. Lumbar nerve root tension may be tested with a straight-leg raise test or other provocative maneuvers.
- e. Gait, forward flexion, and general mobility should be noted.

Recommendation: Nurses should be alert for “red flags” in the patient history and neurological examination, including a history of cancer, recent trauma or infection, progressive neurological deficits such as weakness or sensory changes, or alterations in bowel and bladder functioning. Abnormal findings should be reported to the healthcare provider (**Level 3**).

4. Surgical treatment options
 - a. Surgical treatment may be indicated when conservative management fails to alleviate a patient’s symptomatology. Before surgical intervention is considered for patients with isolated HNP-induced low back pain, a trial of maximal nonoperative therapies for at least 6 weeks is recommended (Jegade, Ndu, & Grauer, 2010). This time frame is extended for up to 6 months in patients with thoracic HNP. Exceptions are indicated if a patient with a lumbar HNP develops cauda equina syndrome (CES), if a patient with a thoracic HNP develops signs of myelopathy due to cord compression from the herniated disk, or if progressive neurologic deficits are present in any patient (Matsumoto et al., 2010).
 - b. The best surgical results are obtained when back pain is associated with a radiculopathy in a distribution consistent with radiographic findings (Moschetti, Pearson, & Abdu, 2009). The literature regarding the benefits

of surgery for low back pain is conflicting. Several studies have attempted to evaluate the efficacy of surgery versus conservative management in the treatment of acute back pain. The findings of these studies revealed a trend toward reported improvement in short-term outcomes with surgical intervention, but longer-term outcomes were similar when comparing conservative and surgical interventions (Jegade et al., 2010). Weinstein et al. (2008a) found that patients treated surgically for intervertebral disk herniation showed significantly greater improvement in pain, function, satisfaction, and self-rated progress over 4 years compared to patients treated nonoperatively. A literature review by Chou, Baisden, and colleagues (2009) found that discectomy and microdiscectomy for low back pain were moderately superior to nonsurgical therapy for improvement in pain and function in the short term, but long-term benefits (longer than 3 months) were inconsistent.

c. Surgery for patients with a thoracic HNP is less nebulous because the strongest indication for surgery is the presence of myelopathy (Matsumoto et al., 2010).

d. Surgical options for thoracic HNP

i. Surgical planning may include decompression and fusion depending on the patient's anatomy and degree of instability. Preoperative patient education should include chest tube management because these procedures often necessitate the placement of a chest tube intraoperatively.

ii. Posterior or posterolateral approach

- a) Useful for disks located within the lateral half of the spinal canal or in the neural foramen
- b) Best for soft HNPs; not as useful if the disk is large or calcified
- c) The limitation of the posterior approach is the surgeon's inability to visualize the ventral surface of the dura.

iii. Anterior approach

- a) Allows a more complete visualization of and access to the ventral surface of the spine and spinal cord
- b) Options include thoracotomy or less invasive thoracoscopy; benefits of thoracoscopy over thoracotomy include a shorter hospitalization and

recovery period and less postoperative pain

e. Surgical options for lumbar HNP

i. Microdiscectomy

- a) Microdiscectomy is performed under general or regional anesthesia.
- b) The patient is in a prone position.
- c) Following deep dissection, the correct disk space is confirmed radiographically. Once confirmed, the ligamentum flavum and lamina are dissected to expose the nerve root. The opening in one lamina is termed a *semihemilaminectomy*.
- d) After the nerve root is identified, all ligaments obstructing the view of the disk and nerve roots are cleaned away. A retractor is used to gently bring the nerve root structures medially.
- e) The disk often is excised and the disk fragments, which will vary in size, are carefully removed.
- f) The area is then irrigated, hemostasis is achieved, and the wound is closed.

ii. Open discectomy

Open discectomy is the same procedure as microdiscectomy, except the surgeon does not use an operative microscope. Consequently, a larger incision is required.

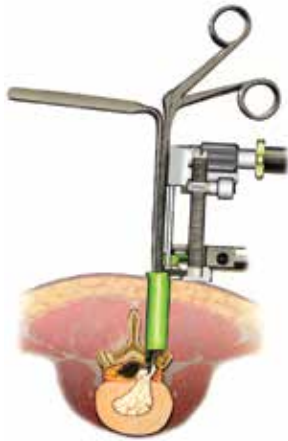iii. Minimal-access or minimally invasive discectomy

This technique permits a discectomy to be performed through a very small incision and with minimal disruption of adjacent tissues (**Figure 11**). It often is performed on an outpatient basis or with a 23-hour observation stay. This technique is increasing in popularity in all settings, especially in freestanding surgery centers.

- a) The surgeon uses a tubular retractor system and loupe magnification or an operating microscope.
- b) The tubular retractor is placed through a small incision and deep dissection.
- c) The discectomy is performed, as described above, through the tubular retractor.

5. Preoperative, intraoperative, and postoperative management of HNP of the thoracolumbar spine

Figure 11. Minimal-access microdiscectomy



From Schnuerer, A., Gallego, J., & Manuel, C. (2003). Core Curriculum for Basic Spinal Training (2nd ed.). Memphis, TN: Medtronic Sofamor Danek. Image provided by Medtronic.

5. Preoperative, intraoperative, and postoperative management of HNP of the thoracolumbar spine
 - a. The general recommendations for the preoperative, intraoperative, and postoperative management found in Sections V–VII of this guideline should be followed.
 - b. Patients should receive information regarding the possibility of postoperative residual sensory disturbances. Although low back pain and sciatica may significantly decrease after surgery, patients may experience sensory disturbances in the affected dermatomes as the nerve heals during the postsurgical months.
 - c. General wound care instructions should be provided upon discharge. Typically, Steri-Strips are used after microdiscectomy and staples are used after open discectomy.
 - d. Analgesics should be provided to manage surgical wound pain and enhance postoperative physical functioning.

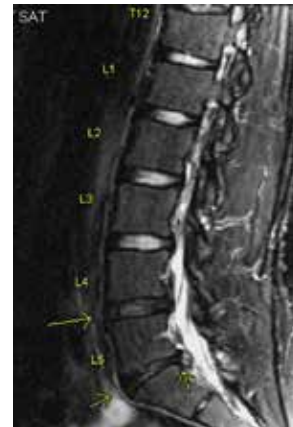Recommendation: Nurses should provide a clearly defined plan for increasing activity and weaning pain medications during the first few weeks following surgery based on the patient's status. Generally, the goal is to resume normal activities and be titrated off of opioid medications by weeks 2–4 postoperatively (**Level 3**).

- C. Degenerative disk disease (DDD) of the thoracolumbar spine
 1. Description and etiology
 - a. DDD is one of the most common causes of low back pain, especially in the younger population. It is estimated that up to 93% of people between 60 and 80 years of age have some

radiographic degenerative disk changes; however, most do not experience any pain (Schizas, Kulik, & Kosmopoulos, 2010)

- b. The lumbar region is the most prone to degenerative changes as a result of increased mechanical stresses in this area.
 - c. Current evidence indicates that disk degeneration is a result of a combination of mechanical, biochemical, and genetic factors. With aging, the moisture content of the inner nucleus pulposus decreases due to proteoglycan changes and the resulting desiccated disk provides less support. The annulus fibrosis, with its higher collagen content, must absorb more of the mechanical stresses as the inner nucleus pulposus loses strength, leading to higher incidences of annular tears. As tears develop, the inner nucleus material may begin to seep out. If the nerves surrounding the outer region of the annulus fibrosis are exposed to noxious stimuli such as pressure from the nucleus pulposus, extreme pain may result (Ferguson & Steffen, 2003).
2. Incidence and epidemiology
 - a. Patients often are relatively young; they present with a history of gradually worsening back pain. Disk degeneration is a natural process; up to 34% of the population between 20 and 40 years of age has MRI evidence of DDD, and up to 95% of those 65 years of age and older show signs of disk degeneration (Hicks et al., 2009).
 - b. Many patients with DDD are asymptomatic despite radiographic degenerative changes (**Figure 12**).

Figure 12. L4–L5 and L5–S1 degenerative disk disease: Lumbar spine MRI, T2-weighted image



© 2011 by Andrea Strayer. Reproduced with permission.

- c. Those with symptoms commonly report increased pain with sitting, sciatica (often bilateral) and disability (Chou, Baisden, et al., 2009).
 - d. DDD is most common in the lumbar spine because of increased compressive loads in this region. Evidence exists for a genetic disposition to DDD (Paassilta et al., 2001). Changes in specific proteoglycans in the nucleus pulposa that are associated with aging also have been studied (Gruber et al., 2009). These changes contribute to decreased water content and, along with structural changes, reduce the load-bearing capacity of the intervertebral disk and affect the efficiency of nutrient transport throughout the disk.
3. Diagnostic and physical exam findings
- a. Pain is described as deep, midline, and aching. Pain may radiate into the buttocks or upper thighs; it may be unilateral or bilateral. It usually is worse when patients stand in one position or sit for long periods of time.
 - b. Various scales have been developed to attempt to correlate the degree of disk degeneration with radiographic findings. Thompson and colleagues (1990) developed a screening scale ranging from I–V to evaluate gross changes in disk morphology, and Pfirmann, Metzdorf, Zanetti, Hodler, and Boos (2001) developed a I–V scale based on T2-weighted MRIs.
 - c. Surgical treatment options

Correlation of physical exam findings with diagnostic imaging is necessary to determine the potential benefit of surgical interventions, which may include disk arthroplasty, intradiskal electrothermal annuloplasty (IDET), laminectomy, or fusion procedures (described below).

 - i. Disk arthroplasty (artificial disk replacement)
 - a) To date, the only U.S. Food and Drug Administration-approved lumbar artificial disk replacements are the Charité™ and the ProDisk™. Other devices are being investigated.
 - b) Proponents of artificial disk replacement cite its stabilization and preservation of the motion segment, citing decreased adjacent level disease and a reduction in other complications of lumbar fusion (i.e., hardware failure, graft problems, graft site pain, symptomatic pseudoarthrosis, loss of motion across fused segments, loss of normal sagittal balance; Berg, Tullberg, Branth, Olerud, & Tropp, 2009).
 - c) Correct patient selection and accurate and correct disk placement are important for optimal surgical results.
 - d) Clinical indications for the Charité include single-level DDD at L4–L5 or L5–S1 confirmed by provocative diskography, back or leg pain without nerve root compression, and failure of nonsurgical treatment (Guyer et al., 2009).
 - e) Clinical indications for the ProDisk are disabling low back pain caused by one or two adjacent levels between L3–S1. The pain must primarily originate from the disk and be refractory to aggressive nonoperative treatment for at least 6 months (Berg et al., 2009).
 - f) Both devices are placed through an anterior approach.
 - ii. IDET
 - a) The clinical indications for IDET include back pain caused by DDD that is refractory to at least 6 months of conservative treatment.
 - b) A specialized catheter is threaded through an introducer to the affected area. The catheter is heated to 90°C for 17 minutes. The purpose is to cauterize the annular tear and pain fibers, thereby decreasing or alleviating low back pain.
 - c) This minimally invasive procedure is done in an interventional radiology suite or operating room under fluoroscopy. It is performed as an outpatient procedure using conscious sedation.
 - iii. Laminectomy
 - a) A laminectomy may be used to treat DDD by removing a portion or entire segment of the lamina (Papavero et al., 2009). The number of levels decompressed is dependent on the number of levels that may be causing a patient's symptoms.
 - b) After deep-tissue dissection, localization is confirmed with X ray.
 - c) Bony removal begins with the spinous process. The amount of bone

removed depends on the amount of stenosis.

- d) The lamina is thinned with a drill. The thinned lamina is then removed; the spinal canal is carefully decompressed.
 - e) The ligamentum flavum lies between the lamina and the thecal sac. The ligamentum flavum often is thickened in cases of spinal stenosis. The dura often is physically protected while the ligamentous and bony dissection is completed.
 - f) The lateral recesses are then checked and ligamentous or bony material is removed, with particular attention paid to the medial aspect of the foramen. This approach ensures good nerve root decompression.
 - g) The wound is irrigated and closed. A drain may be used.
- iv. Fusion procedures
- a) A lumbar fusion procedure may be used for DDD that is refractory to 6–12 months of conservative treatment.
 - b) The type of lumbar fusion procedure will depend on the levels involved and existing spinal instability. The various types of fusion techniques are described in Section III.E.4.d.
4. Preoperative, intraoperative, and postoperative management of DDD of the thoracolumbar spine
- a. The general recommendations for preoperative, intraoperative, and postoperative management in Sections V–VII should be followed.
 - b. Patients should receive information regarding the possibility of having residual pain and sensory disturbances during the postoperative period. Consider formal physical rehabilitation programs or pain management services for patients with preoperative chronic pain.
 - c. General wound care instructions should be provided upon discharge. Typically, Steri-Strips or staples are used to close wounds.
 - d. Analgesics should be provided to manage surgical wound pain and enhance postoperative physical functioning.

Recommendation: Nurses should provide a clearly defined plan for increasing activity and weaning pain medications during the first few weeks

following surgery based on the patient's status. Generally, the goal is to resume normal activities and begin titrating off of opioid medications by weeks 2–4 postoperatively (**Level 3**).

- D. Stenosis and spondylosis of the thoracolumbar spine
1. Description and etiology
 - a. Thoracolumbar stenosis
 - i. Central canal stenosis
The normally triangular-shaped spinal canal becomes flattened, compressing the thecal sac. As it progresses, the cauda equina or spinal cord is compressed. Central spinal stenosis of the thoracic region may cause myelopathy, which in turn may result in lower-extremity weakness and gait disturbance. This condition can be caused by any one or a combination of the following:
 - facet hypertrophy
 - thickening and bulging of the ligamenta flava
 - outward disk bulging
 - disk degeneration
 - spondylosis (**Figures 13 and 14**)
 - degenerative spondylolisthesis.Central canal stenosis is aggravated by positions of extension or flexion, which produce more central canal and lateral-recess narrowing.
 - ii. Lateral-recess stenosis
Lateral-recess stenosis may occur at any region of the spine. It is a narrowing in the area in which the nerve roots exit the spinal canal, which leads to nerve root compression. Complaints of radicular pain, weakness, or numbness along the distribution of the affected spinal nerve may be observed. Causes include facet hypertrophy, disk bulging, loss of disk height, spondylosis, or degenerative spondylolisthesis.
 - iii. Neurogenic claudication
Compression of the microvasculature of the lumbar nerve roots, which results in ischemia and pain, is believed to be a major contributing factor to neurogenic claudication. In addition to ischemia, postural changes can cause stenosis. Postural neurogenic claudication is induced when the lumbar spine is extended and lordosis is accentuated, whether at rest or during exercise in the erect posture. With extension of

the spine, degenerated intervertebral disks and thickened ligamenta flava protrude posteriorly into the lumbar canal, producing transient compression of the cauda equina. In the ischemic form, it is theorized that transient ischemia occurs in compressed lumbosacral roots when increased oxygen demand occurs during walking (Siebert et al., 2009).

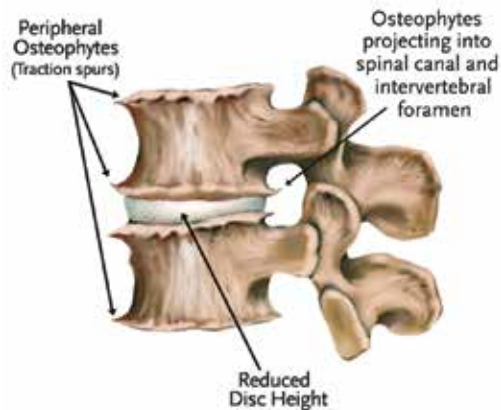
b. Spondylosis

- i. Spondylosis is the result of disk degeneration, which leads to bulging of the annulus fibrosus. The degenerated, bulging annulus fibrosus creates an elevation of the periosteum. Bony reactions occur, resulting in osteophyte formation (Figure 13). The osteophytes most commonly occur in the lordotic spinal canal of the lumbar and cervical spine (Middleton & Fish, 2009). In addition, there may be hypertrophy or thickening and buckling of the ligamentum flavum, leading to further narrowing of the central spinal canal. With disk collapse, the neural foramina will decrease in height, resulting in neuroforaminal stenosis, which may result in nerve root compression.
- ii. Alterations in axial loads may lead to posterior facet osteophyte formation, which also can result in nerve root compression (Singh & Phillips, 2005).
- iii. Spondylosis often results in axial spine pain (Middleton & Fish, 2009). Motion segment degeneration can lead to stiffened levels, exhibiting disk degeneration, ligament calcification, and osteophyte formation. Conversely, the motion segment can be hypermobile, as in degenerative spondylolisthesis (Watters et al., 2009).
- iv. The degenerative cascade, a part of the aging process, is caused by many factors and affects the disks, facet joints, surrounding soft tissue, ligaments, vertebrae, and articular processes. Middleton and Fish (2009) noted that the spondylotic process may be lessened by surgical fusion or immobilization with orthosis.

2. Incidence and epidemiology

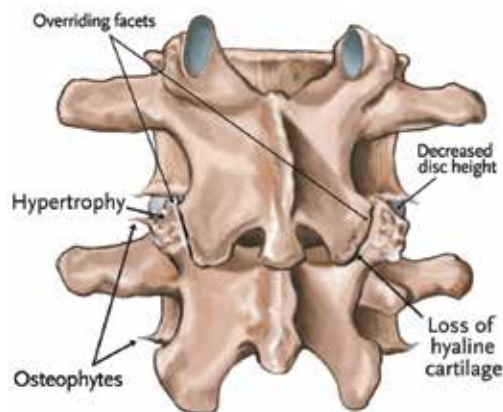
- a. A person with severe congenital lumbar stenosis may become symptomatic as early as age 20; someone with acquired lumbar spinal stenosis becomes symptomatic between ages 60 and 70 (Aliabadi & Isaacs, 2009).
- b. Back pain as a result of degenerative changes is seen more frequently in older adults; in one study, 47.2% of a sample 60–69-year-old age group showed radiographic signs of lumbar spinal stenosis (Kalichman et al., 2009). Hicks and colleagues (2009) found that more than 90% of older adults in their study had

Figure 13. Spondylosis in the lumbar spine



From Schnuerer, A., Gallego, J., & Manuel, C. (2003). Core Curriculum for Basic Spinal Training (2nd ed.). Memphis, TN: Medtronic Sofamor Danek. Image provided by Medtronic.

Figure 14. Spondylosis: Posterior view



From Schnuerer, A., Gallego, J., & Manuel, C. (2003). Core Curriculum for Basic Spinal Training (2nd ed.). Memphis, TN: Medtronic Sofamor Danek. Image provided by Medtronic.

iv. Types of stenosis

- a) Congenital stenosis: A patient is born with a small narrow spinal canal.
- b) Acquired stenosis: The spinal canal has narrowed because of degenerative changes.

- radiographic evidence of degenerative spine disease.
- c. Although L4–L5 is the most frequently involved level, lumbar stenosis may be found over one or two segments or at multiple levels. As is the case with herniated disks, stenosis in the thoracic spine is rare due to the comparative immobility of the thoracic cage (Matsumoto et al., 2010).
 - d. Men have a higher incidence of spinal stenosis than women. There does not appear to be a correlation between race and spinal stenosis, although ossification of the posterior longitudinal ligament leading to development of spinal stenosis is seen more frequently in those of Asian ethnicity (Yang, Bi, Fu, & Zhang, 2010).
3. Diagnostic and physical exam findings
 - a. Symptoms of thoracic stenosis
 - i. Radicular pain is managed with conservative therapies as described below.
 - ii. Physical symptoms associated with stenosis of the thoracic spine most often are seen in patients with myelopathy and may include spastic gait, lower-extremity motor and sensory loss, and bladder changes (Yang et al., 2010).
 - iii. If myelopathic signs are present, a patient may be hyper-reflexic with positive Babinski sign, clonus, and decreased motor strength in the lower extremities.
 - b. Symptoms of lumbar stenosis
 - i. Lower extremity symptoms may be described as burning, cramping, aching, numbness, tingling, or dull fatigue.
 - ii. Early stenosis may present with non-specific back pain.
 - iii. Leg fatigue, pain, numbness, and weakness occur, possibly several months to years after back pain first is noticed.
 - iv. Symptoms usually are exacerbated by walking; symptoms are immediately relieved by sitting down.
 - v. Walking distance usually gradually declines over time, reflecting symptom onset at shorter and shorter distances.
 - vi. Symptoms generally are bilateral but can be more pronounced on one side.
 - vii. Pain radiates from the buttocks to the posterior or posterolateral thighs and occasionally spreads distally to the calves and feet.
 - viii. Symptoms often improve with a forward flexed posture. Patients may describe increased walking tolerance if using a supportive device such as a grocery cart, walker, or cane.
 - ix. The degree of pain does not always correlate with the severity of stenosis.
 - x. Posture often is stooped forward (i.e., forward flexion). This sort of posture, referred to as the simian stance, is more pronounced with ambulation.
 - xi. Patient strength generally is intact, but deep tendon reflexes may be decreased or absent.
 - xii. Sensation usually is normal but may temporarily be affected after ambulation. If comorbidities such as diabetes are present, the patient may have decreased sensation in a stocking distribution.
 4. Surgical treatment options
 - a. The goals of treatment for patients with spinal stenosis are pain alleviation and mobility preservation or improvement. Conservative management is recommended before considering surgical intervention unless clearly defined neurologic emergencies are present (Papavero et al., 2009).
 - b. The literature regarding surgery for low back pain resulting from stenosis, like that for HNP, is conflicting. Pearson and colleagues (2011) found that patients with low back pain improved significantly more with surgery compared to patients treated with nonoperative strategies. Further investigation by the authors revealed that patients with predominant leg pain improved significantly more with surgery than patients with predominant low back pain. Weinstein, Tosteson and colleagues (2008) reported that patients with spinal stenosis without degenerative spondylolisthesis who underwent surgery showed significantly better improvement in pain, function, satisfaction, and self-rated progress than did patients treated nonsurgically. Atlas, Keller, Wu, Deyo, and Singer (2005) found that patients with lumbar spinal stenosis treated surgically and nonsurgically had similar low back pain relief, predominant symptom improvement, and satisfaction at 8–10 years. However, the surgical treatment group experienced greater improvement in leg pain relief and back-related functional status. The benefits

associated with surgery must be weighed against potential complications, particularly because many of these patients are elderly and may have comorbidities that place them at increased risk for surgery. Chou, Baisden, and colleagues (2009) noted that “decisions regarding surgery for this condition should take into account several factors, including the availability of intensive rehabilitation..., the small to moderate benefit associated with surgery compared to standard (non-intensive) nonsurgical therapy...and the fact that most patients do not experience an optimal outcome following fusion” (p. 1105).

- c. Laminectomy and partial facetectomy (typically medial one-third) is the standard surgery for lumbar stenosis (Papavero et al., 2009). The number of levels decompressed (**Figure 15**) is dependant on the number of levels suspected to cause the patient’s symptoms. Care is taken to avoid dural tear, nerve root injury, or complete facetectomy, which can lead to segmental instability or acquired spondylolisthesis.
5. Preoperative, intraoperative, and postoperative management of stenosis and spondylosis of the thoracolumbar spine
 - a. The general recommendations for preoperative, intraoperative, and postoperative management found in Sections V–VII should be followed.

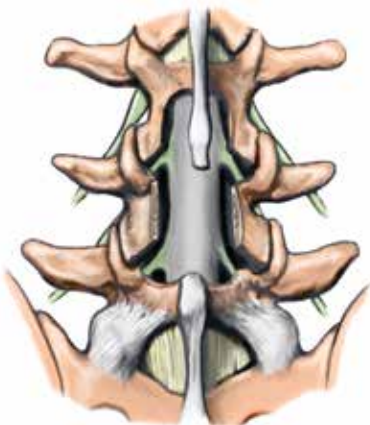
the surgery to address recommendations or the need for additional testing.

- c. Patients should receive information regarding the possibility of having residual pain, weakness, or sensory disturbances during the postoperative period. Consider rehabilitation or pain-management services for those with preoperative chronic pain. Formal rehabilitation programs may be more effective than standard care for postoperative improvement in functional status (McGregor et al., 2013).

Recommendation: Nurses should assess for potential rehabilitation needs based on the patient’s preoperative status. If the patient is deconditioned, consider coordinating preoperative referral to a physical medicine and rehabilitation specialist (**Level 3**).

- E. Spondylolisthesis and spondylolysis of the thoracolumbar spine
 1. Description and etiology
 - a. *Spondylolisthesis* comes from the Greek words *spondylo*, meaning vertebrae, and *lithesis*, meaning slipping or sliding.
 - b. It most often occurs at L4–L5, followed by L5–S1.
 - c. The most frequent cause of spondylolisthesis is degenerative change related to chronic motion between two vertebrae that results in anterior subluxation and the development of lumbar pain.
 - d. *Spondylolysis* is the dissolution of, or a defect in, the pars interarticularis (the bony region between the superior and inferior articulating processes of individual vertebra; Sang-Bong & Sang-Wook, 2011). The defect may be an elongated, but intact, pars; an acute fracture; or a lytic lesion representing a fatigue fracture. Spondylolysis also is known as isthmic spondylolysis or type II spondylolisthesis.
 - e. Spondylolisthesis is classified as follows:
 - i. Type I: Dysplastic
 - a) Type I is a developmental disorder and characterized by the presence of dysplastic sacral facet joints that allow forward translation (movement) of one vertebra over another. Undue stress on the pars may result in fracture.
 - b) It often is associated with spina bifida and congenital defects of the pars interarticularis.
 - ii. Type II: Isthmic
 - a) Repeated fatigue fractures followed by remodeling causes the development of a stress fracture of the pars interarticularis, most often affecting L5–S1.

Figure 15. Decompression laminectomy

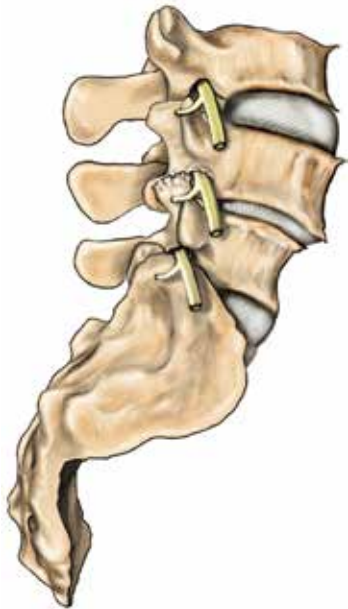


From Schnuerer, A., Gallego, J., & Manuel, C. (2003). Core Curriculum for Basic Spinal Training (2nd ed.). Memphis, TN: Medtronic Sofamor Danek. Image provided by Medtronic.

- b. Patient age and relevant comorbidities should be considered preoperatively to determine the need for preoperative cardiac clearance. This should be done well in advance of

- b) Type II also can be a developmental injury for some adolescents during growth spurts.
- c) This is the most common cause of low back pain in children.
- iii. Type III: Degenerative
 - a) Type III is characterized by forward slipping of the lumbar vertebrae with an intact neural arch, with associated degeneration of the facet joints (Monticone & Giovanazzi, 2008; **Figure 16**).

Figure 16. L4–L5 degenerative spondylolisthesis



From Schnuerer, A., Gallego, J., & Manuel, C. (2003). Core Curriculum for Basic Spinal Training (2nd ed.). Memphis, TN: Medtronic Sofamor Danek. Image provided by Medtronic.

- b) Type III is the most common subtype.
- c) Etiology is not known (Monticone & Giovanazzi, 2008).
- d) Type III is seldom seen in people younger than 50 years of age (Monticone & Giovanazzi, 2008).
- e) Female to male ratio 1:5–6 (Monticone & Giovanazzi, 2008)
- f) Slippage most often occurs at the L4–L5 level (Monticone & Giovanazzi, 2008).
- g) Type III may produce low back, sciatic, or radicular pain and leg weakness and may progress to spinal stenosis (Monticone & Giovanazzi, 2008).

- iv. Type IV: Traumatic
 - a) Type IV results from a fracture of the pedicles, the pars, or the superior/inferior articular processes caused by traumatic injury.
 - b) Type IV is rare.
 - c) Type IV can occur acutely after an injury, although most often it will develop during the weeks to months after the injury.
 - d) Type V: Pathological
 - e) Type V occurs as the result of an internal alteration causing destabilization of the facet mechanism producing a pathologic spondylolisthesis. These alterations can result from tumors, infection, Paget's disease, osteoporosis, or hyperthyroidism, among other disorders.
 - f) Grading: The degree of subluxation generally is measured using the Meyerding method. The superior surface of the sacrum is divided into fourths along its anteroposterior (AP) diameter. Then the degree of subluxation is noted as a grade.
 - Grade 1: 1%–25% slippage
 - Grade 2: 26%–50% slippage
 - Grade 3: 51%–75% slippage
 - Grade 4: 76%–100% slippage
 - Grade 5: More than 100% slippage

2. Incidence and epidemiology

- a. Type I: Of all populations, Inuit are most at risk for this type. As many as 50% of Inuit acquire this condition as a result of both genetic and environmental factors. There is a 2:1 ratio of women to men. In children this condition has been diagnosed as early as 3.5 months of age; 4% of cases are recognized by age 6, and 6% by age 14 (Herkowitz, 2009; Jones & Rao, 2009).
- b. Type II: Although type II spondylolisthesis is not a congenital condition, there is a positive correlation between congenital defects, including spina bifida occulta and scoliosis, and the development of type II spondylolisthesis. As many as 50% of spondylolysis cases will become type II spondylolisthesis. Affected men outnumber women by 2:1, although women have a higher likelihood of having a more severe grade. There is a higher incidence among Whites than among African Americans (6:1 ratio).

- c. Type III: This condition commonly occurs after the age of 40. Women are affected more than men by a 5:1 ratio. African American women are affected more than White women. Most commonly, type III spondylolisthesis occurs at L4–L5. Incidence increases with advancing age; other risk factors include diabetes, arthritis, smoking, and obesity (Watters et al., 2009).
 - d. Type IV: Traumatic spondylolisthesis is rare. Falls and parachuting injuries are most frequently associated with this type. More often, spondylolisthesis occurs after trauma and is related to the sequela of the recovery process.
 - e. Type V: Type V spondylolisthesis occurs with other disease processes and determining its incidence has been difficult. Incidence is increased with diseases affecting the bone structure, the generation of osteoblast, and conditions that increase the osteoclasts.
3. Diagnostic and physical exam findings
- a. Symptoms are dependent on the type and grade of spondylolisthesis.
 - b. Pain can begin insidiously and is aggravated by activity, especially back-extension types of movements.
 - c. Pain is in the low back with or without radiation.
 - d. Pain usually is worse with prolonged walking or standing and improves with sitting.
 - e. Symptoms often are similar to those of lumbar stenosis, but the patient may experience more back pain.
 - f. Patients may complain of a slipping sensation in the lower back.
 - g. Patients may have difficulty walking.
 - h. On examination the clinician may be able to palpate the “step-off” of the vertebrae.
 - i. In most cases the patient does not present with radicular pain because it occurs more often in high grades.
4. Surgical treatment options
- a. Surgical approaches depend on the degree of subluxation, patient symptoms, and neurological function.
 - b. Fusion procedures typically are necessary to stabilize the vertebrae.
 - c. A retrospective review of 426 patients undergoing fusion found that smoking 10 or more cigarettes per day increased the rate of non-union (Andersen et al., 2001). Smoking cessation lowered the risk to levels of nonsmokers. For this reason, some surgeons will not perform fusion procedures on patients who

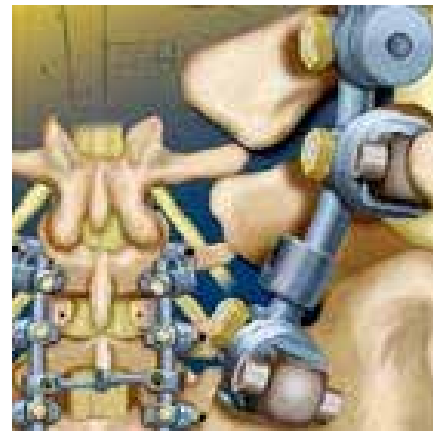smoke or will only schedule the surgery after a predefined period of smoking cessation (Whitesides, Hanley, & Fellrath, 2004).

d. Fusion techniques

- i. Posterior spinal fusion (PSF) with or without instrumentation.

This procedure is performed via an incision over the thoracolumbar spine with fusion of two or more vertebrae. The procedure involves decortication of the transverse processes, facet joints, and pars interarticularis. Autograft bone is harvested from either the surgical decompression site or an iliac crest and is placed over all decorticated surfaces. If instrumentation is used, it is laid down after pedicle screws are in place. Pedicle screw fixation is done using the largest screw the pedicle is able to hold (**Figure 17**). A 3-D image guidance system may be used for visualization.

Figure 17. Pedicle screw fixation: Posterior view



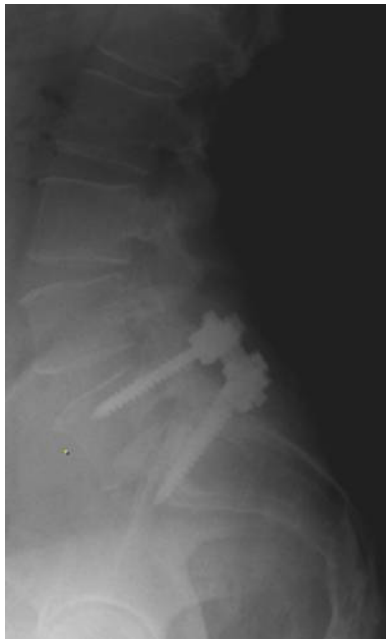From Schnuerer, A., Gallego, J., & Manuel, C. (2003). Core Curriculum for Basic Spinal Training (2nd ed.). Memphis, TN: Medtronic Sofamor Danek. Image provided by Medtronic.

- ii. Posterior interbody fusion (posterior lumbar interbody fusion [PLIF]/transforaminal lumbar interbody fusion [TLIF]).

During the PLIF procedure posterior elements are removed to gain access to the disk space. After the disk space is cleared, an interbody spacer (e.g., cages, allograft wedges, allograft bone dowel) is placed into the disk space with disk distraction. The distractors then are removed. The spacer remains in the disk space and is left under compression. The

fusion is strengthened by adding pedicle screw fixation (**Figure 18**). Instrumentation adds internal support to correct spine alignment (by replacing lumbar lordosis) and secures adequate stabilization while the vertebral bones fuse at approximately 6 months (Andersen, Videbaek, Hansen, Bunder, & Christensen, 2008). The TLIF procedure entails using a posterior approach to perform a unilateral facetectomy and laminectomy. Spacers (e.g., cages, femoral rings, allograft) packed with autograft bone and recombinant human bone morphogenetic protein are placed into the disk space. The operative site is supplemented with pedicle screw and rod instrumentation (Starkweather, 2006).

Figure 18. L5–S1 posterior lumbar interbody fusion: Lateral X ray



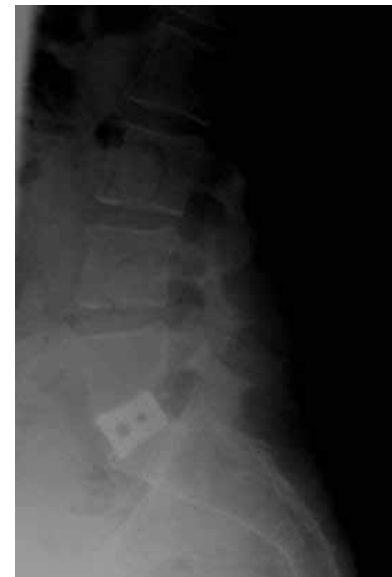© 2011 by Andrea Strayer. Reproduced with permission.

iii. Anterior interbody fusion

An anterior lumbar interbody fusion is performed using an abdominal approach. Indications include DDD with associated back pain. There should be no neural compression or degenerative spondylolisthesis because no direct nerve root decompression is achieved intraoperatively. During exposure care is taken to avoid vascular injury and superior hypogastric stretching or injury leading to retrograde ejaculation (Truumees & Brebach, 2004).

- a) Generally the anterior longitudinal ligament is divided and reflected to opposite sides to allow spine and disk work.
- b) The disk space is cleaned and an interbody device is placed in the disk space.
- c) The interbody device can be packed with recombinant human bone morphogenetic protein (Burkus, 2004).
- d) The femoral ring is packed with autograft (**Figure 19**).

Figure 19. Anterior lumbar interbody fusion: Lateral view

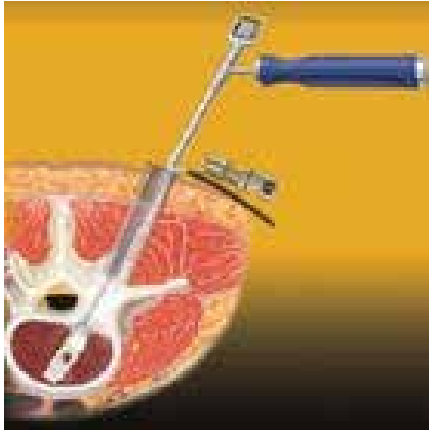


© 2011 by Andrea Strayer. Reproduced with permission.

- iv. Direct lateral interbody fusion (DLIF) or extreme lateral interbody fusion provides an alternative to cutting through the psoas muscle. Instead of accessing the spine through an anterior or posterior approach, the incision is made in the lateral flank and the fibers of the psoas muscle are gently separated (trans-psoas). Serial dilators and retractors are placed through the psoas muscle to be seated on the lateral aspects of the disk space and vertebral bodies. This is an open minimally invasive procedure performed under direct visualization.
- v. Combined anterior/posterior fusion Anterior/posterior lumbar fusions are indicated when instability from spondylolisthesis or other degenerative problems lead to the need for both anterior and posterior column fixation.

- vi. Minimal-access/minimally invasive fusion techniques
 - a) Minimally invasive percutaneous PLIF or TLIF procedures use a hybrid of microsurgical and endoscopic techniques through four 2-cm incisions (**Figure 20**). The DLIF procedure is an open minimally invasive procedure that is performed under direct visualization in contrast to percutaneous.

Figure 20. Minimal-access (minimally invasive) fusion



From Schnuerer, A., Gallego, J., & Manuel, C. (2003). Core Curriculum for Basic Spinal Training (2nd ed.). Memphis, TN: Medtronic Sofamor Danek. Image provided by Medtronic.

- b) During percutaneous procedures, an interbody distractor device is placed into the disk space to restore intervertebral height, and an appropriate-size graft is placed. The pedicle screw rod instrumentation is placed through the same incisions.
 - c) The guiding K-wire is advanced to the planned segmental fusion site. A multi-axial pedicle screw is passed over the K-wire, and the pedicle screw is then inserted into the pedicle. For each ipsilateral pair of pedicles within the motion segment that is fused, the rod inserter is passed through both screw heads.
- vii. Intraoperative image guidance
 - a) Preoperatively, a CT or MRI scan through the appropriate spinal levels is obtained and image data are transferred to the computer work station in the operating suite.
 - b) Three to five reference points for each spinal segment to be instrumented are selected and stored in

the image data set and then identified in the operative field and registered. This information allows the surgeon to have real-time 3-D information about the patient's bony anatomy during the operative procedure.

- 5. Preoperative, intraoperative, and postoperative management of spondylolisthesis and spondylolysis of the thoracolumbar spine
 - a. The general recommendations for preoperative, intraoperative, and postoperative management found in Sections V–VII should be followed.
 - b. Patient age, comorbidities, intraoperative positioning, and length of time for the procedure should be considered when determining the need for preoperative cardiac clearance.
 - c. The patient should receive information regarding activity and work restrictions during the postoperative period. Generally, he or she will need assistance with activities of daily living for the first week and will be off of work for 4–6 weeks.
 - d. Although movement of the fused vertebrae may be restricted following surgery, patients should be encouraged to increase walking distance weekly to maintain cardiovascular health.
 - e. Analgesics should be provided to manage surgical wound pain and enhance postoperative physical functioning.
- Recommendation:** Nurses should provide a clearly defined plan for increasing activity and weaning pain medications during the first few weeks following surgery based on the patient's status. Generally, the goal is to resume normal activities and begin titrating off of opioid medications by weeks 2–6 postoperatively (**Level 3**).
- F. Scoliosis and kyphosis of the thoracolumbar spine
 - 1. Description and etiology
 - a. Adult spinal deformities occur as a result of alterations in the skeletally mature spine (Li et al., 2009).
 - b. The spinal column is a 3-D structure with sagittal, coronal, and axial planes. These planes collectively determine one's posture.
 - c. The balanced spine consists of three curvatures including cervical lordosis, thoracic kyphosis, and lumbar lordosis. Values for these curvatures are on average 40 degrees of cervical lordosis, 20–50 degrees of thoracic kyphosis, and 31–79 degrees of lumbar lordosis

(Heary & Albert, 2007). Variations to these measurements can leave patients with altered equilibrium and subsequent deformity. Abnormal curvatures can occur as the result of trauma, inflammatory responses, osteoporotic fractures, infection, previous surgery, and degenerative changes (Roussouly & Nnadi, 2010).

d. In patients with thoracolumbar deformities, the degenerative cascade often starts with asymmetric disk deterioration. This can result in a lack of competency of the posterior elements. This lack of competency, especially at the facet joints, can result in ligamentous laxity, rotation, or listhesis. Increased hypermobility can lead to curve initiation and progression in all planes of the spine (Silva & Lenke, 2010).

e. Scoliosis is a coronal or lateral curvature of the spine with a Cobb angle of more than 10 degrees (Aebi, 2005). Scoliosis in adults can be characterized as idiopathic or de novo.

i. Adult idiopathic scoliosis refers to a history of adolescent idiopathic scoliosis with symptom or curve progression into adulthood. Weinstein and Ponsetti (1983) examined 102 subjects with idiopathic scoliosis. Their findings revealed that 68% of this cohort had curve progression as adults. Consequently, many of these patients will need interval follow-up for their scoliosis as they age. The most common treatment goal for adolescent idiopathic scoliosis is to prevent progression of deformity; in adult idiopathic scoliosis a common goal is to improve manifestations of the condition (Bess et al., 2009; Trobisch, Suess, & Schwab, 2010).

ii. De novo scoliosis describes a new onset of scoliosis in adulthood as a result of degenerative changes or arthritis. Degenerative curves likely are accompanied by a loss of normal lumbar lordosis with associated sagittal imbalance. These curves generally do not have rotation above the T10 vertebrae, which is likely in idiopathic scoliosis (Ploumis, Liu, Mehbod, Transfeldt, & Winter, 2009). Presenting symptoms of adult degenerative scoliosis may be multifactorial and often are consistent with worsening back pain, radicular pain, or a combination of both (Silva

& Lenke, 2010). Patients often present with pain and disability, which likely are the results of one or a combination of the following: DDD, central or foraminal stenosis, facet arthropathy, spinal imbalance, and muscle fatigue (Smith et al., 2009a).

f. Kyphosis is a sagittal deviation of the spinal column. One of the spinal column's most important functions is to maintain balance with the head over the pelvis (Heary & Albert 2007). When this position becomes altered, sagittal imbalance may result.

i. Spinal extension exercises, usually the first intervention prescribed, have been shown to prevent the natural progression of kyphosis (Ball, Cagle, Johnson, Lucasey, & Lukert, 2009).

ii. A deviation in normal spinal balance causes increased energy depletion, which can lead to several undesirable symptoms in this population. Symptoms consistent with sagittal plane imbalance include fatiguing back pain, muscle spasms, difficulty with horizontal gaze and balance, loss of height, and a progressive leaning-forward posture.

iii. Many patients progress to needing assistive devices because of unnatural posture. Patients begin to find ways to compensate and often alter the position of their hips and knees, which may cause further disk discomfort (Chang et al., 2011).

iv. Sagittal alignment is one of the most important predictors of surgical outcomes in adults with spinal deformity and is an important variable in the surgical plan (Roussouly & Nnadi, 2010).

2. Incidence and epidemiology

a. As our population lives longer, the number of people with spinal deformities will increase.

b. Degenerative changes are likely the source of increased prevalence of scoliosis and kyphosis in adults. Prevalence of scoliosis rises to 8% in adults 25 years of age and older, and up to 68% of those ages 60–90 (Trobisch et al., 2010).

c. Scoliosis is more common in women. In the United States it affects approximately 2%–3% of the female population.

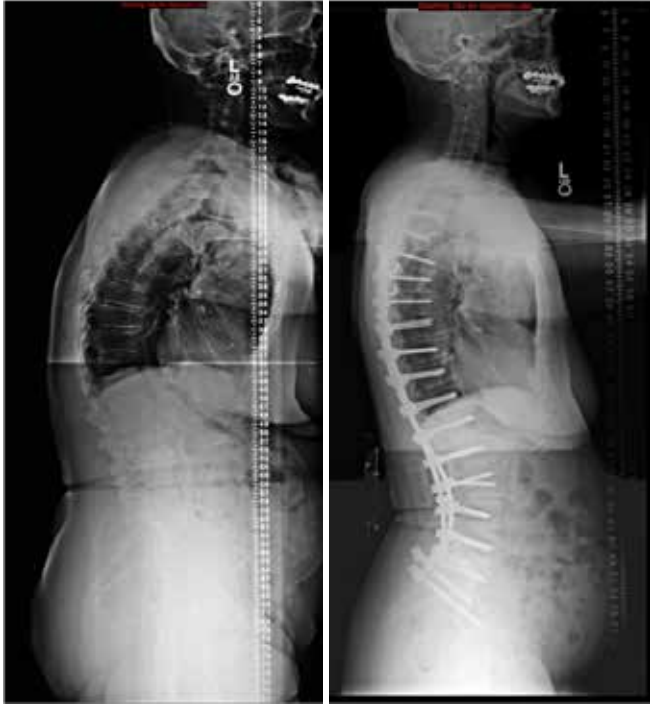
3. Diagnostic and physical exam findings

a. Cobb angle measurements are best measured on long cassette (14 x 36-inch, or scoliosis) standing AP radiographs.

- b. Sagittal alignment is measured from the relationship of the C7 plumb line to the posterior superior aspect of S1. It also is measured on a standing long cassette X ray. If the plumb line falls in front of the sacrum by more than 2–4 cm, the patient has positive sagittal balance. Negative sagittal balance occurs if the plumb line falls behind this landmark (Heary & Albert, 2007).
 - c. Determining a surgical plan involves many variables. Surgeons use different X-ray techniques to help determine the best surgical option for patients with deformities. Standing, supine, supine sidebending, and lateral lumbar bolster scoliosis X rays all are helpful when making these decisions. With supine sidebending X rays, if the scoliotic deformity corrects more than 30%, the curve is considered flexible and is not likely to require osteotomies for correction. Those with curves that do not correct more than 30% with bending maneuvers are determined to be rigid and commonly will need osteotomies to correct their deformity (Silva & Lenke, 2010).
4. Surgical treatment options
- a. When nonoperative measures fail to help adults with deformities, many will seek surgical treatment. Surgical treatment varies for each patient because each case is unique. Improvements in operative techniques and instrumentation and increased knowledge of biomechanics have led to surgical advancements in recent years (Yadla, Maltenfor, Ratliff, & Harrop, 2010).
 - b. Indications for surgery
 - i. Curve progression
 - ii. Pain despite conservative treatments
 - iii. Neurological deficit
 - iv. Pulmonary compromise also should be considered, but is not likely with coronal curves less than 90 degrees (Heary & Albert, 2007).
 - v. Age, rate of progression, magnitude of deformity, and functional status all should be a part of the decision-making process (Pekmezci, Berven, Hu, & Deviren, 2009).
 - c. There are six levels of surgical treatment for the deformity population (Silva & Lenke, 2010).
 - i. Decompression
 - ii. Decompression and limited fusion
 - iii. Decompression and lumbar curve fusion
 - iv. Decompression with anterior and posterior spinal fusion. The following interbody approaches are used in an attempt to promote a circumferential spinal fusion. These approaches often are used at the lumbosacral junction at which spinal load is the greatest (Maeda, Buchowski, Kim, Mishihiro, & Bridwell, 2009). Interbody fusions often are done in a second-stage approach.
 - a) Anterior lumbar interbody fusion (ALIF)
 - b) DLIF
 - c) TLIF
 - v. Thoracic instrumentation and fusion extension
 - vi. Inclusion of osteotomies for specific deformities
 - a) A Smith-Peterson osteotomy is a posterior column osteotomy used with flexible deformities. Each level of osteotomy will produce approximately 10–15 degrees of correction (**Figure 21**).
 - b) A pedicle subtraction osteotomy (PSO) is a three-column osteotomy used to treat fixed deformities. A PSO is likely to achieve 30–40 degrees of correction by shortening the posterior column while the vertebral body undergoes a wedge resection.
 - c) Vertebral column resection: Osteotomies alone cannot fix some severe deformities; in such cases vertebral column resection may be considered. This procedure involves a spinal-shortening vertebral body resection.
 - d. Advancements in surgical techniques have produced posterior segmental fixation systems with contoured rods and pedicle screws. These systems presently are used in the spinal deformity population (Heary & Albert, 2007).
 - e. Treatment goals of spinal deformity surgery
 - i. Decrease pain, stop deformity progression, and improve function (Heary & Albert, 2007).
 - ii. Obtain solid fusion and establish a balanced 3-D spine (Heary & Albert, 2007). Rebalancing the spine is critical and is linked to patient satisfaction and improved outcomes (Silva & Lenke, 2010).
 - iii. A majority of patients who undergo spinal deformity surgery report

improvements in back and leg pain (Smith et al., 2009a, 2009b) and functional ability (Zimmerman, Mohamed, Skolasky, Robinson, & Kebaish, 2010); however, there is a higher morbidity and mortality risk compared to other fusion procedures (Smith et al., 2011).

Figure 21. Stage 1: T4-S1/Ilium posterior spinal fusion with Smith Peterson osteotomies, Stage 2: L4/5 L5/S1 ALIF (pre- and postoperative, lateral view)



© 2011 by Kristen Smith. Reproduced with permission.

- f. Spinal deformity surgeons also will see patients to manage complications resulting from previous operations (Heary & Albert, 2007). Revision surgeries sometimes are necessary to treat flat-back deformity, adjacent segment degeneration, proximal junctional kyphosis, and pseudoarthrosis.
5. Preoperative, intraoperative, and postoperative management of scoliosis and kyphosis of the thoracolumbar spine
 - a. The general recommendations for preoperative, intraoperative, and postoperative management found in Sections V–VII should be followed.
 - b. In anticipation of the extent and length of surgery, preoperative assessment of risk factors that may impair optimal outcomes is recommended well in advance of the date of surgery. Assessments include the following:
 - i. Cardiac status: Patients with clinical risk factors should likely undergo a preoperative cardiology consult and cardiac stress test.
 - ii. Pulmonary status: Patients with known pulmonary disease may require a pulmonology evaluation with possible pulmonary function tests. Smoking cessation is important for this population. Smoking can delay bone healing and increase rates of pseudoarthrosis. Nicotine screening before surgery is recommended (Andersen et al., 2001; Glassman et al., 1998; Whitesides et al., 1994).
 - iii. Nutritional status: A patient's nutritional status can greatly affect surgical outcomes. It has been shown to take approximately 6–12 weeks for nutritional parameters to return to baseline after spinal reconstructive surgery (Lenke, Bridwell, Blanke, & Baldus, 1995). Consequently, optimizing preoperative nutritional stores is essential. If preoperative malnourishment is suspected, albumin, prealbumin levels, and total lymphocyte count should be tested (Halpin et al., 2010).
 - iv. Hepatic and renal evaluations should include correcting any coagulopathy and optimizing renal function. If a patient has a history of coagulopathy, DVT, or pulmonary embolism (PE), a prophylactic inferior vena cava (IVC) filter should be considered.
 - v. Weight loss: Weight loss should be encouraged for obese patients because those who are obese are at increased risk for perioperative complications (Pull ter Gunne, van Laarhove, & Cohen, 2010).
 - vi. Bone health: A recent dual-energy X-ray absorptiometry (DEXA) scan and vitamin D level should be assessed and treatment for osteopenia and osteoporosis should be initiated if not already started. Bone-morphogenic proteins (BMP) have been introduced into spinal fusion surgeries within the past decade. BMP consists of a family of growth factors that induce bone growth. With the use of these proteins, findings suggest increased frequency of fusion when compared to fusions using

iliac crest bone graft (Maeda et al., 2009).

Recommendation: A preoperative evaluation to identify and treat intraoperative and postoperative risk factors should be performed preoperatively with coordination of appropriate consulting services (**Level 3**).

G. Fractures of the thoracolumbar spine

1. Description and etiology

a. Fractures along the thoracolumbar spine may occur as the result of high-energy forces from trauma such as vehicle accidents or falls. These traumatic fractures may cause acute neurological problems; some may be nonrecoverable spinal cord injuries.

b. Less often, fractures occur spontaneously or as the result of low impact due to weakened bones from osteoporosis, tumor growth, or congenital conditions.

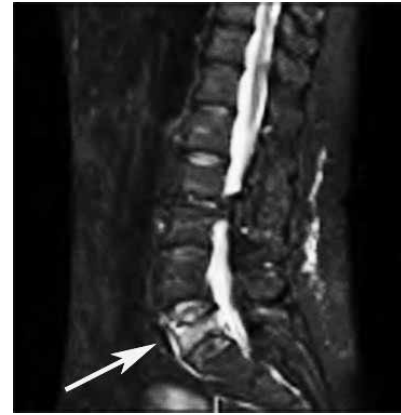c. Identifying the type, location, and stability of the fracture is key to determining the optimum treatment protocol.

i. **Stability:** The vertebral column by convention is divided into the Denis 3 column system (Denis, 1983). The anterior column consists of the anterior half of the vertebral body and disk and the anterior longitudinal ligament. The middle column consists of the posterior half of the vertebral body and disk and the posterior longitudinal ligament. The posterior column consists of the osseous structures and ligaments posterior to the posterior longitudinal ligaments. As a general rule, stability may be compromised if there is damage in more than one of the three columns as outlined by Denis.

ii. Compression or wedge fractures are flexion fractures with which the anterior portion of the vertebrae fails and the posterior portion of the vertebrae remains relatively stable (**Figure 22**). Vertebral height loss in the anterior column usually does not lead to neurological deficits, but loss of vertebral body height exceeding 50% may lead to instability. If multiple compression fractures are present, kyphosis and loss of overall body height may be noticed.

iii. Osteoporosis-related fractures in the thoracolumbar spine typically are wedge compression fractures.

Figure 22. L5 compression fracture



© by Angela Starkweather. Reproduced with permission.

- iv. Burst fractures are axial compression fractures with which the vertebrae loses height in two columns; they may be stable or unstable depending on the degree of damage to the posterior column. There may be a risk of neurological compromise with this type of fracture that is associated with retropulsion of bony fragments into the spinal canal. Burst fractures occur most frequently at the thoracolumbar junction.
- v. Flexion-distraction fractures, also known as Chance or seatbelt fractures, lead to damage in all three of the columns as defined by Denis (1983). Damage to the posterior column is variable and neurological impairment is dependent on the degree of this damage and the number of vertebrae affected.
- vi. Rotational fracture-dislocation injuries are unstable shear-type failures and involve damage to both the vertebral body and surrounding soft tissues, with relative motion between two vertebrae often leading to significant spinal cord compression and severe neurological consequences.
- vii. The Spine Trauma Study Group (Vacarro et al., 2006) developed a systematic approach to classifying thoracolumbar spine injuries based on input from recognized expert spinal surgeons. Using this system, healthcare providers can rate injuries based on physical morphology, degree of neurological deficits, and condition of posterior ligaments

surrounding the injured vertebrae. This rating system is a general guideline regarding the appropriateness of conservative nonsurgical treatment as well as the necessity and type of surgery that may be required. Patel and colleagues (2009) demonstrated the reliability and validity of this tool on various spinal trauma cases.

- d. Conservative nonsurgical treatment of fractures is indicated for patients with intact neurological status and an intact posterior ligamentous complex. These patients typically are those with anterior wedge fractures and mild burst fractures. Wood and colleagues (2003) found that patients with mild burst fractures treated with nonsurgical interventions had equivalent outcomes in terms of pain and functioning compared to those who underwent surgical procedures. Nonoperative treatment generally involves bracing or casting and medications to control pain. Braces or casts are worn for a number of weeks in many cases to help with stabilizing the spine during initial healing. For patients who present with nonacute wedge fractures, bracing usually is not indicated.
 - e. Osteoporotic fractures typically are treated with bisphosphonates, calcium, and vitamin D supplements. Calcitonin is a hormone used to slow bone resorption and has been shown to improve pain in osteoporotic fractures. Calcitonin is available in injectable and nasal spray forms. It also is used to treat hypercalcemia and should not be used in patients with low blood calcium. Physical therapy and activity as tolerated should be encouraged as soon as possible to prevent complications from immobility. Weight-bearing exercise is important for patients at risk for further osteoporotic compression fractures and can improve strength and balance (Dusdal et al., 2011). All exercise programs should be carried out under the supervision of health-care professionals after the appropriate rest time for patients with vertebral fractures.
2. Incidence and epidemiology
 - a. Vehicular accidents, violence, and falls account for the majority of high-energy traumatic spinal cord injuries, including fractures, and are most common in younger men.
 - b. Spinal fractures associated with osteoporosis are most common in postmenopausal women, with approximately 25% having at least one compression fracture during their lifetime (Old & Calvert, 2004).
 3. Diagnostic and physical exam findings
 - a. Plain radiographs initially are used to characterize the type of fracture. CT scans and MRI may be indicated for traumatic fractures or to better visualize the soft tissues surrounding the fractures. Marrow edema surrounding a fracture is an indication of a more recent fracture.
 - b. Symptoms of vertebral fractures are dependent on the location and type of fracture. Patients with traumatic fractures may present with severe pain and acute neurological deficits.
 - c. Osteoporotic fractures may be asymptomatic and be discovered during routine testing; in some cases acute pain may be the presenting symptom. Patients may show signs of kyphosis, loss of overall height, and reduction in mobility. Loss of pulmonary function and weight loss or decreased appetite may result from pressure on internal organs resulting from kyphotic changes in the spine (Lemke, 2005).
 4. Surgical treatment options
 - a. The type of surgical management of thoracolumbar fractures is highly dependent on the type and severity of the fracture. Using input from various experts in the Spine Trauma Study Group, Vaccaro and colleagues (2006) described possible treatment protocols for patients with more complicated types of fractures while discussing the need to evaluate each case. A recent systematic review of eleven articles supports early rather than late surgical stabilization of spine injuries. Early stabilization, for individuals both with and without spinal cord injury, may lessen the patient's critical care and hospital length of stays and days on mechanical ventilation (Carreon & Dimar, 2011).
 - b. For patients with neurological compromise, surgical strategies include anterior decompression, posterior decompression, and combined surgeries.
 - c. Although single-level flexion-distraction injuries may be treated with a brace if a patient is neurologically intact, treatment with internal fixation and instrumentation may be needed; fusion usually is avoided, especially in younger patients, to preserve normal motion (Eichinger, Arrington, Kerr, & Molinari, 2007).
 - d. Vertebroplasty and kyphoplasty are minimally invasive surgical procedures that have gained popularity for treatment of compression and burst fractures (Doody, Czarnecki, Given, & Lyon, 2009) in the absence

of neurological deficits. These procedures are used to treat recent fractures as evidenced by bone marrow edema via MRI. The method involves a percutaneous injection of cement into the vertebral body, with the goal of fracture stabilization. In the case of kyphoplasty, a balloon-tipped catheter is inserted into a pathway made by needle access into the vertebral body. Using this method, the cement is inserted at a lower pressure than used in vertebroplasty, allowing for better control and the benefit of expanding the vertebral body and improving the kyphotic curve (Sinha, Sedgley, Sutcliffe, & Timothy, 2010). These methods have been shown by some authors to provide statistically significant improvements in pain control and vertebral body height when compared to control groups (Farrokhi, Alibai, & Maghami, 2011).

- i. Although there have been reports of the benefits of vertebroplasty and kyphoplasty in the literature, Buchbinder and colleagues (2009) carried out a double-blinded study in which the control group received sham surgery instead of typical conservative nonsurgical treatment. There was no significant difference in patient outcomes between the two groups, suggesting that the surgical intervention led to a placebo effect. This outcome strongly suggests that nonsurgical management of compression and burst fractures without neurological deficits may be equally effective.
- ii. Complications from vertebroplasty and kyphoplasty include standard postoperative complications along with allergic reactions and possible cement leakage that can potentially lead to compression within the spinal cord or pulmonary embolism (Robinson, Heyde, Försth, & Olerud, 2011).
- iii. Kasperk and colleagues (2010) tracked patients for 3 years after kyphoplasty surgery and found they exhibited reduced pain and higher levels of mobility compared with a control group. In addition, their data indicated the kyphoplasty-treated group had fewer additional vertebral fractures when compared to those in the control group, although the sample size was small.
- e. Outcomes for patients with traumatic flexion-distraction and rotational injuries are

variable and highly dependent upon factors such as neurological status at the time of injury.

5. Preoperative, intraoperative, and postoperative management of fractures of the thoracolumbar spine
 - a. The general recommendations for preoperative, intraoperative, and postoperative management found in Sections V–VII should be followed.
 - b. Due to the wide range of effects on neurological functioning, rehabilitation needs vary considerably.

Recommendation: Nurses should perform a thorough assessment of functional needs and coordinate consultation services accordingly (**Level 3**).

H. Cauda Equina Syndrome (CES)

1. Description and etiology
 - a. The cauda equina consists of nerve roots, both motor and sensory, below the level of the conus medullaris and within the spinal canal as described in Section II.
 - b. The cauda equina provides motor innervation to the lower extremities, sensory innervation to the saddle region, and parasympathetic innervation to the bladder and distal bowel.
 - c. Compressive damage to these lumbar and sacral nerve roots with associated neurological damage results in CES.
 - d. The most frequent cause of CES is midline prolapse of an intervertebral disk, and the most common levels reported are in the lower lumbar region, particularly L4–L5. Other conditions that may cause CES include tumor, trauma, spinal epidural hematomas and abscesses, and free fat graft following discectomy. CES also may be a postoperative complication after lumbar spine surgery. CES rarely occurs without a precipitating event; in these cases a history of spinal stenosis often is present.
 - e. Compressive lesions may create a partial block, causing varying degrees of impairment in addition to asymmetry of the disturbance. A complete block is not required to produce a CES. Clinical evidence has demonstrated little correlation between the degree of block and the development of CES (Olivero et al., 2009).
 - f. Significant neurological changes can occur with 75% restriction of the cauda equina.
2. Incidence and epidemiology

CES is rare, affecting an estimated 1% of people secondary to disk herniation (Olivero et al., 2009).

3. Diagnostic and physical exam findings
 - a. Low back pain with bilateral sciatica is a presenting symptom. Radicular pain often is described as stabbing, shooting, or burning.
 - b. Saddle and perineal anesthesia are hallmark signs. The patient may describe difficulty urinating, overflow incontinence, or the absence of or decreased feeling in the perineal region (**Table 2**).

Table 2. Symptoms Related to CES

Involvement	Symptoms
Motor	Limb weakness or weakness of movements; hypotonia in the limb or muscle group; diminished or absent reflexes
Sensory	Hypoesthesia or hyperesthesia with objective signs of sensory loss in a dermatomal or myotomal distribution
Urinary sphincter control	Difficulty initiating micturition, retention, stress incontinence; loss of urethral sensation
Bowel dysfunction	Constipation, loss of appreciation of rectal distension; loss of anal tone and sensation
Sexual dysfunction	Sudden onset of difficulty achieving an erection or orgasm

- c. Urinary retention of more than 500 ml using the bladder scanner method in the presence of two or more classic CES symptoms was found by Domen, Hofman, van Santbrink, and Weber (2009) to strongly predict CES findings on MRI.
- d. Progressive symptoms likely are the result of a combination of compressive damage to the nerves along with ischemic changes in the relatively hypovascular region of the cauda equina (Jensen, 2004).
- e. Healthcare providers should assess motor weakness (specifically motor nerve root), sensory changes (numbness or tingling along a specific distribution), and reflexes (decreased or absent) to evaluate patients presenting with low back pain for CES.
- f. If CES is suspected, an examination and evaluation of perianal sensation is warranted. Sensory assessment of the perineal region should include the perianal area, the natal cleft, and the posterior scrotal or labial areas.
- g. Due to the potential for permanent neurological impairment for patients with CES, it is recommended that patients presenting with likely CES symptoms undergo urgent MRI evaluation (Bell, Collie, & Statham, 2007).
- h. MRI studies are standard practice to determine the level of pathology, aid in diagnosis of the primary pathologic lesion, and assist

in determining optimum surgical treatment. CT and X ray analyses also may help to determine the diagnosis if MRI is unavailable or contraindicated.

Frequently there is incomplete CES with asymmetric motor and sensory changes and variability in bowel and bladder symptoms. These cases are treated in a similarly urgent manner as complete CES to prevent progressive neurological deterioration.

4. Surgical treatment options
 - a. CES from a herniated lumbar disk is an absolute indication for decompressive surgery. Transcanal approaches include standard open lumbar laminectomy for the resection of a compressive lesion or discectomy and microdiscectomy for the treatment of herniated disks.
 - b. Although controversy exists regarding the effectiveness of early surgical intervention, surgery continues to be recommended within 48 hours after a patient presents with CES symptoms.
 - c. Some controversy surrounding the effectiveness of early intervention stems from both the low incidence of this condition and mixed data regarding patients presenting with both complete and incomplete CES symptoms (DeLong, Polissar, & Neradilek, 2008).
 - i. In a prospective study Qureshi and Sell (2007) found no significant difference in residual symptoms, including disability, pain, and incontinence, between patients who received surgery within 24 hours of symptom onset and those who received surgery more than 24 hours after symptom onset. However, a significantly improved outcome was found in patients who were continent of urine at presentation. In many cases early intervention may prevent the progression of partial sphincter disturbance to complete lesions. This progression has been documented to occur even within the first 24 hours of symptom onset (Kennedy, Soffe, McGrath, Stephens, & Walsh, 1999).
 - ii. Predictors of residual dysfunction are the presence of significant sphincter disturbance and complete perineal anesthesia at presentation. Patients with complete CES and those exhibiting urinary retention may have a poor

- prognosis even if surgery is carried out within the 24- to 48-hour time frame (Arrigo, Kalanithi, & Boakye, 2011).
- iii. The goal of surgery is to prevent progression of neurological dysfunction; resolution of presenting symptoms of neurologic dysfunction is variable and often proceeds over a number of months. Some patients continue indefinitely with neurological deficits.
 - iv. Although a retrospective review by Olivero and colleagues (2009) found that recovery of sensory, motor, and bladder function was not related to the timing of the surgical intervention, other authors (Arrigo et al., 2011) presented data indicating earlier intervention led to improved outcomes. Arrigo and colleagues (2011) also found that patients with CES undergoing surgery after 48 hours had higher complication rates and more nonroutine hospital discharges. Current guidelines encourage early surgical intervention on an emergency or urgent basis within 48 hours of symptom onset.
- d. Patients who present postoperatively with CES symptoms after lumbar spine surgery may require further surgical intervention to prevent long-term complications even in the absence of lesions detected with MRI imaging (Jensen, 2004).
5. Preoperative, intraoperative, and postoperative management of CES
 - a. The general recommendations for preoperative, intraoperative, and postoperative management found in Sections V–VII should be followed.
 - b. Patients should be made aware that improvements may not be immediate and arrangements should be made for appropriate short- and long-term follow-up care. Pay special attention to assessing for return of bladder and bowel function. Bladder scanning should be used to ensure adequate bladder emptying during the postoperative period. Patient teaching should be implemented for patients who have residual neurological deficits. Patients may need instruction on intermittent catheterization in the hospital setting and as a part of discharge planning.
 - c. To reflect the wide range of effects on neurological functioning, rehabilitation needs vary considerably.

- d. Nurses should assess functional needs and help patients identify potential resources to enhance patient and family coping and adjustment.

Recommendation: Nurses should perform a postoperative assessment of mental health and functional needs of patients to determine the need for consultation services and discharge teaching (**Level 3**).

IV. Review of Diagnostic Studies

A. Nursing responsibilities

1. Although it is not within the RN scope of practice to order diagnostic studies, nurses should be familiar with each diagnostic modality and be able to provide education and guidance when preparing patients for their procedures.
2. Obtain a medical history and inform the provider of any possible contraindications to the examination. For procedures requiring the injection of a contrast material, the nurse will need to obtain data on the patient's allergies, medications, and renal function. If the patient has allergies to contrast material, is currently taking medications such as metformin that increase risks associated with contrast, or has a decreased glomerular filtration rate, the ordering provider should be informed and appropriate interventions taken.
3. Patients undergoing MRI should be assessed for the presence of ferromagnetic foreign bodies such as spinal hardware, implanted pumps, or spinal stimulators. The radiologist should be made aware of any foreign bodies because they may contraindicate the MRI or require posttest reprogramming.
4. Nurses should assess for anxiety and treat patients appropriately with anxiety-reducing interventions such as visualization techniques and deep-breathing exercises. In addition, sedatives may be necessary to alleviate anxiety and promote tolerance of the examination. Earplugs or earphones can be offered to patients to increase their tolerance.
5. Provide information to patients regarding the indications, risks, and contraindications of the diagnostic test and let them know what to expect before, during, and after the procedure. Instructions should be provided regarding which medications to take before the test and how to resume home medications, oral intake, and activities before and after the test; clothing and accessories to wear; and transportation needs.

6. Inform the patient about when to expect study results and encourage him or her to contact their provider to follow up.
- B. X ray: X rays are inexpensive and noninvasive. X rays show the general changes of arthritis and bony alignment, but are limited to assessment of bony structures only. Flexion/extension X rays may help to identify segmental instability. Serial X rays may be used to evaluate bone healing and maturation of surgical fusion.
 - C. CT: A CT scan may be used either as an adjunct to MRI or for patients with thoracolumbar spine issues who cannot undergo MRI evaluation. A CT scan shows the bony elements of the spine very well, as well as the disks, nerves, and ligaments. Although it provides excellent visualization of the bony components, the CT scan is less sensitive to changes in the soft tissues of the spine. Contrast agents may be useful to highlight masses and abnormal tissue and fluid collections. A CT scan also is occasionally used in conjunction with computerized neuro-navigation for intraoperative 3-D image guidance during thoracolumbar fusions.
 - D. MRI: Using strong magnetic fields and radio frequencies, MRI can provide useful information on all tissues in the spine (e.g., bones, soft tissues, spinal cord, nerves, ligaments, musculature, disks). MRI is superior to CT for the evaluation of soft-tissue structures (Lurie, Doman, Spratt, Tosteson, & Weinstein, 2009). Contrast agents may be used to highlight masses, epidural scarring as a result of previous spine surgeries, and abnormal tissue or fluid collections. MRI is contraindicated for patients who have metallic implants or a cardiac pacemaker.
 - E. Bone scan: Radioactive tracers are injected into the patient. These tracers attach themselves to areas of increased bone production or increased vascularity associated with tumor or infection. Bone scans are often used when evaluating for spondylolysis (i.e., destructive lesion of the vertebra), occult fractures, or suspected bony metastasis.
 - F. Diskogram: A diskogram may be used to evaluate for DDD. Under fluoroscopic guidance, a contrast agent is injected into the nucleus pulposus. The clinician performing the procedure assesses the amount of contrast agent administered and at what point the patient experiences pain. The clinician then notes whether the patient's typical pain is elicited. Radiographs are taken to assess whether the contrast agent stays within the nucleus pulposus or leaks out of the disk. All of these data may be useful in determining whether a specific degenerated disk seen on an MRI or CT scan is the cause of the patient's symptoms; however, the utility of this test remains controversial (Carragee et al., 2009; Manchikanti, Glaser, Wolfer, Derby, & Cohen, 2009).
 - G. Myelogram/postmyelogram CT: A contrast agent is injected under fluoroscopy into the intrathecal space through either lumbar puncture or cisternal puncture. The contrast agent then is visualized with radiographs, commonly with CT. The resulting images are useful for evaluating patients who cannot undergo MRI studies (e.g., people who have pacemakers) or as an adjunct to MRI. This test also is useful in evaluating for suspected CES (any mass lesion or infection that is within or impinging upon the thecal sac, arachnoiditis, or nerve root lesions).
 - H. Electromyography/nerve conduction velocities: Small needles are inserted into specific muscles to assess muscle activity and nerve conduction time and amplitude of electrical stimulation along specific nerves. Electromyography may be indicated for patients without a clear radiculopathy (i.e., pain in the anatomic distribution of the affected nerve root) to further assess and diagnose their pathology (Carstensen, Al-Harbi, Urbain, & Belhocine, 2011).

V. Preoperative, Intraoperative, and Postoperative Nursing Care

A. Preoperative nursing responsibilities

1. Preoperative planning several weeks before surgery
 - a. Describe the surgical procedure to the patient and family, including expected postoperative and long-term outcomes. Emphasize realistic expectations based on the patient's preoperative status and prepare the patient and family for potential care needs during recovery, such as assistance with activities of daily living.
 - b. Arrange for required preoperative testing. For procedures during which a substantial amount of blood loss is expected, the option for autologous blood donation may be offered at least 3–5 weeks before the scheduled procedure.
 - c. Psychosocial factors can greatly affect surgical outcomes. Optimizing social support and mental health is imperative (Laxton & Perrin, 2003).
 - d. When cardiac clearance is indicated by the surgeon, make sure that preoperative medical clearance has been obtained and ensure that all recommendations have been implemented.

e. Assess nutritional status preoperatively.

Recommendation: Preoperative nutritional assessment and treatment may improve thoracolumbar surgical outcomes (**Level 3**).

- i. Nutritional status may affect surgical outcomes such as infection potential and the quality and rate of healing; however, no evidence has been identified in the literature addressing surgical outcomes in patients undergoing spinal surgery. Regardless, it has been shown to take approximately 6–12 weeks for nutritional parameters to return to baseline after spinal reconstructive surgery (Lenke, Bridwell, Blanke, & Baldus, 1995). Consequently, optimizing preoperative nutritional stores may be beneficial, particularly in patients with severe malnourishment, which can be evaluated with albumin, prealbumin levels, and total lymphocyte count (Halpin et al., 2010). No evidence was identified to guide interventional strategies for malnourishment.
 - ii. Another concern regarding fusion surgery is bone health, and a bone health evaluation with a recent DEXA scan and vitamin D level to guide preoperative treatment for osteopenia and osteoporosis has been advocated. A recent retrospective study among 176 women who underwent surgery for scoliosis did not show correlations among bone mineral density measured by DEXA, rate of fusion, or complications, however (Yagi, King, & Boachie-Adjei, 2011).
 - f. Encourage patients to anticipate and arrange for perioperative and postoperative care needs. Patients should arrange for help with household chores, yard work, pets, and other tasks.
 - g. Patients undergoing multilevel spinal fusions must be informed that they may lose a significant amount of flexibility depending on the levels of their fusion. Simple hygiene tasks and activities of daily living often become difficult because of this loss of flexibility when patients' lumbar vertebrae are fused down to their sacrum. Preoperative physical therapy concentrating on leg flexibility and strengthening may be of significant benefit for this population.
 - h. Coordinate the equipment and personnel required for the operative procedure. When scheduling the surgical procedure, learn from the surgeon whether special equipment is necessary, including fusion hardware, which may necessitate contacting the device representative; intraoperative nerve conduction monitoring or image guidance, which may require specific personnel; and cadaver bone or human recombinant bone morphogenic protein, which may require special ordering.
2. Preoperative planning the week before and day of surgery
 - a. Verify that informed consent has been obtained by the surgeon.
 - b. Ensure that a recent preoperative history and physical has been performed and documented. Verify the findings of the physical exam and document any changes. Report changes to the surgeon.
 - c. Explain to patients where and when to arrive and the surgery time.
 - d. Instruct patients about their medications. Specific instructions should be provided regarding medications to be taken the morning of surgery with a sip of water. Advise patients regarding which medications should be discontinued before surgery, such as herbal products, nonsteroidal antiinflammatory drugs (NSAIDs), anticoagulants, antiplatelet medications, and direct thrombin inhibitors.
 - e. Ensure patients have adequate pain medications that can be administered until the time of surgery.
 - f. Instruct patients about eating and drinking restrictions.
 - g. Remind patients to wear comfortable clothing and to leave jewelry and valuables at home.
 - h. Tell patients to remove dentures, partial plates, eyeglasses, contact lenses, nail polish, and sculptured nails.
 - i. Implement measures to reduce DVT risk.
Recommendation: The use of mechanical prophylaxis may decrease the rate of DVT in patients undergoing spinal surgery (**Level 2**).
 - i. Antithrombotic Therapies in Spine Surgery, a comprehensive review of the literature performed by the North American Spine Society, was published in 2009. The work group found limited information regarding the relative incidence of DVT or PE complications for specific prophylactic

measures according to particular spine procedures.

- ii. The most common elective spine surgeries performed through a posterior approach (e.g., microdiscectomy, laminectomy) are associated with low risk for DVT.
- iii. Because of their ease of use and low rate of complications, mechanical prophylaxis of any type, including pneumatic sequential compression devices or compression stockings, should be considered for any inpatient spine procedures and for those at risk for DVT in accordance with recommendations from the Agency for Healthcare Research and Quality (AHRQ).
- iv. Initiation of mechanical compression before or at the beginning of surgery and continuation until patients are fully ambulatory is an established standard of care (Geerts et al., 2004).

Recommendation: Low-molecular-weight heparin (LMWH) or low-dose warfarin may be used postoperatively following elective combined anterior-posterior (circumferential) spine surgery or in patients with high-risk for thromboembolic disease (**Level 3**).

- i. Recommendations in *Antithrombotic Therapies in Spine Surgery* on the use of LMWH or low-dose warfarin for patients undergoing circumferential spine surgery and those at high risk for thromboembolic disease (patients who have experienced multiple trauma, malignancy, or hypercoagulable states) are based on work group consensus (North American Spine Society [NASS], 2009).
- ii. Limited data exist concerning outcomes in patients undergoing other types of spine surgery, and only one study was identified since the publication of *Antithrombotic Therapies in Spine Surgery* (NASS, 2009). A retrospective cohort analysis that included 3,870 patients undergoing elective spine surgery found that preoperative DVT prophylaxis did not influence the incidence of DVT, PE, or subdural hematoma (Cunningham, Swamy, & Thomas, 2011).
- iii. The work group also recommended that the duration of chemoprophylaxis should be decided based on the underlying pathological condition and weighed

against the risk of epidural hematoma because there is no available literature to support an ideal duration (NASS, 2009).

- iv. A review of the literature did not find evidence to address wound complications or neurologic decline from epidural hematoma related to the use of DVT chemoprophylaxis.
- j. Infection control measures should be implemented to reduce the risk of infection.

Recommendation: Patients undergoing spine surgery should receive preoperative prophylactic antibiotics (**Level 2**).

- i. After a comprehensive review of the literature, evidence-based guidelines were published by NASS (2007) entitled *Antibiotic Prophylaxis in Spine Surgery*. Recommendations include the use of preoperative prophylactic antibiotics for instrumented and noninstrumented spine surgery (Shaffer, Baisden, Fernand & Matz, 2013).
- ii. Little evidence was found to guide the selection of a specific agent or dosing; however, the work group recommended considering an appropriate broad spectrum antibiotic when instrumented fusion is performed for those at risk for polymicrobial infection (patients with neuromuscular scoliosis, myelodysplasia, or traumatic complete spinal cord injury; Shaffer et al., 2013).
- iii. Older age, obesity, malnutrition, diabetes, higher American Society of Anesthesiologists score, and posterior approaches were associated with increased infection rates after spine surgery (Schuster et al., 2010; Shaffer et al., 2013).
- iv. Besides intraoperative interventions, no additional evidence was identified that addressed infection-control measures since the publication of *Antibiotic Prophylaxis in Spine Surgery*.

Recommendation: Standards of practice to reduce infections in hospitalized patients should be implemented in patients undergoing spinal surgery (**Level 3**).

- i. Although no evidence was identified specifically pertaining to patients undergoing spinal surgery, AHRQ recommends several important infection-control standards of care. These include hand hygiene and measures to reduce catheter-related urinary tract

infections, such as aseptic insertion and catheter care and prompt removal of unnecessary catheters.

- ii. Recommendations to reduce central venous catheter infections and ventilator-associated pneumonia also should be implemented when appropriate.

B. Intraoperative nursing responsibilities

1. Perform a “time out”—right patient, right surgery, right site.
2. Verify that prophylactic DVT prevention measures have been implemented if appropriate.
3. Verify that preoperative antibiotics have been administered.
4. Alert surgical staff of patient allergies, particularly to latex, so that appropriate measures can be implemented.
5. Ensure the correct and most recent diagnostic imaging equipment is available for the surgeon. Intraoperative CT image-guided navigation systems have been introduced and are demonstrating increased safety and accuracy in the placement of posterior spinal instrumentation (Tormenti et al., 2010).
6. If autologous blood donation was provided, notify the blood bank at which the donation was collected to allow for adequate preparation time.
7. Monitor proper patient positioning throughout the procedure.
 - a. Table options are surgeon specific.
 - b. If the patient is obese, consider using a Jackson table.
 - c. The patient’s abdomen should hang freely to reduce intraoperative bleeding by minimizing vena cava compression and epidural venous pressure.
 - d. Appropriately pad pressure points to decrease the incidence of pressure sores attributable to long operating times. Pressure points and genitalia should be checked frequently to avoid positioning injuries.
8. Assist in the coordination of a pain-management plan based on patient needs.

Recommendation: Preemptive or intraoperative pain management interventions may reduce opioid requirements postoperatively (Level 1).

 - a. Numerous studies were identified that evaluated preemptive and intraoperative methods of pain management in patients undergoing spinal procedures. Although most studies were double-blind RCTs, there were a limited number of studies for each pain regimen for which the patient sample was selected

by procedure and small samples were used (fewer than 100 subjects). Collectively, these studies support the use of preemptive or intraoperative pain management interventions for patients undergoing spine surgery. Because of wide variations in pain techniques and study samples, however, no specific intervention has been identified as superior to others.

- b. Preemptive oral controlled-release oxycodone for elective lumbar discectomy (one or two levels) along with morphine patient-controlled analgesia (PCA) reduced pain scores and nausea and vomiting and was associated with earlier recovery of bowel function and higher patient satisfaction compared to placebo (Blumenthal, Min, Marquardt, & Borgeat, 2007).
- c. Among 73 patients undergoing PLIF, continuous subcutaneous morphine was associated with significantly fewer side effects and lower equivalent pain scores compared with continuous epidural morphine and diclofenac sodium (Voltaren®; Yukawa, Kato, Ito, Terashima, & Horie, 2005).
- d. Two studies evaluated preemptive gabapentin (Neurontin®), but the results were inconsistent. In the first study a preemptive dose of gabapentin was evaluated for postoperative pain relief after single-level lumbar discectomy and its effect on fentanyl consumption during the initial 24 hours after surgery (Pandey et al., 2005). Patients were divided into five groups to receive placebo or gabapentin 300, 600, 900, or 1,200 mg 2 hours before surgery. Patients receiving 600 mg or higher had significantly lower pain scores than patients receiving 300 mg; however, there were no differences in pain scores between groups receiving at least 600 mg. The authors concluded that gabapentin 600 mg is the optimal dose for postoperative pain relief after lumbar discectomy. In contrast, preemptive gabapentin 800 mg (in two equally divided doses) or placebo was given preoperatively to 60 adult patients undergoing elective lumbar laminectomy or discectomy (Radhakrishnan, Bithal, & Chaturvedi, 2005). Pain scores, total morphine consumption, and side effects were similar in the two groups.
- e. Patients undergoing elective single-level lumbar microdiscectomy who received two doses of rofecoxib 50 mg preoperatively

- required significantly less morphine postoperatively compared to placebo (Bekker et al., 2002).
- f. Reuben, Buvanendran, Kroin, and Raghunathan (2006) demonstrated that celecoxib (Celebrex) alone or in combination with pregabalin (Lyrica®) dosed 1 hour preoperatively and 12 hours after 1–2-level spinal fusion with harvest of iliac crest bone graft was effective at significantly reducing pain at rest and with activity. Study patients receiving celecoxib alone or in combination with pregabalin demonstrated decreased opioid use and less postoperative sedation and nausea than the placebo group, which received PCA morphine alone. The celecoxib/pregabalin combination had more effect than either agent given alone.
 - g. Many intraoperative interventions for pain management also showed effectiveness in reducing postoperative pain compared to usual care or placebo. Intravenous ketamine administered to patients undergoing major lumbar spine surgery was effective (Lofthus et al., 2010), and a mixture of ketamine and morphine in patients undergoing lumbar disk surgery was superior to either agent alone (Aveline, Hetet, Vautier, Gautier, & Bonnet, 2006).
 - h. Magnesium sulfate infusion in patients undergoing lumbar disk surgery (Oguzhan, Gunday, & Turan, 2008) and in those who had major lumbar surgery (Levaux, Bonhomme, Dewandre, Brichant, & Hans, 2003) was more effective in reducing pain than usual care. A one-time dose of intrathecal morphine after posterior lumbar interbody fusion resulted in lower opioid requirements than seen in the placebo control group up to 20 hours after surgery (Ziegeler et al., 2008).
Epidural morphine combined with clonidine for postoperative pain relief after lumbar disk surgery was superior to bupivacaine or placebo in reducing pain and analgesic requirements (Bonhomme et al., 2002).
 - j. A single epidural injection of bupivacaine and tramadol in patients undergoing discectomy by the posterior approach with or without instrumentation resulted in lower pain scores and significant delay in the first demand for analgesic medications compared to placebo (Sekar et al., 2004).
 - k. Celecoxib administered at a dose of 200 mg twice a day for 72 hours starting the evening before surgery did not significantly reduce morphine consumption (Karst et al., 2003).
 - l. Patients who received 20–80 mg dexamethasone (Decadron®) intravenously during surgery because of visible signs of compression of the affected nerve root had significantly less pain on movement and lower morphine requirements. In another study methylprednisolone locally applied to the affected nerve roots was effective in patients undergoing posterior lumbar discectomy and decompressive laminectomy with or without instrumented fusion for degenerative spinal diseases in reducing the cumulative morphine dose and postoperative pain compared to placebo (Jiraattanaphochai, Jung, Thienthong, Krisanaprakornkit, & Sumananont, 2007). Both 40-mg and 80-mg intravenous dexamethasone versus placebo in patients with a single-level discectomy resulted in lower pain scores and less opioid use postoperatively (Aminmansour, Khalili, Ahmadi, & Nourian, 2006).
 - m. A comparison of pain interventions in lumbar discectomy cases revealed that intrathecal or epidural morphine resulted in lower postoperative pain scores than paraspinal bupivacaine or placebo (Yorukoglu, Ates, Temiz, Yamali, & Kecik, 2005).
 - n. Preoperative epidural anesthesia with morphine for posterior lumbar spinal fusion resulted in more stable blood pressure and less blood loss and analgesic requirements than placebo (Yoshimoto et al., 2005).
 - o. Adcon-L, an adhesion control in a barrier gel that acts as a barrier to the development of epidural fibrosis when mixed with morphine, resulted in lower pain scores, less analgesic use, and shorter hospital stays compared with placebo (Mastronardi, Pappagallo, Puzzilli, & Tatta, 2002).
 - p. Intrathecal administration of neostigmine after single-level lumbar discectomy was more effective in reducing pain and analgesic requirements compared to placebo (Khan, Hamidi, Miri, Majedi, & Nourijelyani, 2008).
 - q. Bupivacaine injected into the paravertebral muscles and subcutaneous tissues along with a piece of autologous fat soaked in 40 mg of methylprednisolone for 10 minutes did not lead to a significant reduction in pain scores compared with placebo among patients with lumbar discectomy (Mirzai, Tekin, & Alincak, 2002).

- r. Continuous epidural infusion of 0.1% ropivacaine (Gottschalk et al., 2004) or 0.5% marcaine into the subfascial aspects of the wound (Elder, Hoh, & Wang, 2008) resulted in lower pain scores, lower opioid consumption, and higher patient satisfaction when compared with placebo.

Recommendation: Opioid analgesics administered via patient-controlled devices can effectively reduce postoperative pain (**Level 1**).

- a. Although not all patients undergoing thoracolumbar spine procedures require intravenous or epidural analgesics, the use of patient-controlled devices has been shown to be superior compared to patient-requestion (as needed) administration. The studies reviewed included a meta-analysis, RCTs, and retrospective studies.
- b. A recent meta-analysis demonstrated slightly higher patient satisfaction and pain control scores with use of PCA when compared to traditional patient-requested or nurse administered opioid analgesics (Hudcova, McNicol, Quah, Lau, & Carr, 2006). Patients using PCA took more opioids and demonstrated more itching compared to their cohorts, but no other significant differences in side effects were found (Hudcova et al., 2006).
- c. Patient-controlled epidural analgesia (PCEA) has been shown to provide adequate postoperative pain control and patient satisfaction as an alternate to PCA (Fisher et al., 2003). A clinical advantage of PCEA over PCA for patients undergoing spine fusion was the lower quantity of opioids consumed, although the PCEA group experienced significantly more side effects than the PCA group.
- d. The use of PCEA has been shown to provide better postoperative analgesia and to decrease the amount of opioid consumption compared with patient-controlled intravenous analgesia in a retrospective review of 245 medical records of adult patients undergoing major spine surgery (Cata et al., 2008).

Recommendation: High-dose nonsteroidal anti-inflammatory drugs (NSAIDs) should be avoided in patients receiving lumbar fusion procedures (**Level 2**).

- a. NSAIDs should be avoided for the first several months after spinal fusion because these medications may decrease the rate of fusion

(Dahners & Mullis, 2004; Li, Zhang, & Cai, 2011).

- b. Park, Moon, Park, Oh, and Lee (2005) evaluated rates for lumbar fusion for patients who received PCA continuous infusions of ketorolac and morphine versus morphine alone for the first 3 days postoperatively. They reported that patients were nearly six times more likely to develop a nonunion of fusion with the addition of PCA ketorolac and discouraged the use of NSAIDs after posterolateral fusion.
- C. Postoperative nursing responsibilities
- 1. Monitoring neurological functioning
 - a. Although standards of monitoring neurological functioning vary by setting (intensive care unit versus care unit), neurological assessments should be carried out on a frequent basis during the postoperative period to gauge effects of surgical intervention. Changes in sensation, strength, or pain levels should be reported to the surgeon immediately, especially if patients show deterioration compared to the preoperative state. Patients should be made aware that improvements may not be immediate and arrangements should be made for appropriate short- and long-term follow-up care.
 - b. In the event of significant intraoperative nerve root manipulation or postoperative neurological deficits, the physician may order postoperative steroids for 24–48 hours. Antibiotics may be continued for 24 hours.
 - c. Monitor for postoperative complications including
 - i. Superficial wound infections (0.9%–5% incidence)
 - a) Increased risk with age, long-term steroid use, obesity, or diabetes mellitus
 - b) Most superficial infections are caused by *S. aureus*.
 - c) Mild infections usually are treated with 7–14 days of oral antibiotics.
 - ii. Increased motor deficit (1%–8% incidence)
 - a) Can be sustained during intraoperative positioning: compression neuropathies, anterior tibial compartment syndrome, pressure on the eye, cervical spine injuries
 - b) Can be transient with nerve root stretching or manipulation

- c) Diagnostic imaging may be required to ensure spinal stability and integrity of the spinal cord.
- iii. Unintended durotomy (CSF leak; 0.3%–13% incidence)
 - a) Generally revealed intraoperatively but may present postoperatively as a wound leak, a collection, or a postural headache
 - b) In most circumstances activity is restricted to a flat-lying position for 24–48 hours; gradually raise the head of the bed.
 - c) May be repaired with a 4.0 silk or nylon sutures, fibrin glue, or muscle plug (may be necessary for poor quality dura or difficult locations)
 - d) Possible sequelae include a CSF fistula (external CSF leak) or pseudomeningocele.
 - e) In some situations the physician may elect to have a blood patch placed to plug the tunnel.
- iv. Pseudomeningocele (0.7%–2% incidence)
 - a) Appears similar radiographically to a spinal epidural abscess
 - b) If a dural tear is suspected or visualized, the patient is maintained in a flat position for 24–48 hours to minimize dural pressure. Raise the head of the bed slowly (10 degrees every hour) until upright. If the patient complains of positional headache (i.e., headache when upright), then resume a flat-lying position.
 - c) Some surgeons may place a lumbar drain to decrease dural pressure and allow for dural repair.
 - d) Surgical exploration may be necessary if symptoms do not resolve.
- v. Instability
 - a) Instability usually is found in predisposed patients undergoing decompression without fusion, especially if a significant amount of facet is removed.
 - b) Obtain flexion and extension films to determine the amount of movement and the need for fusion.
- vi. Direct injury to neural structures during surgery may result in transient or permanent neurological deficits (<1% incidence).
 - vii. Deep infections: Lower than 1% incidence; this includes diskitis at 0.5%, spinal epidural abscess at 0.67%, and osteomyelitis
 - viii. Thrombophlebitis and DVT with risk of pulmonary embolism: 0.1% incidence
- 2. Wound care
 - a. Closely monitor surgical wounds for signs and symptoms of excessive blood loss and infection.
 - b. Wound drainage amounts should be measured per protocol and significant changes in drainage quickly reported.
 - c. Changes in temperature and white blood cell count should also be monitored because changes can indicate wound infection.
- 3. Mobility
 - a. Patients should mobilize quickly unless ordered differently because of the type of surgery or complication (e.g., CSF leak). If a CSF tear has occurred, the surgeon may order flat bed rest. This often is dependent on the degree of tear, ease of repair, and surgeon preference. For a persistent CSF leak, a lumbar drain or external ventricular device may be implemented.
 - b. Instruct and help patients to roll to the side and bring their legs down while simultaneously rising up with the torso from the bed. This minimizes twisting at the waist.
 - c. Instruct and help patients to rise from a chair using their legs rather than pushing off with their back.
 - d. Patients may benefit from use of a walker or other assistive devices if they are deconditioned, had a multilevel laminectomy, or have difficult mobility.
 - e. Evaluate patients for inpatient physical therapy referral needs for gait training and a walker evaluation.
 - f. Instruct patients to take short walks to avoid excessive fatigue; note their preoperative walking endurance.

Recommendation: Prescribing an exercise program starting 4–6 weeks postsurgery may lead to a more rapid reduction in pain and disability than no treatment (**Level 1**).

 - i. A recent meta-analysis evaluated the effectiveness of rehabilitation after lumbar disk surgery and found low-quality evidence showing that exercise is more effective than no treatment for pain, and moderate-quality evidence showing that exercise is more effective

for functional status at short-term follow-up (Ostelo, Costa, Maher, de Vet, & van Tulder, 2008, 2009). None of the studies reported that exercise increased the reoperation rate. In addition, the analysis found low-quality evidence showing no significant differences between supervised and home exercises and their effects on short-term pain relief or functional status.

- ii. In contrast, an RCT examined the effects on outcome up to 2 years after spinal decompression surgery of two types of postoperative physiotherapy, spine stabilization exercises or mixed techniques, versus simply instructing patients to stay active (Mannion, Denzler, Dvorak, Muntener, & Grob, 2009). There was no significant difference between groups in levels of pain or disability at 12 and 24 months after surgery. The authors concluded that advising patients to keep active by carrying out the type of physical activities they most enjoy appears to be just as effective as administering a supervised rehabilitation program.
- iii. An RCT was conducted to investigate the effectiveness of a psychomotor therapy focusing on cognition, behavior, and motor relearning compared with exercise therapy applied during the first 3 months after lumbar fusion (Abbott, Tyni-Lenné, & Hedlund, 2010). Both groups received a home-based exercise program with pain-contingent training of back, abdominal, and leg muscle functional strength and endurance; stretching; and cardiovascular fitness. The psychomotor therapy improved functional disability, self-efficacy, outcome expectancy, and fear of movement or (re)injury significantly more than exercise therapy at 3-, 6-, 9-, and 12-month follow-ups. Similar results occurred for pain coping, but group differences were nonsignificant at 2–3 years follow-up.

Recommendation: High-intensity exercise programs appear to provide a faster decrease in pain and disability than low-intensity programs for patients receiving lumbar microdiscectomy (**Level 2**).

- i. A recent meta-analysis found low-quality evidence that high-intensity exercises are slightly more effective than low-intensity exercise programs for pain in the short term, and moderate evidence that they are more effective for functional status in the short term (Ostelo et al., 2008, 2009).
- ii. In an RCT to evaluate a progressive exercise program patients who had undergone a single-level lumbar microdiscectomy were randomly allocated to receive education only or exercise and education (Kulig et al., 2009). The exercise intervention consisted of a 12-week periodized program of back extensor strength (force-generating capacity) and endurance training and mat and upright therapeutic exercises. Patients who received the progressive exercise program and education had significantly lower disability scores and greater improvement in distance walked.
- g. If a brace is ordered, instruct patients in its use and assist during the first few times to ensure correct use.

Recommendation: When spinal bracing is ordered, the patient should have it properly fitted and receive information on how to wear the brace (**Level 3**).

- i. Braces are widely used to decrease back pain and disability despite the lack of conclusive evidence regarding their efficacy.
- ii. A recent meta-analysis found there was little or no difference in back pain prevention or reduction of sick leave between people with low back pain who used back supports and those who received no treatment, or between people who received education on lifting techniques (van Duijvenbode, Jellema, van Poppel, & van Tulder, 2008).
- iii. Spinal braces can be used for numerous conditions including fractures and scoliosis or as an intervention after lumbar fusion to reduce flexion/extension, which is thought to interfere with the fusion process (Agabegi, Ferhan, Asghar, & Herkowitz, 2010).
- iv. A systematic review found no evidence that bracing had an effect on traumatic thoracolumbar fractures (Giele et al., 2009).

- v. A recent meta-analysis found low-quality evidence showing that a brace curbed adolescent scoliosis curve progression at the end of growth better than observation and electrical stimulation, and low-quality evidence showing that a rigid brace is more effective than an elastic one (Negrini et al., 2010).
 - vi. In patients with lumbar stenosis, braces may be used to decrease lumbar lordosis. Although prolonged use theoretically can cause muscle atrophy and weakness, this has not been substantiated with evidence. The efficacy of lumbar braces for treating acute and chronic lumbar stenosis is unknown (Siebert et al., 2009).
4. Pain control
 - a. Medication to control pain varies widely with the type of surgery performed.
 - b. For patients undergoing complicated fusion surgeries with instrumentation, PCA systems with morphine or dilaudid frequently are used during the early postoperative days; patients undergoing less invasive surgeries may start with oral pain medications directly after surgery.
 - c. In all cases patients should be weaned from intravenous pain medications as soon as is feasible. Patients should be educated about the complications of opioid pain medications, including long-term dependence, constipation, dizziness, and respiratory depression.
 - d. Morphine, hydrocodone (Vicodin[®]), or oxycodone (Roxicodone[®]), with or without acetaminophen (Tylenol[®]), may be prescribed as needed when patients are able to take oral medications.
 - e. NSAIDs taken as needed can be beneficial to manage postoperative pain (Cassinelli, Dean, Garcia, Furey, & Bohlman, 2008). However, NSAIDs should be avoided during the first several months after spinal fusion because they are thought to possibly decrease the rate of fusion (Dahners & Mullis, 2004; Li et al., 2011).
 - f. Neuropathic pain medications (e.g., gabapentin) may be beneficial.
 - g. Antispasmodics may be prescribed if muscle spasms are present.
 - h. Heat may be applied to treat spasms and muscular tension.
Ice may be applied to treat radicular pain for no more than 20 minutes per hour.
 5. Nutrition
 - a. As with other types of surgery, oral feedings should be given with or without supplements as soon as patients are stable and able to tolerate oral intake.
 - b. Glucose control has been shown to decrease postsurgical complications such as wound infections and pneumonia. Perioperative intensive glucose control is recommended (Halpin et al., 2010).
Recommendation: Enteral or parenteral nutrition may lead to more rapid normalization of nutritional parameters in patients undergoing staged or complex spinal procedures (**Level 2**).
 - i. A prospective randomized trial was conducted to evaluate the effects of total parenteral nutrition (TPN) among 46 patients undergoing same-day or staged fusion of 10 or more levels (Lapp et al., 2001). The results indicated that TPN administration was safe and patients randomized to receive TPN showed a trend toward more rapid normalization of nutritional parameters. However, there was no statistically significant reduction in complications, which was consistent with past studies (Hu, Fontaine, Kelly, & Bradford, 1998).
 - ii. Although not specific to spinal surgery, Story and Chamberlain's (2009) literature review found that early enteral feeding decreased the duration of postoperative ileus and length of stay. They noted that because early feeding does not increase the occurrence of associated complications, it may be used as a strategy to prevent postoperative ileus.
 6. Constipation prevention
 - a. Consider initiating techniques preoperatively.
 - b. Ensure adequate water intake.
 - c. Diet should include adequate fresh fruits, vegetables, and fiber.
 - d. Stool softeners such as docusate should be administered two to three times per day in patients receiving opioid analgesics. Geriatric patients are particularly prone to constipation.
 - j. Gentle massage may be used away from the incision.
 - k. Make sure patients frequently change positions.

- e. Motility agents such as senna should be used only as needed.
- 7. Urination
 - a. A Foley catheter should be kept in place until patients can stand to void or reliably use a urinal or bedpan. The goal should be to remove the Foley catheter within 24 hours of surgery.
 - b. Urinary hesitancy, especially immediately postoperative, usually is transient.
 - c. Assess urinary output, frequency, and volume.
 - d. Assess whether there is adequate emptying. Bladder scanning or intermittent bladder catheterization may be necessary to assess for retention or incomplete emptying. For patients with residual bowel or bladder functional deficits, a bowel/bladder program should be developed and patient teaching should be implemented.
- 8. Discharge planning
 - a. Discharge planning should be initiated preoperatively.
 - b. Reinforce the following: no lifting, bending, or twisting; no sitting for long periods of time. Avoid heavy lifting (anything heavier than a gallon of milk) for the first 4–6 weeks. Avoid prolonged sitting or standing for the first 4–6 weeks, including long car trips.
 - c. Remind patients to frequently change positions.
 - d. Remind patients to not drive while using opioids or other medications that may cause drowsiness.
 - e. Explain to patients that sexual activity may resume as indicated by the surgeon; generally this is 2–6 weeks after surgery.
- f. Ensure the patient is aware of return-to-work and activity recommendations. Return to work will vary depending on the type of work (sedentary roles earlier than heavy labor). Return to work may be a gradual progression to full time.
- g. Reinforce alternative planning and problem solving for practical everyday activities (e.g., vacuuming, doing laundry, performing child care).
- h. Incision care varies with the type of closure.
 - i. Assess the incision to be sure it is clean and dry.
 - ii. Care varies widely depending on the type of closure (staples, sutures, skin glue).
 - iii. In general, the incision needs to be monitored daily for redness, drainage, and signs of infection. Patients and caregivers need to be instructed on incision care, evaluating for signs and symptoms of infection, and when and whom to call with questions or problems.
- i. Follow-up scoliosis X rays should be considered at intervals of 6 weeks, 12 weeks, 6 months, 1 year, and 2 years after deformity correction. These X rays will help evaluate for hardware failure, proximal junctional kyphosis, pseudoarthrosis, and adjacent segment disease.
- j. Review medications, including those for pain management, and provide a plan to decrease the use of opioid medications during the following weeks as incisional pain subsides.

References

- Abbott, A. D., Tyni-Lenné, R., & Hedlund, R. (2010). Early rehabilitation targeting cognition, behavior, and motor function after lumbar fusion: A randomized controlled trial. *Spine*, 35(8), 848–857.
- Aebi, M. (2005). The adult scoliosis. *European Spine Journal*, 14, 925–948.
- Agabegi, S. S., Ferhan, A., Asghar, F. A., & Herkowitz, H. N. (2010). Spinal orthoses. *Journal of the American Academy of Orthopedic Surgeons*, 18, 657–667.
- Aliabadi, H., & Isaacs, R. (2009). Lumbar spinal stenosis: A brief review. *Neurosurgery Quarterly*, 19(3), 200–206.
- American Association of Neuroscience Nurses. (2005, April). *Best practices position statement*. Glenview, IL: Author.
- Aminmansour, B., Khalili, H. A., Ahmadi, J., & Nourian, M. (2006). Effect of high-dose intravenous dexamethasone on postlumbar discectomy pain. *Spine*, 31(21), 2415–2417.
- Andersen, T., Christense, F. B., Laursen, M., Hoy, K., Hansen, E. S., & Bunger, C. (2001). Smoking as a predictor of negative outcome in lumbar spinal fusion. *Spine*, 26(23), 2623–2628.
- Andersen, T., Videbaek, T. S., Hansen, E. S., Bunder, C., & Christensen, F. B. (2008). The positive effect of posterolateral lumbar spinal fusion is preserved at long-term follow-up: A RCT with 11–13 year follow-up. *European Spine Journal*, 17, 272–280.
- Arrigo, R. T., Kalanithi, P., & Boakye, M. (2011). Is cauda equina syndrome being treated within the recommended time frame? *Neurosurgery*, 68(6):1520–1526.
- Atlas, S., Keller, R., Wu, Y., Deyo, R., & Singer, D. (2005). Long-term outcomes of surgical and nonsurgical management of lumbar spinal stenosis: 8 to 10 year results from the Maine lumbar spine study. *Spine*, 30(8), 936–943.
- Aveline, C., Hetet, H. L., Vautier, P., Gautier, J. F., & Bonnet, F. (2006). Peroperative ketamine and morphine for postoperative pain control after lumbar disk surgery. *European Journal of Pain*, 10(7), 653–658.
- Ball, J. M., Cagle, P., Johnson, B. E., Lucasey, C., & Lukert, B. P. (2009). Spinal extension exercises prevent natural progression of kyphosis. *Osteoporosis International*, 20(3), 481–489.
- Becske, T., & Nelson, P. (2009). The vascular anatomy of the vertebrospinal axis. *Neurosurgery Clinics of North America*, 20(3), 259–264.
- Bekker, A., Cooper, P. R., Frempong-Boadu, A., Babu, R., Errico, T., & Lebovits, A. (2002). Evaluation of preoperative administration of the cyclooxygenase-2 inhibitor rofecoxib for the treatment of postoperative pain after lumbar disk surgery. *Neurosurgery*, 50(5), 1053–1057.
- Bell, D. A., Collie D., & Statham, P. F. (2007). Cauda equina syndrome: What is the correlation between clinical assessment and MRI scanning? *British Journal of Neurosurgery*, 21(2), 201–203.
- Berg, S., Tullberg, T., Branth, B., Olerud, C., & Tropp, H. (2009). Total disk replacement compared to lumbar fusion: A randomized controlled trial with 2-year follow-up. *European Spine Journal*, 18(10), 1512–1519.
- Bess, S., Boachie-Adjei, O., Burton, D., Cunningham, M., Shaffrey, C., Shelokov, A., et al. (2009). Pain and disability determine treatment modality for older patients with adult scoliosis, while deformity guides treatment for younger patients. *Spine*, 34(20), 2186–2190.
- Blumenthal, S., Min, K., Marquardt, M., & Borgeat, A. (2007). Postoperative intravenous morphine consumption, pain scores, and side effects with perioperative oral controlled-release oxycodone after lumbar discectomy. *Anesthesia & Analgesia*, 105(1), 233–237.
- Bonhomme, V., Doll, A., Dewandre, P. Y., Brichant, J. F., Ghassempour, K., & Hans, P. (2002). Epidural administration of low-dose morphine combined with clonidine for postoperative analgesia after lumbar disk surgery. *Journal of Neurosurgical Anesthesiology*, 14(1), 1–6.
- Bono, C. M., Watters III, W. C., Heggeness, M. H., Resnick, D. K., Saffer, W.O., Baisden, J., . . . Toton, J. F. (2009). North American Spine Society Evidence-Based Clinical Guidelines for Multidisciplinary Spine Care: Antithrombotic Therapies in Spine Surgery. Burr Ridge, IL, North American Spine Society. Accessed at www.spine.org/Documents/ResearchClinicalCare/Guidelines/AntithromboticTherapies.pdf
- Buchbinder, R., Osborne, R. H., Ebeling, P. R., Wark, J. D., Mitchell, P., Wriedt, C., et al. (2009). A randomized trial of vertebroplasty for painful osteoporotic vertebral fractures. *The New England Journal of Medicine*, 361(6), 557–568.
- Burkus, J. K. (2004). Bone morphogenetic proteins in anterior lumbar interbody fusion: Old techniques and new technologies. *Journal of Neurosurgery: Spine*, 1(3), 254–260.
- Carragee, E. J., Don, A. S., Hurwitz, E. L., Cuellar, J. M., Carrino, J., & Herzog, R. (2009). Does diskography cause accelerated progression of degeneration changes in the lumbar disk: A ten-year matched cohort study. *Spine*, 34(21), 2338–2345.
- Carreon, L. Y. & Dimar, J. R. (2011). Early versus late stabilization of spine injuries. *Spine*, 36(11), E727–E733. doi:10.1097/BRS.06013e3181fab02f
- Carstensen, M. H., Al-Harbi, M., Urbain, J. L., & Belhocine, T. Z. (2011). SPECT/CT imaging of the lumbar spine in chronic low back pain: A case report. *Chiropractic & Manual Therapies*, 19(2), 1–5.
- Cassinelli, E. H., Dean, C. L., Garcia, R. M., Furey, C. G., & Bohlman, H. H. (2008). Ketorolac use for postoperative pain management following lumbar decompression surgery: A prospective, randomized, double-blinded, placebo-controlled trial. *Spine*, 33(12), 1313–1317.
- Cata, J. P., Noguera, E. M., Parke, E., Ebrahim, Z., Kurz, A., Kalfas, I., et al. (2008). Patient-controlled epidural analgesia (PCEA) for postoperative pain control after lumbar spine surgery. *Neurosurgical Anesthesiology*, 20(4), 256–260.
- Chang, K. W., Len, X., Zhao, W., Cheng, C. W., Chen, T. C., Chang, K. I., et al. (2011). Quality control of reconstructed sagittal balance for sagittal imbalance. *Spine*, 36(3), 186–197.
- Choi, Y. (2009). Pathophysiology of degenerative disk disease. *Asian Spine Journal*, 3(1), 39–44.
- Chou, R., Atlas, S. J., Stanos, S. P., & Rosenquist, R. W. (2009). Nonsurgical interventional therapies for low back pain: A review of the evidence for an American Pain Society Clinical Practice Guideline. *Spine*, 34(10), 1078–1093.
- Chou, R., Baisden, J., Carragee, E. J., Resnick, D. K., Shaffer, W. O., & Loeser, J. D. (2009). Surgery for low back pain: A review of the evidence for an American Pain Society Clinical Practice Guideline. *Spine*, 34(10), 1094–1109.
- Chou, R., & Huffman, L. (2009). Evaluation and management of low back pain: Evidence review. Glenview, IL: American Pain Society.
- Chou, R., Loeser, J., Owens, D. K., Rosenquist, R. W., Atlas, S. J., Baisden, J., et al. (2009). Interventional therapies, surgery, and interdisciplinary rehabilitation for low back pain: An evidence-based clinical practice guideline from the American Pain Society. *Spine*, 34(10), 1066–1077.
- Cunningham, J. E., Swamy, G., & Thomas, K. C. (2011). Does preoperative DVT chemoprophylaxis in spinal surgery affect the incidence of thromboembolic complications and spinal epidural hematoma? *Journal of Spinal Disorders and Techniques*, 24(4), E31–E34.
- Dahners, L. E., & Mullis, B. H. (2004). Effects of nonsteroidal anti-inflammatory drugs on bone formation and soft-tissue healing. *Journal of American Academy of Orthopedic Surgery*, 12(3), 139–143.
- DeLong, W. B., Polissar, N., & Neradilek, B. (2008). Timing of surgery in cauda equina syndrome with urinary retention: Meta-analysis of observational studies. *Journal of Neurosurgery, Spine*, 8(4), 305–320.

- Denis, F. (1983). The three-column spine and its significance in the classification of acute thoracolumbar spinal injuries. *Spine*, 8, 817–831.
- Deyo, R., Nachemson, A., & Mirza, S. (2004). Spinal-fusion surgery: A case for restraint. *New England Journal of Medicine*, 350, 722–726
- Domen, P. M., Hofman, P. A., van Santbrink, H., & Weber, W. E. J. (2009). Predictive value of clinical characteristics in patients with suspected cauda equina syndrome. *European Journal of Neurology*, 16(3), 416–419.
- Doody, O., Czarnecki, C., Given, M. F., & Lyon, S. M. (2009). Vertebroplasty in the management of traumatic burst fractures: A case series. *Journal of Medical Imaging and Radiation Oncology*, 53(5), 489–492.
- Duffy, R. L. (2010). Low back pain: An approach to diagnosis and management. *Primary Care: Clinics in Office Practice*, 37(4), 729–741.
- Dusdal, K., Grundmanis, J., Luttin, K., Ritchie, P., Rompre, C., Sidhu, R., et al. (2011). Effects of therapeutic exercise for persons with osteoporotic vertebral fractures: A systematic review. *Osteoporosis International*, 22(3), 755–769.
- Eichinger, J. K., Arrington, E. D., Kerr, G. J., & Molinari, R. (2007). Bony flexion-distraction injury of the lower lumbar spine treated with instrumentation without fusion and early implant removal: A method of treatment to preserve lumbar motion. *Journal of Spinal Disorders and Techniques*, 20(1), 93–96.
- Elder, J. B., Hoh, D. J., & Wang, M. Y. (2008). Postoperative continuous paravertebral anesthetic infusion for pain control in lumbar spinal fusion surgery. *Spine*, 33(2), 210–218.
- Farrokhi, M. R., Alibai, E., & Maghami, Z. (2011). Randomized controlled trial of percutaneous vertebroplasty versus optimal medical management for the relief of pain and disability in acute osteoporotic vertebral compression fractures. *Journal of Neurosurgical Spine*, 14(5), 561–569.
- Ferguson, S. J., & Steffen, T. (2003). Biomechanics of the aging spine. *European Spine Journal*, 12(Suppl. 2), S97–S103.
- Fisher, C., Belanger, L., Gofton, E. G., Umedaly, H. S., Noonan, V., Abramson, C., et al. (2003). Prospective randomized clinical trial comparing patient-controlled intravenous analgesia with patient-controlled epidural analgesia after lumbar spinal fusion. *Spine*, 28(8), 739–743.
- Geerts, W. H., Pineo, G. F., Heit, J. A., Bergqvist, D., Lassen, M. R., Colwell, C. W., et al. (2004). Prevention of venous thromboembolism: The Seventh ACCP Conference on Antithrombotic and Thrombolytic Therapy. *Chest*, 126(Suppl. 3), 338S–400S.
- Giele, B. M., Wiertsema, S. H., Beelen, A., van der Schaaf, M., Lucas, C., Been H. D., et al. (2009). No evidence for the effectiveness of bracing in patients with thoracolumbar fractures. A systematic review. *Acta Orthopaedica*, 80(2), 226–232.
- Glassman, S. D., Rose, S. M., Dimar, J. R., Puno, R. M., Campbell, M. J., & Johnson, J. R. (1998). The effect of postoperative nonsteroidal anti-inflammatory drug administration on spinal fusion. *Spine*, 23(7), 834–838.
- Gottschalk, A., Freitag, M., Tank, S., Burmeister, M., Kreil, S., Kothe, R., et al. (2004). Quality of postoperative pain using an intraoperatively placed epidural catheter after major lumbar spinal surgery. *Anesthesiology*, 101(1), 175–180.
- Gruber, H. E., Ingram, J. A., Hoelscher, G. L., Zinchenko, N., Norton, H. J., & Hanley, E. N. (2009). Matrix metalloproteinase 28, a novel matrix metalloproteinase, is constitutively expressed in human intervertebral disk tissue and is present in matrix of more degenerated disks. *Arthritis Research & Therapy*, 11(6), 184–186.
- Guyatt, G., & Rennie, D. (2002). *User's guides to the medical literature: Essentials of evidence-based clinical practice*. Chicago: American Medical Association.
- Guyer, R.D., McAfee, P.C., Banco, R.J., Bitan, F.D., Cappuccino, A., Geisler, F.H., et al. (2009). Prospective, randomized, multicenter Food and Drug Administration investigational device exemption study of lumbar total disc replacement with the CHARITE artificial disc versus lumbar fusion: five-year follow-up. *The Spine Journal*, 9(5):374–386.
- Halpin, R. J., Sugrue, P. A., Gould, R. W., Kallas, P. G., Schafer, M. F., Ondra, S. L., et al. (2010). Standardizing care for high-risk patients in spine surgery: The Northwestern high-risk spine protocol. *Spine*, 35(25), 2232–2238.
- Heary, R. F., & Albert, T. J. (2007). *Spinal deformities: The essentials*. New York: Thieme Medical Publishers, Inc.
- Herkowitz, H. N. (2009). Degenerative lumbar spondylolisthesis: Evolution of surgical management. *Spine*, 9(7), 605–606.
- Hicks, G. E., Morone, N., & Weiner, D. K. (2009). Degenerative lumbar disk and facet disease in older adults: Prevalence and clinical correlates. *Spine*, 34(12), 1301–1306.
- Hudcova, J., McNicol, E. D., Quah, C. S., Lau, J., & Carr, D. B. (2006). Patient controlled opioid analgesia versus conventional opioid analgesia for postoperative pain. *Cochrane Database of Systematic Reviews*, 4, CD003348.
- Hu, S. S., Fontaine, F., Kelly, B., & Bradford, D. S. (1998). Nutritional depletion in staged spinal reconstructive surgery. The effect of total parenteral nutrition. *Spine*, 23(12), 1401–1405.
- Ireland, D. (2009). Molecular mechanisms involved in intervertebral disk degeneration and potential new treatment strategies. *Bioscience Horizons*, 2(1), 83–89.
- Jegade, K. A., Ndu, A., & Grauer, J. N. (2010). Contemporary management of symptomatic lumbar disk herniation. *Orthopaedic Clinics of North America*, 41(2), 217–224.
- Jensen, R. L. (2004). Cauda equina syndrome as a postoperative complication of lumbar spine surgery. *Neurosurgical Focus*, 16(6), e7.
- Jiraattanaphochai, K., Jung, S., Thienthong, S., Krisanaprakornkit, W., & Sumananont, C. (2007). Peridural methylprednisolone and wound infiltration with bupivacaine for postoperative pain control after posterior lumbar spine surgery: A randomized double-blinded placebo-controlled trial. *Spine*, 32(6), 609–616.
- Jones, T. R., & Rao, R. D. (2009). Adult ischemic spondylolisthesis. *Journal of the American Academy of Orthopaedic Surgery*, 17(10), 609–617.
- Kalichman, L., Cole, R., Kim, D. H., Li, L., Suri, P., Guermazi, A., et al. (2009). Spinal stenosis prevalence and association with symptoms: The Framingham Study. *The Spine Journal*, 9(7), 545–550.
- Karst, M., Kegel, T., Lukas, A., Ludemann, W., Hussein, S., & Piepenbrock, S. (2003). Effect of celecoxib and dexamethasone on postoperative pain after lumbar disk surgery. *Neurosurgery*, 53(2), 331–336.
- Kasperk, C., Grafe, I. A., Schmitt, S., Noldge, G., Weiss, C., DeFonseca, K., et al. (2010). Three-year outcomes after kyphoplasty in patients with osteoporosis with painful vertebral fractures. *Journal of Vascular and Interventional Radiology*, 21(5), 701–709.
- Katz, J. N. (2006). Lumbar disk disorders and low-back pain: Socioeconomic factors and consequences. *Journal of Bone and Joint Surgery*, 88(Suppl. 2), 21–24.
- Kennedy, J. G., Soffe, K. E., McGrath, A., Stephens, M. M., Walsh, M. G., & McManus, F. (1999). Predictors of outcome in cauda equina syndrome. *European Spine Journal*, 8, 317–322.
- Khan, Z. H., Hamidi, S., Miri, M., Majedi, H., & Nourijiyani, K. (2008). Post-operative pain relief following intrathecal injection of acetylcholine esterase inhibitor during lumbar disk surgery: A prospective double blind randomized study. *Journal of Clinical Pharmacy and Therapeutics*, 33(6), 669–675.

- Kulig, K., Beneck, G. J., Selkowitz, D. M., Popovich, J. M. Jr., Ge, T. T., Flanagan, S. P., et al. (2009). An intensive, progressive exercise program reduces disability and improves functional performance in patients after single-level lumbar microdiscectomy. *Physical Therapy*, 89(11), 1145–1147.
- Lapp, M. A., Bridwell, K. H., Lenke, L. G., Baldus, C., Blanke, K., & Iffrig, T. M. (2001). Prospective randomization of parenteral hyperalimentation for long fusions with spinal deformity: Its effect on complications and recovery from postoperative malnutrition. *Spine*, 26(7), 809–817.
- Laxton, A. W., & Perrin, R. G. (2003). The relations between social support, life stress, and quality of life following spinal decompression surgery. *Spinal Cord*, 41(10), 553–558.
- Lemke, D. M. (2005). Vertebroplasty and kyphoplasty for treatment of painful osteoporotic compression fractures. *Journal of the American Academy of Nurse Practitioners*, 17(7), 268–276.
- Lenke, L. G., Bridwell, K. H., Blanke, K., & Baldus, C. (1995). Prospective analysis of nutritional status normalization after spinal reconstructive surgery. *Spine*, 20(12), 1359–1367.
- Levaux, C., Bonhomme, V., Dewandre, P. Y., Brichant, J. F., & Hans, P. (2003). Effect of intra-operative magnesium sulphate on pain relief and patient comfort after major lumbar orthopaedic surgery. *Anaesthesia*, 58(2), 131–135.
- Li, Q., Zhang, Z., & Cai, Z. (2011). High-dose ketorolac affects adult spinal fusion: A meta-analysis of the effect of perioperative nonsteroidal anti-inflammatory drugs on spinal fusion. *Spine*, 36(7), 461–468.
- Loftus, R. W., Yeager, M. P., Clark, J. A., Brown, J. R., Abdu, W. A., Sengupta, D. K., et al. (2010). Intraoperative ketamine reduces perioperative opiate consumption in opiate-dependent patients with chronic back pain undergoing back surgery. *Anesthesiology*, 113(3), 639–646.
- Lurie, J. D., Doman, D. M., Spratt, K. F., Tosteson, A. N. A., & Weinstein, J. N. (2009). Magnetic resonance imaging interpretation in patients with symptomatic lumbar spine disk herniations: Comparison of clinician and radiologist readings. *Spine*, 34(7), 701–705.
- Maeda, T., Buchowski, J. M., Kim, Y. J., Mishiro, T., & Bridwell, K. H. (2009). Long adult spinal deformity fusion to the sacrum using rhBMP-2 versus autogenous iliac crest bone graft. *Spine*, 34(20), 2205–2212.
- Manchikanti, L., Glaser, S. E., Wolfer, L., Derby, R., & Cohen, S. P. (2009). Systematic review of lumbar diskography as a diagnostic test for chronic low back pain. *Pain Physician*, 12(3), 541–559.
- Mannion, A. F., Denzler, R., Dvorak, J., Muntener, M., & Grob, D. (2009). A randomised controlled trial of post-operative rehabilitation after surgical decompression of the lumbar spine. *European Spine Journal*, 16(8), 1101–1117.
- Mastrorardi, L., Pappagallo, M., Puzzilli, F., & Tatta, C. (2002). Efficacy of the morphine-Adcon-L compound in the management of postoperative pain after lumbar microdiscectomy. *Neurosurgery*, 50(3), 518–524.
- Matsumoto, M., Okuda, E., Ichihara, E., Watanabe, K., Chiba, K., Toyama, Y., et al. (2010). Age-related changes of thoracic and cervical intervertebral disks in asymptomatic subjects. *Spine*, 34(14), 1359–1364.
- McGill, S., & Karpowicz, A. (2009). Exercises for spinal stabilization: Motion/motor patterns, stability progressions, and clinical technique. *Archives of Physical Medicine and Rehabilitation*, 90(1), 118–126.
- Melnyk, B. M. (2004). Evidence digest: Levels of evidence. *Worldviews on Evidence-Based Nursing*, 1, 142–145.
- McGregor, A. H., Probyn, K., Cro, S., Doré, J. C., Burton, A. K., Balagué, F., Fairbank, J. (2013). Rehabilitation following surgery for lumbar spinal stenosis. *Cochrane Database Systematic Review*. 12:CD009644. doi10.1002/14651858.CD009644.pub2.
- Middleton, K., & Fish, D. E. (2009). Lumbar spondylosis: Clinical presentation and treatment approaches. *Current Reviews in Musculoskeletal Medicine*, 2(2), 94–104.
- Mirzai, H., Tekin, I., & Alincak, H. (2002). Perioperative use of corticosteroid and bupivacaine combination in lumbar disk surgery: A randomized controlled trial. *Spine*, 27(4), 343–346.
- Monticone, E., & Giovanazzi, E. (2008). Usefulness of cognitive behavioural and rehabilitative approach to enhance long lasting benefit after lumbar spinal stenosis and degenerative spondylolisthesis surgery: A case report. *European Journal of Physical and Rehabilitative Medicine*, 44(4), 467–471.
- Moschetti, W., Pearson, A., & Abdu, W. (2009). Treatment of lumbar disk herniation: An evidence-based review. *Seminars in Spine Surgery*, 21(4), 223–229.
- Negrini, S., Minozzi, S., Bettany-Saltikov, J., Zaina, F., Chockalingam, N., Graiva, T. B., et al. (2010). Braces for idiopathic scoliosis in adolescents. *Cochrane Database of Systematic Reviews*, 1, CD006850.
- North American Spine Society. (2007). *Antibiotic prophylaxis in spine surgery*. Burr Ridge, IL: Author.
- North American Spine Society. (2009). *Antithrombotic therapies in spine surgery*. Burr Ridge, IL: Author.
- Oguzhan, N., Gunday, I., & Turan, A. (2008). Effect of magnesium sulfate infusion on sevoflurane consumption, hemodynamics, and perioperative opioid consumption in lumbar disk surgery. *Opioid Management*, 4(2), 105–110.
- Old, J. L., & Calvert, M. (2004). Vertebral compression fractures in the elderly. *American Family Physician*, 69(1), 111–116.
- Olivero, W. C., Wang, H., Hanigan, W. C., Henderson, J. P., Tracy, P. T., Elwood, P. W., et al. (2009). Cauda equina syndrome (CES) from lumbar disk herniations. *Journal of Spinal Disorders & Techniques*, 22(3), 202–206.
- Ostelo, R. W., Costa, L. O., Maher, C. G., de Vet, H. C., & van Tulder, M. W. (2008). Rehabilitation after lumbar disk surgery. *Cochrane Database of Systematic Reviews*, 4, CD003007.
- Ostelo, R. W., Costa, L. O., Maher, C. G., de Vet, H. C., & van Tulder, M. W. (2009). Rehabilitation after lumbar disk surgery: An update Cochrane review. *Spine*, 34(17), 1839–1848.
- Paasilta, P., Lohiniva, J., Goring, H. H. H., Perala, M., Raina, S. S., Karppinen, J., et al. (2001). Identification of a novel common genetic risk factor for lumbar disk disease. *Journal of the American Medical Association*, 285(14), 1843–1849.
- Pandey, C. K., Navkar, D. V., Giri, P. J., Raza, M., Behari, S., Singh, R. B., et al. (2005). Evaluation of the optimal preemptive dose of gabapentin for postoperative pain relief after lumbar discectomy: A randomized, double-blind, placebo-controlled study. *Journal of Neurosurgical Anesthesiology*, 17(2), 65–68.
- Papavero, L., Thiel, M., Fritzsche, E., Kunze, C., Westphal, M., & Kothe, R. (2009). Lumbar spinal stenosis: Prognostic factors for bilateral microsurgical decompression using a unilateral approach. *Neurosurgery*, 65(Suppl. 6), 182–187.
- Park, S., Moon, S., Park, M., Oh, K., & Lee, H. (2005). The effects of ketorolac injected via patient controlled analgesia postoperatively on spinal fusion. *Yonsei Medical Journal*, 46(2), 245–251.
- Patel, A. A., Dailey, A., Brodke, D. S., Daubs, M., Harrop, J., Whang, P. G., et al. (2009). Thoracolumbar spine trauma classification: The Thoracolumbar Injury Classification and Severity Score system and case examples. *Journal of Neurosurgical Spine*, 10(3), 201–206.
- Pearson, A., Blood, E., Lurie, J., Abdu, W., Sengupta, D., Frymoyer, J., et al. (2011). Predominant leg pain is associated with better surgical outcomes in degenerative spondylolisthesis and spinal stenosis: Results from the spine patient outcomes research trial (SPORT). *Spine*, 36(3), 219–229.

- Pekmezci, M., Berven, S. H., Hu, S. S., & Deviren, V. (2009). The factors that play a role in the decision-making process of adult deformity patients. *Spine*, 34(8), 813–817.
- Pfirmsmann, C. W., Metzendorf, A., Zanetti, M., Hodler, J., & Boos, N. (2001). Magnetic resonance classification of lumbar intervertebral disk degeneration. *Spine*, 26(17), 1873–1878.
- Ploumis, A., Liu, H., Mehbod, A. A., Transfeldt, E. E., & Winter, R. B. (2009). A correlation of radiographic and functional measurements in adult degenerative scoliosis. *Spine*, 34(15), 1581–1584.
- Pull ter Gunne, A. F., van Laarhove, C. M., & Cohen, D. B. (2010). Incidence of surgical site infection following adult spinal deformity surgery: An analysis of patient risk. *European Spine Journal*, 19(6), 982–988.
- Qureshi, A., & Sell, P. (2007). Cauda equina syndrome treated by surgical decompression: The influence of timing on surgical outcome. *European Spine Journal*, 16(12), 2143–2151.
- Radhakrishnan, M., Bithal, P. K., & Chaturvedi, A. (2005). Effect of preemptive gabapentin on postoperative pain relief and morphine consumption following lumbar laminectomy and discectomy: A randomized, double-blinded, placebo-controlled study. *Journal of Neurosurgical Anesthesiology*, 17(3), 125–128.
- Reuben, S. S., Buvanendran, A., Kroin, J. S., & Raghunathan, K. (2006). The analgesic efficacy of celecoxib, pregabalin, and their combination for spinal fusion surgery. *Anesthesia & Analgesia*, 103(5), 1271–1277.
- Robinson, Y., Heyde, C. E., Försth, P. & Olerud, C. (2011). Kyphoplasty in osteoporotic vertebral compression fractures: Guidelines and technical considerations. *Journal of Orthopaedic Surgery and Research*, 6(43). Accessed at www.josr-online.com/content/6/1/43
- Roussouly, P., & Nnadi, C. (2010). Sagittal plane deformity: An overview of interpretation and management. *European Spine Journal*, 19(11), 1824–1836.
- Sang-Bong, K., & Sang-Wook, L. (2011). Prevalence of spondylolysis and its relationship with low back pain in selected population. *Clinics in Orthopedic Surgery*, 3, 34–38.
- Schizas, C., Kulik, G., & Kosmopoulos, V. (2010). Disk degeneration: Current surgical options. *European Cells and Materials*, 20, 306–315.
- Schuster, J. M., Rehtine, G., Norvell, D. C., & Dettori, J. R. (2010). The influence of perioperative risk factors and therapeutic interventions on infection rates after spine surgery: A systematic review. *Spine*, 35(Suppl. 9), S125–S137.
- Sekar, C., Rajasekaran, S., Kannan, R., Reddy, S., Shetty, T. A., & Pithwa, Y. K. (2004). Preemptive analgesia for postoperative pain relief in lumbosacral spine surgeries: A randomized controlled trial. *Spine Journal*, 4(3), 261–264.
- Shaffer, W. O., Baisden, J., Fernand, R., & Matz, P. (2013). North American Spine Society Evidence-Based Clinical Guidelines for Multidisciplinary Spine Care: Antibiotic prophylaxis in spine surgery. Burr Ridge, IL: North American Spine Society. Accessed at: www.spine.org/Documents/ResearchClinicalCare/Guidelines/AntibioticProphylaxis.pdf
- Shankar, H., Scarlett, J., & Abram, S. (2009). Anatomy and pathophysiology of intervertebral disk disease. *Techniques in Regional Anesthesia and Pain Management*, 13(2), 67–75.
- Siebert, E., Pruss, H., Klingebiel, R., Failli, V., Einhaupl, K. M., & Schwab, J. M. (2009). Lumbar spinal stenosis: Syndrome, diagnostics and treatment. *Nature Reviews Neurology*, 5(7), 392–403.
- Silva, F. E., & Lenke, L. G. (2010). Adult degenerative scoliosis: Evaluation and management. *Neurosurgery Focus*, 28(3), 1–10.
- Singh, K., Masuda, K., Thonar, E. J., An, H. S., & Cs-Szabo, G. (2009). Age-related changes in the extracellular matrix of nucleus pulposus and annulus fibrosus of human intervertebral disk. *Spine*, 34(1), 10–16.
- Singh, K., & Phillips, F. M. (2005). The biomechanics and biology of the spinal degenerative cascade. *Seminars in Spine Surgery*, 17(3), 128–137.
- Sinha, P., Sedgley, L., Sutcliffe, D., & Timothy, J. (2010). Surgery for vertebral compression fractures: Understanding vertebroplasty and kyphoplasty. *British Journal of Neuroscience Nursing*, 6(8), 377–382.
- Smith, J. S., Sansur, C. A., Donaldson, W. F., Perra, J. H., Mudiyan, R., Choma, T. J., et al. (2011). Short-term morbidity and mortality associated with correction of thoracolumbar fixed sagittal plane deformity: A report from the scoliosis research society morbidity and mortality committee. *Spine*, 36(12), 958–964.
- Smith, J. S., Shaffrey, C. I., Berven, S., Glassman, S., Hamil, C., Horton, W., et al. (2009a). Improvement of back pain with operative and nonoperative treatment in adults with scoliosis. *Neurosurgery*, 65(1), 86–94.
- Smith, J. S., Shaffrey, C. I., Berven, S., Glassman, S., Hamil, C., Horton, W., et al. (2009b). Operative versus nonoperative treatment of leg pain in adults with scoliosis. *Spine*, 34(16), 1693–1698.
- Starkweather, A. (2006). Posterior lumbar interbody fusion: An old concept with new technique. *Journal of Neuroscience Nursing*, 38(1), 13–21.
- Story, S. K., & Chamberlain, R. S. (2009). A comprehensive review of evidence-based strategies to prevent and treat postoperative ileus. *Digestive Surgery*, 26(7), 265–275.
- Thompson, J. P., Pearce, R. H., Schechter, M. T., Adams, M. E., Tsang, I. K., & Bishop, P. B. (1990). Preliminary evaluation of a scheme for grading the gross morphology of the human intervertebral disk. *Spine*, 15(5), 411–415.
- Tormenti, M. J., Kostov, D. B., Gardner, P. A., Kanter, A. S., Spiro, R. M., & Okonkwo, D. O. (2010). Intraoperative computed tomography image-guided navigation for posterior thoracolumbar spinal instrumentation in spinal deformity surgery. *Neurosurgery Focus*, 28(3), E11.
- Trobisch, P., Suess, O., & Schwab, F. (2010). Idiopathic scoliosis. *Deutsches Arzteblatt International*, 107(49), 875–884.
- Truumees, E., & Brebach, G. T. (2004). Interbody fusion. In J. W. Frymoyer & S. W. Weisel (Eds.), *The Adult and pediatric spine* (3rd ed., pp. 1133–1152). Philadelphia: Lippincott Williams & Wilkins.
- Vaccaro, A. R., Lim, M. R., Hurlbert, R. J., Lehman, R. A., Harrop, J., Fisher, D., et al. (2006). Surgical decision making for unstable thoracolumbar spine injuries: Results of a consensus panel review by the Spine Trauma Study Group. *Journal of Spinal Disorders and Techniques*, 19(1), 1–10.
- van Duijvenbode, I., Jellema, P., van Poppel, M., & van Tulder, M. W. (2008). Lumbar supports for prevention and treatment of low back pain. *Cochrane Database of Systematic Reviews*, 2, CD001823.
- Watters, W. C., Bono, C. M., Gilbert, T. J., Kreiner, D. S., Mazanec, D. J., Shaffer, W. O., et al. (2009). An evidence-based clinical guideline for the diagnosis and treatment of degenerative lumbar spondylolisthesis. *Spine Journal*, 9(7), 609–614.
- Weinstein, J. N., Lurie, J. D., Tosteson, T. D., Tosteson, A. N. A., Blood, E., Abdu, W. A., et al. (2008a). Surgical versus non-operative treatment for lumbar disk herniation: Four-year results for the Spine Patient Outcomes Research Trial (SPORT). *Spine*, 33(25), 2789–2800.
- Weinstein, J. N., Tosteson, T. D., Lurie, J. D., Tosteson, A. N. A., Blood, E., Hanscom, B., et al. (2008b). Surgical versus nonsurgical therapy for lumbar spinal stenosis. *New England Journal of Medicine*, 358(8), 794–810.
- Weinstein, S. L., & Ponsetti, I. V. (1983). Curve progression in idiopathic scoliosis. *Journal of Bone Surgery of America*, 65(4), 447–455.
- Whitesides, T., Hanley, E. N., & Fellrath, R. F. (2004). Controversies: Smoking abstinence: Is it necessary before spinal fusion? *Spine*, 19(17), 2012–2014.
- Wood, K., Butterman, G., Mehbod, A., Garvey, T., Jhanjee, R., & Sechriest, V. (2003). Operative compared with nonoperative treatment of a thoracolumbar burst fracture without neurological deficit. *The Journal of Bone and Joint Surgery*, 85-A(5), 773–781.

- Yadla, S., Maltenfor, M. G., Ratliff, J. K., & Harrop, J. S. (2010). Adult scoliosis surgery outcomes: A systematic review. *Neurosurgery Focus*, 28(3), E3.
- Yagi, M., King, A. B., & Boachie-Adjei, O. (2011). Characterization of osteopenia/osteoporosis in adult scoliosis. Does bone density affect surgical outcome? *Spine*, 36(20), 1652–1657.
- Yang, C., Bi, Z., Fu, C., & Zhang, Z. (2010). A modified decompression surgery for thoracic myelopathy caused by ossification of posterior longitudinal ligament: A case report and literature review. *Spine*, 35(13), E609–E613.
- Yorukoglu, D., Ates, Y., Temiz, H., Yamali, H., & Kecik, Y. (2005). Comparison of low-dose intrathecal and epidural morphine and bupivacaine infiltration for postoperative pain control after surgery for lumbar disk disease. *Journal of Neurosurgical Anesthesiology*, 17(3), 129–133.
- Yoshimoto, H., Nagashima, K., Sato, S., Hyakumachi, T., Yanagibashi, Y., & Masuda, T. (2005). A prospective evaluation of anesthesia for posterior lumbar spine fusion: The effectiveness of preoperative epidural anesthesia with morphine. *Spine*, 30(8), 863–869.
- Yukawa, Y., Kato, F., Ito, K., Terashima, T., & Horie, Y. (2005). A prospective randomized study of preemptive analgesia for postoperative pain in the patients undergoing posterior lumbar interbody fusion: Continuous subcutaneous morphine, continuous epidural morphine and diclofenac sodium. *Spine*, 30(21), 2357–2361.
- Ziegeler, S., Fritsch, E., Bauer, C., Mencke, T., Muller, B. I., Soltesz, S., et al. (2008). Therapeutic effect of intrathecal morphine after posterior lumbar interbody fusion surgery: A prospective, double-blind, randomized study. *Spine*, 33(22), 2379–2386.
- Zimmerman, R. M., Mohamed, A. S., Skolasky, R. L., Robinson, M. D., & Kebaish, K. M. (2010). Functional outcomes and complications after primary spinal surgery for scoliosis in adults aged forty years or older. *Spine*, 35(20), 1861–1866.

Appendix A

Clinician, Patient, and Family Resources

American Spinal Injury Association

(<http://asia-spinalinjury.org>)

Provides patient and family resources and publications and resources for clinicians.

North American Spine Society (www.spine.org)

A professional society offering free patient and family information on spinal disorders and treatment options and guidelines for clinicians.

Spine Health (www.spine-health.com)

Delivers free resources for patients and families on spine conditions and surgical and nonsurgical treatment options.

Spine Universe (www.spineuniverse.com)

Provides information for clinicians, patients, and families. No-cost videos featuring back exercises and patient teaching resources are available.

