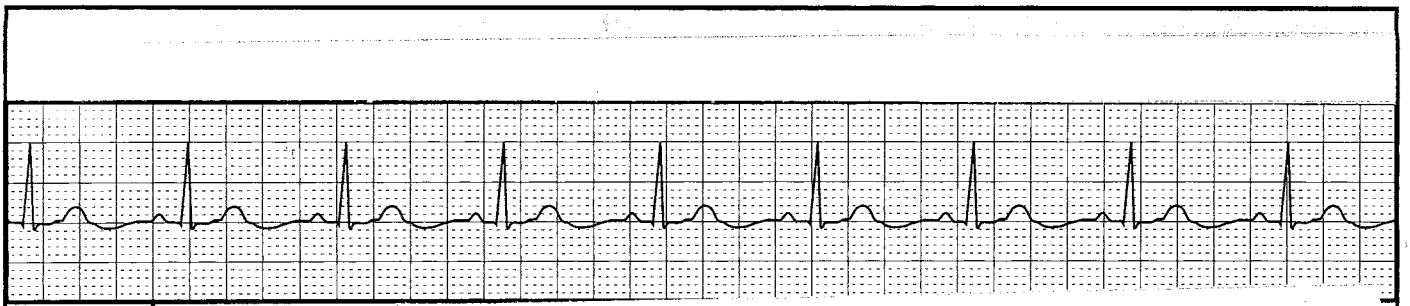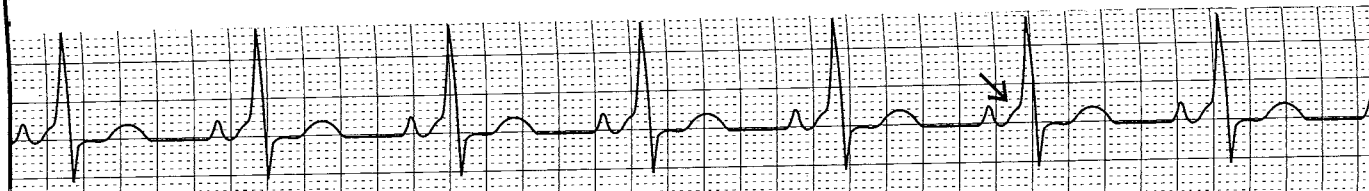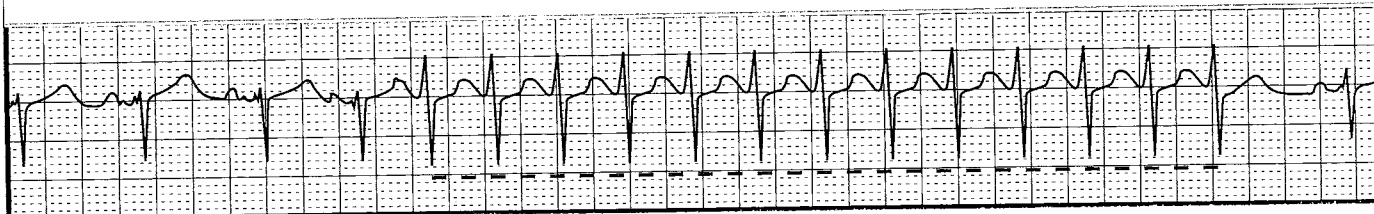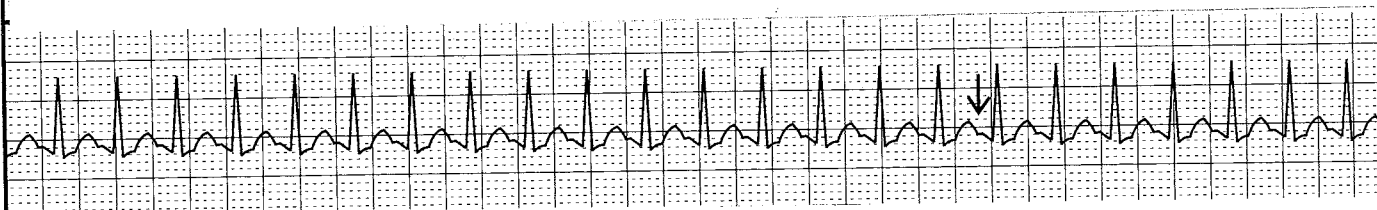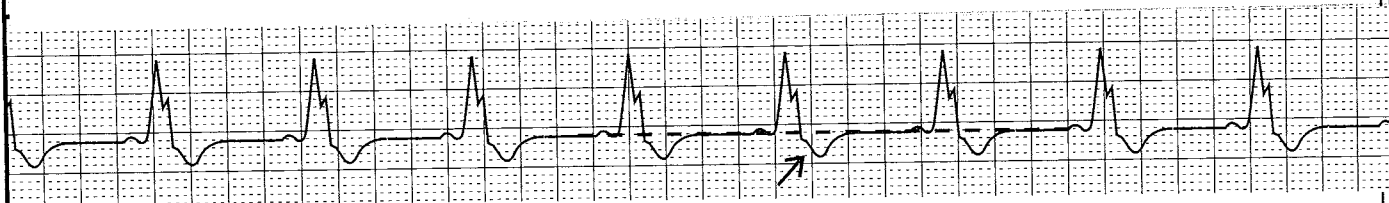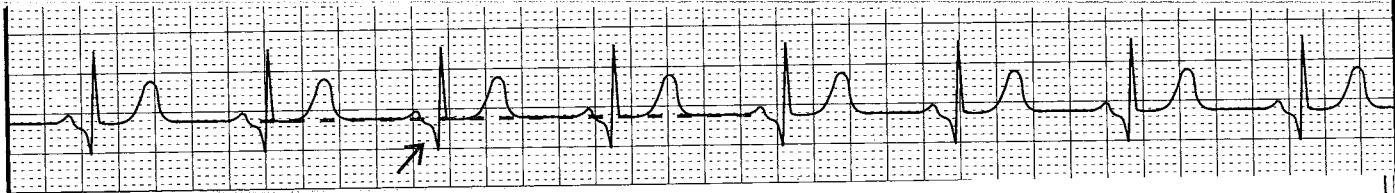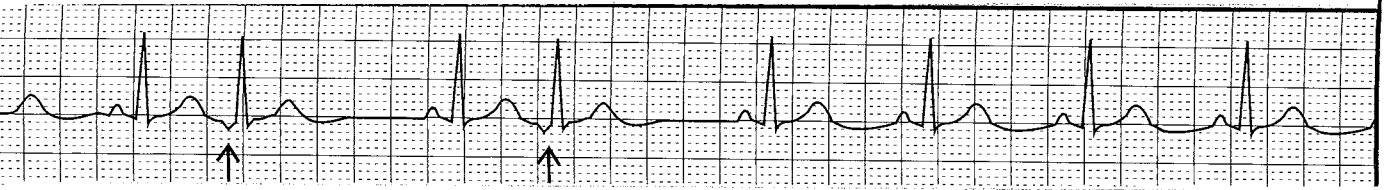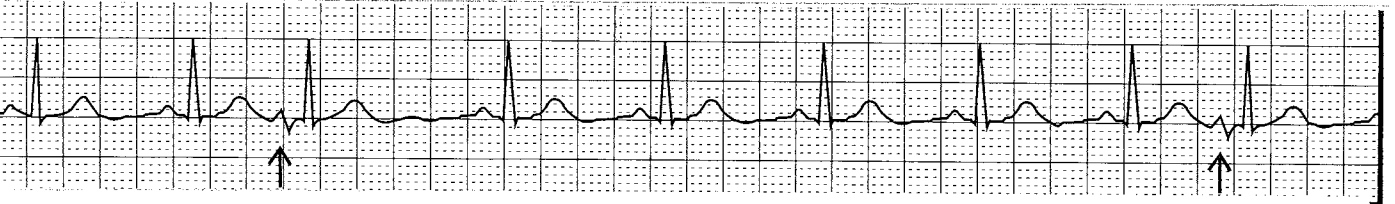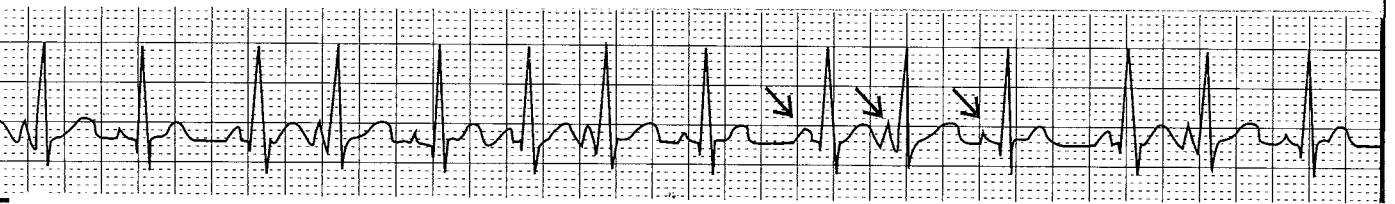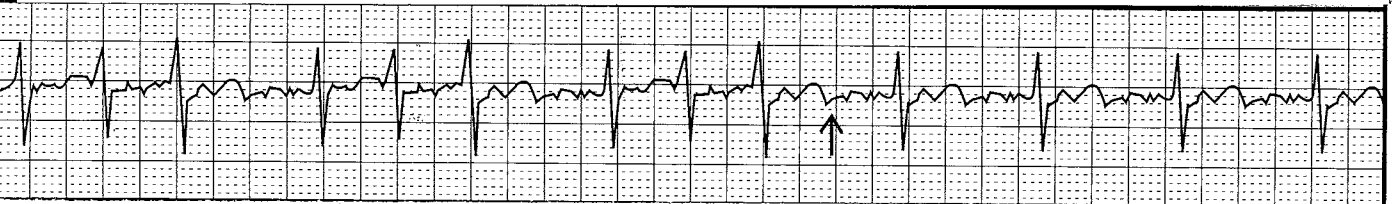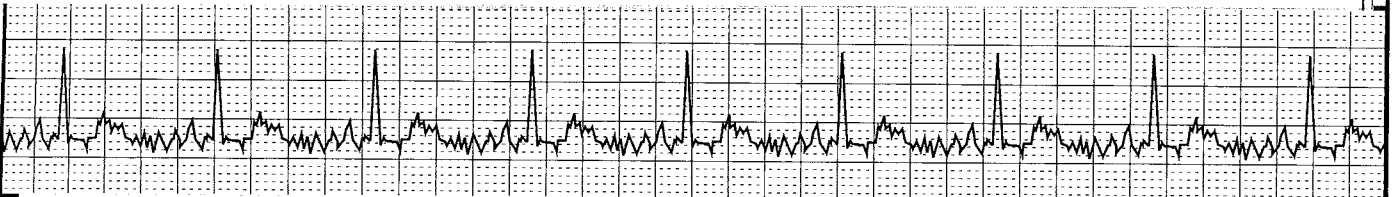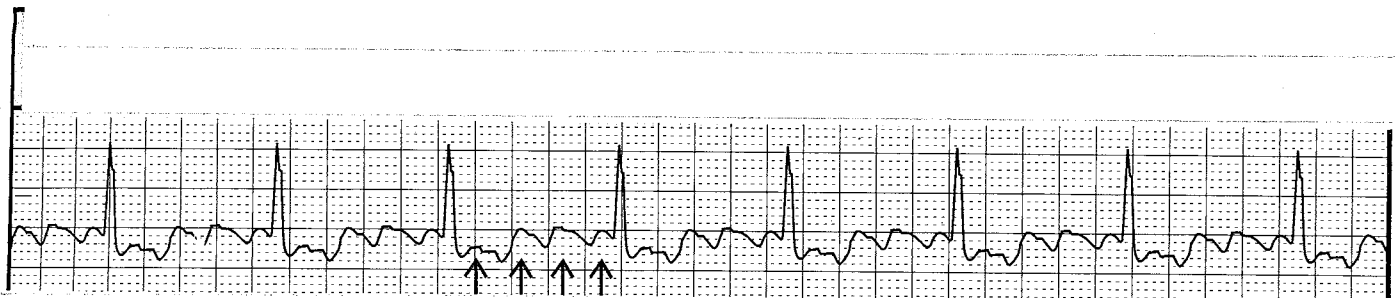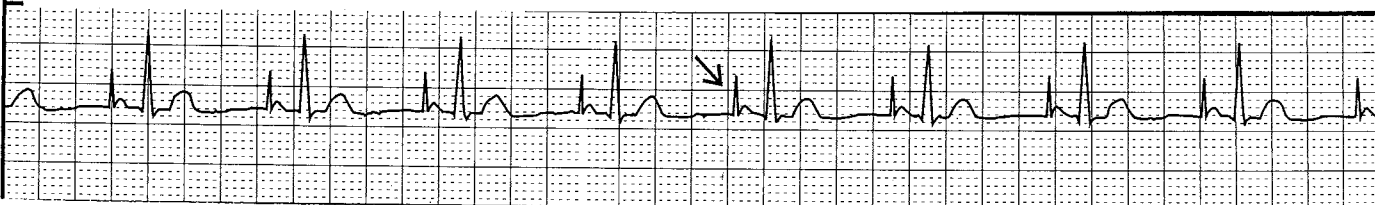
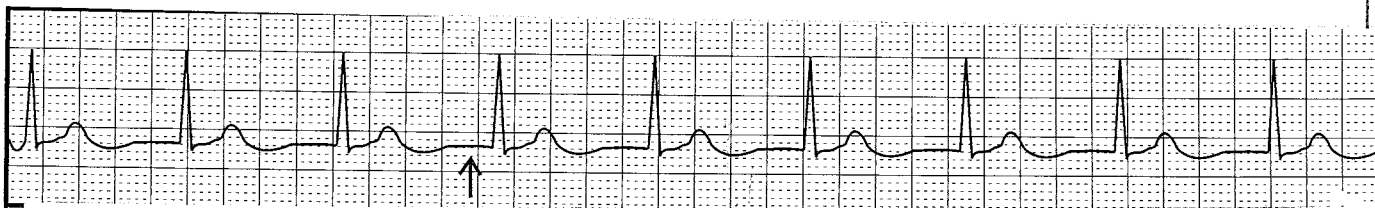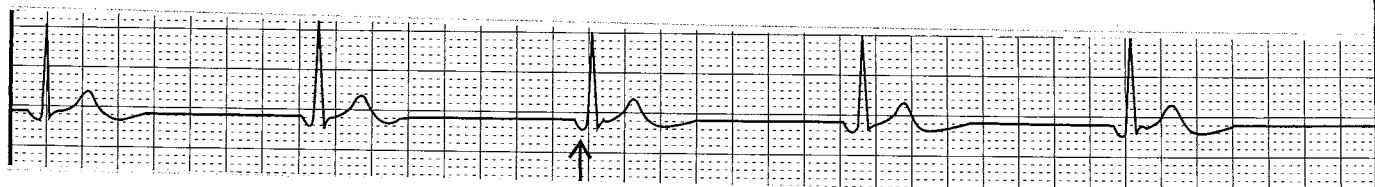
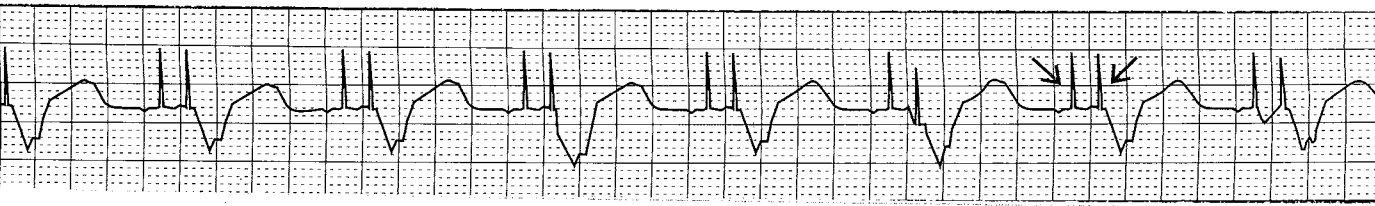
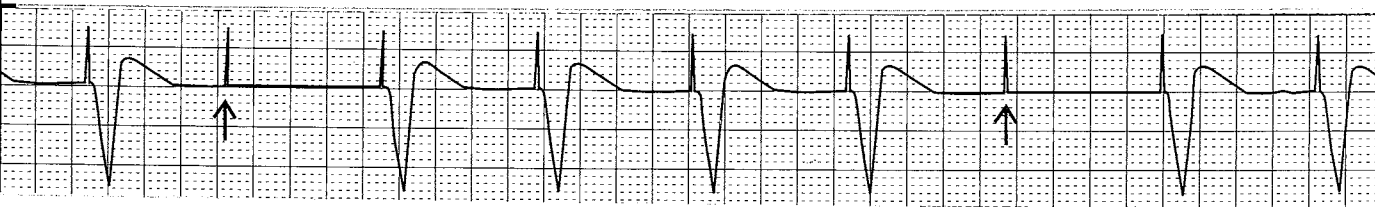
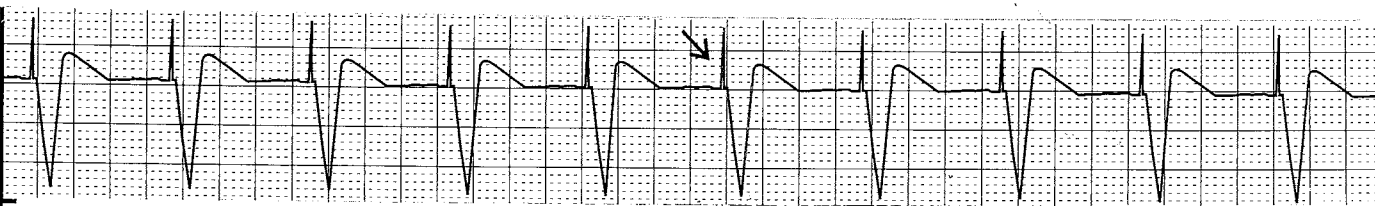


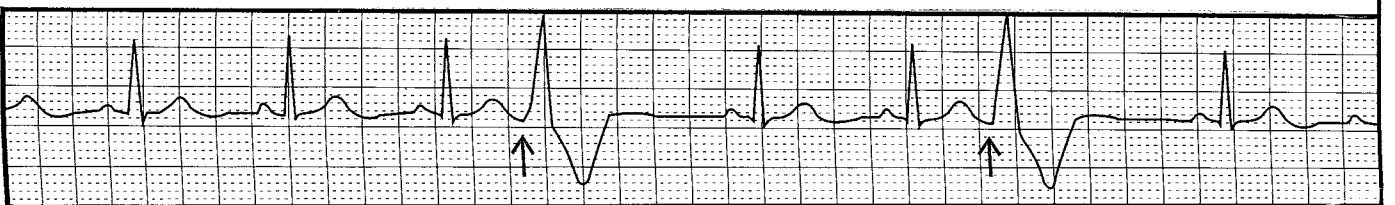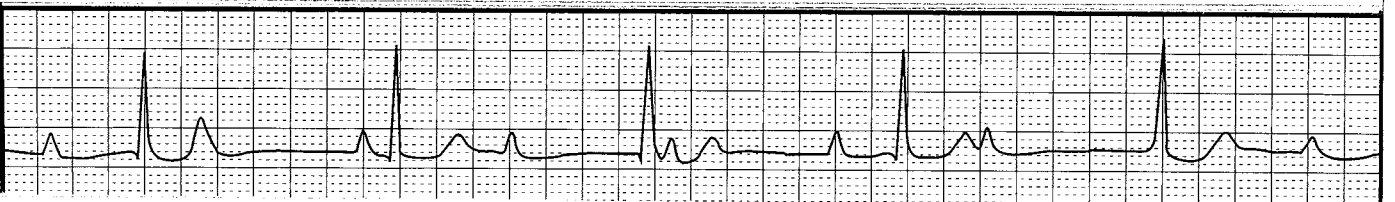
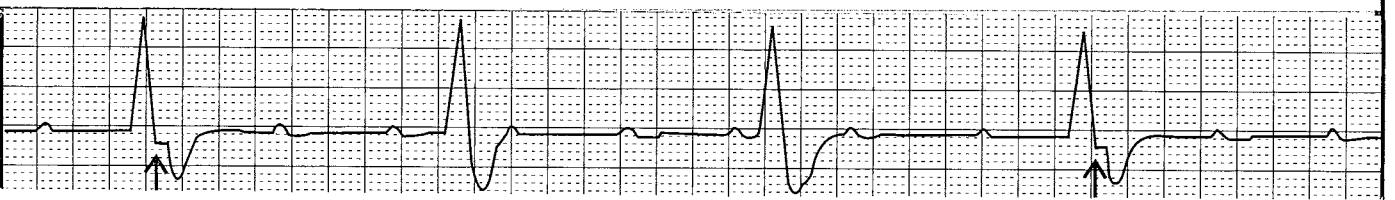
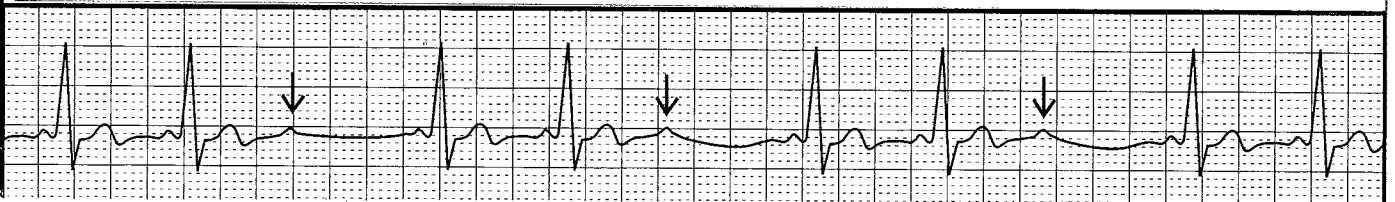
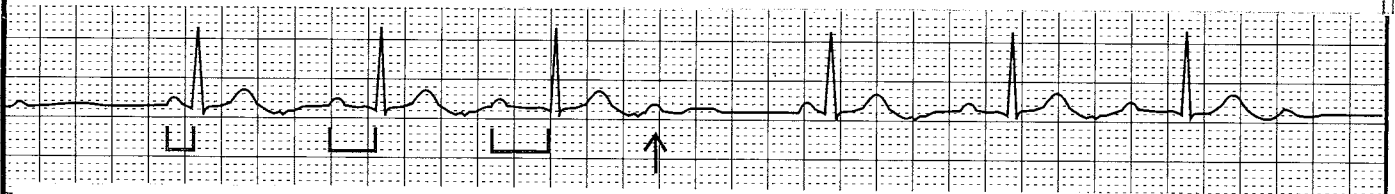
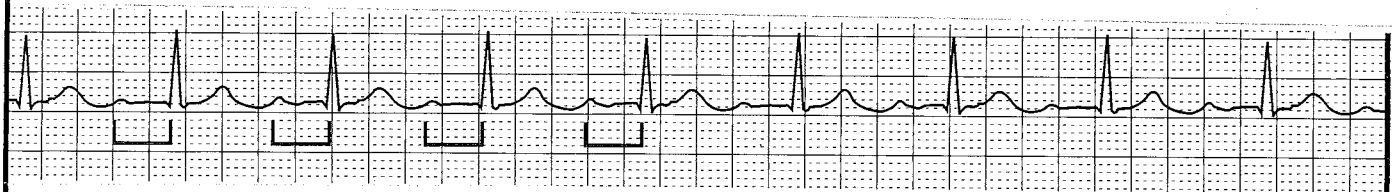
3



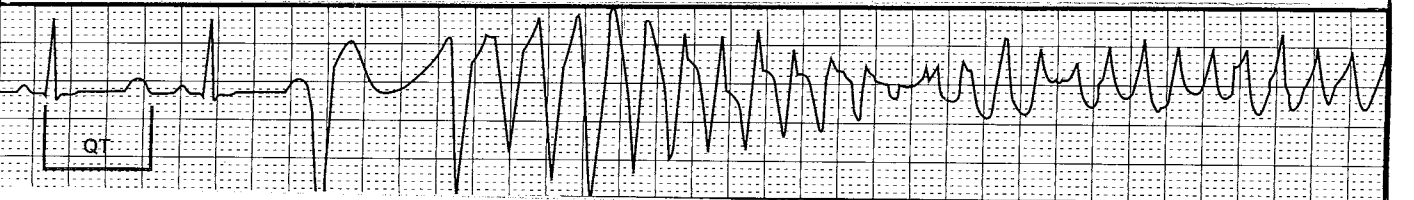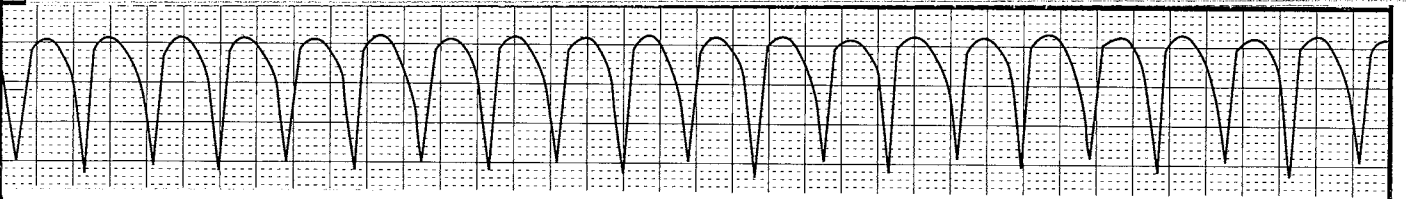
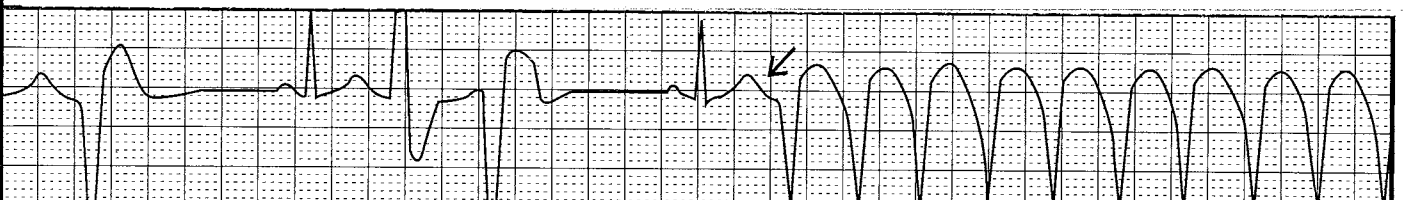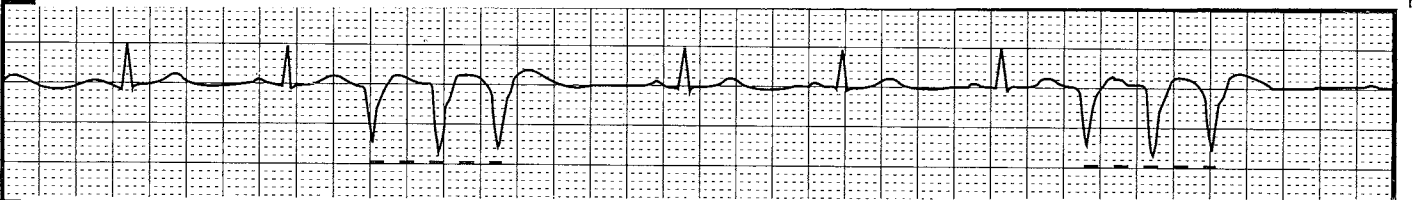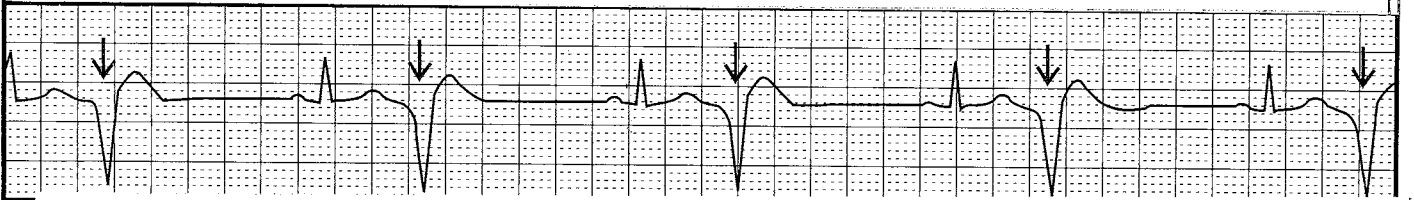
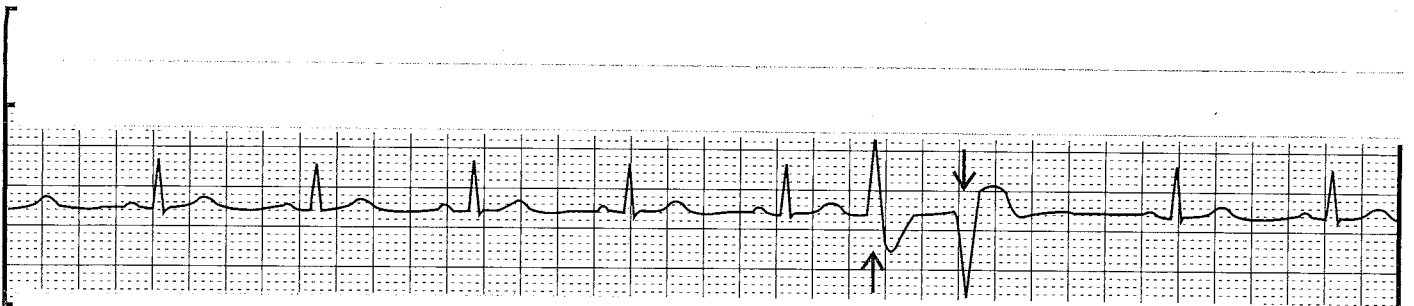
ED A-FIB



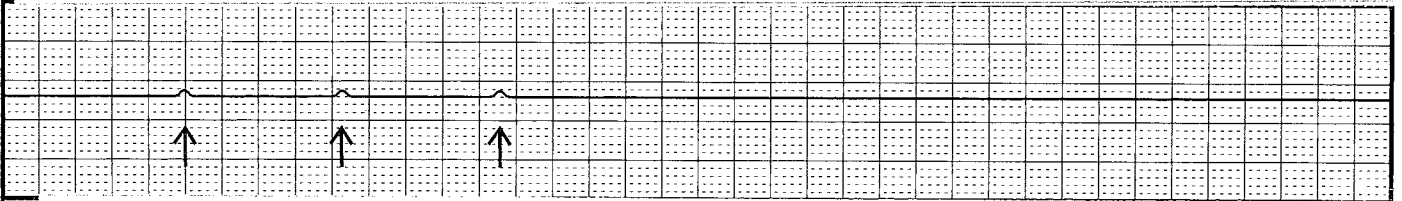
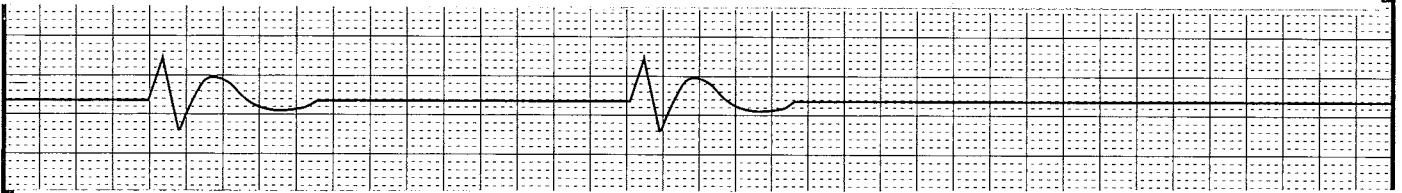
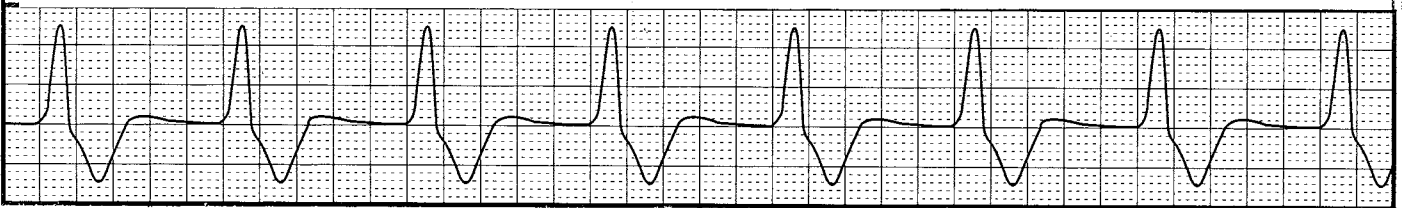
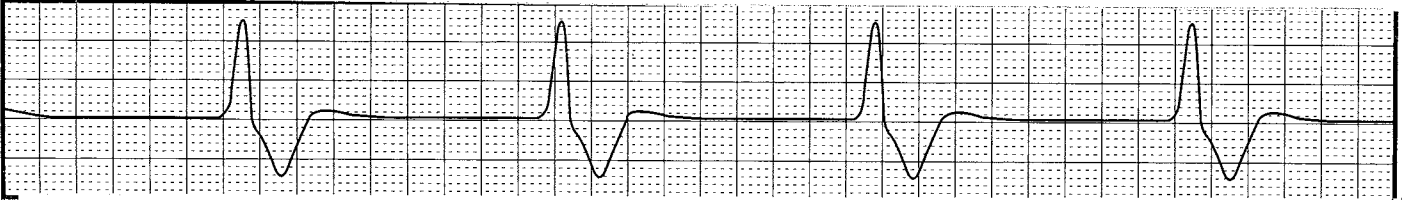
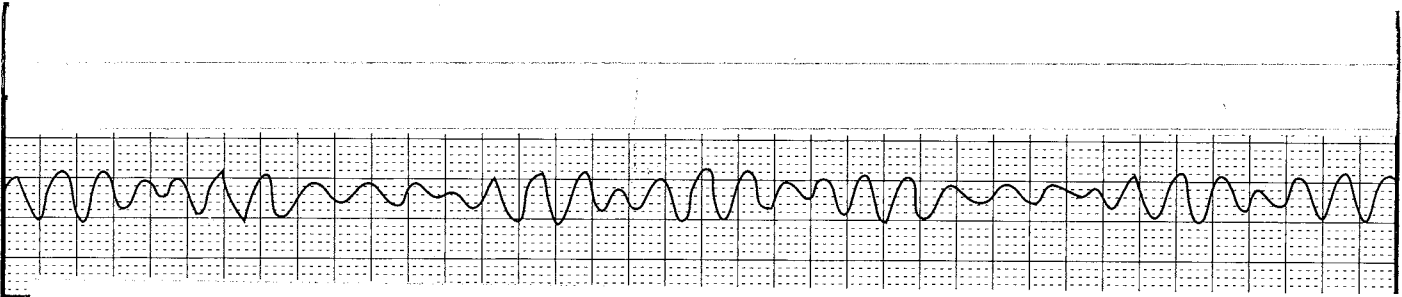
21



5



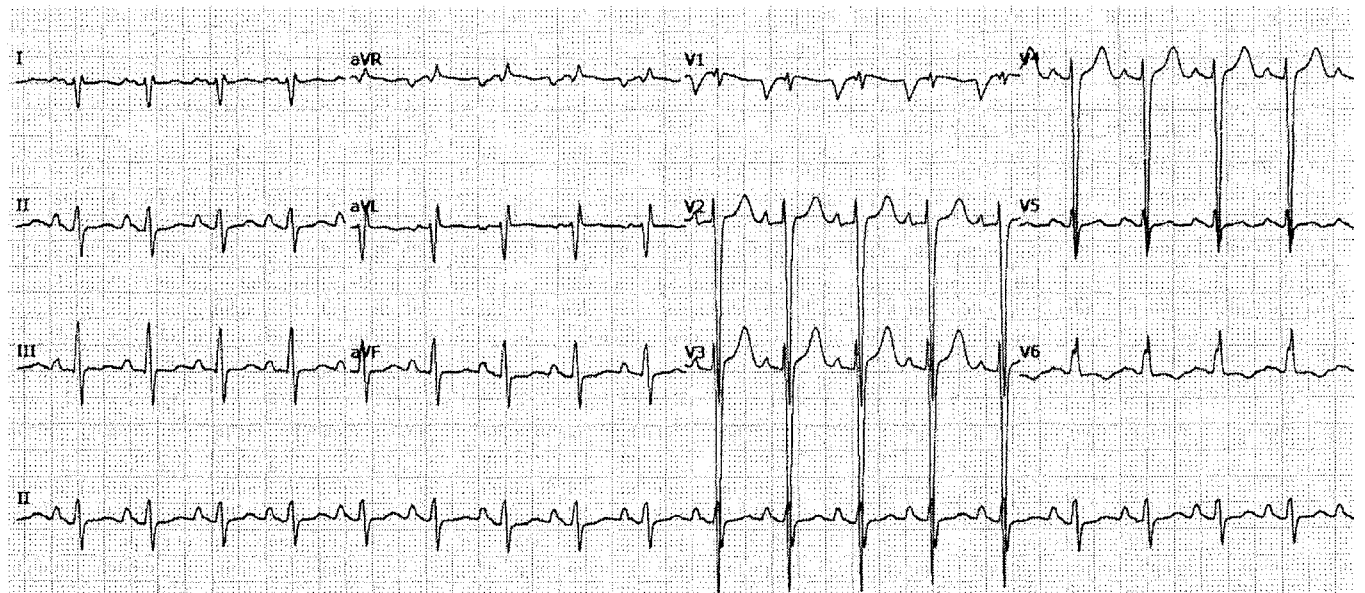
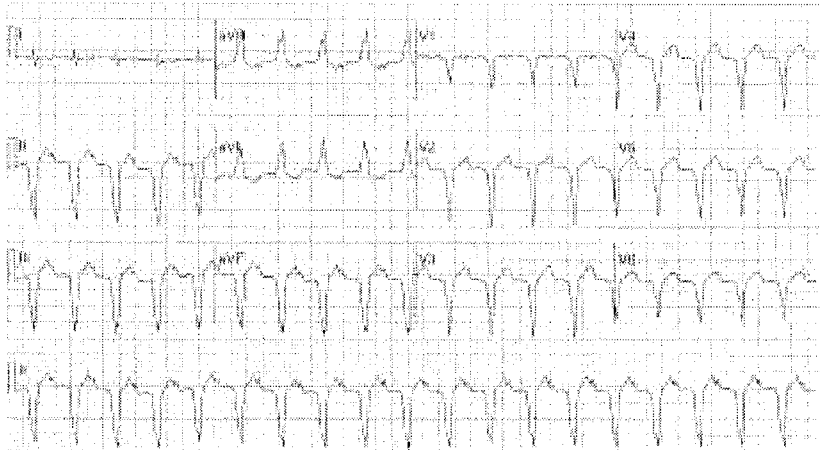
6



7

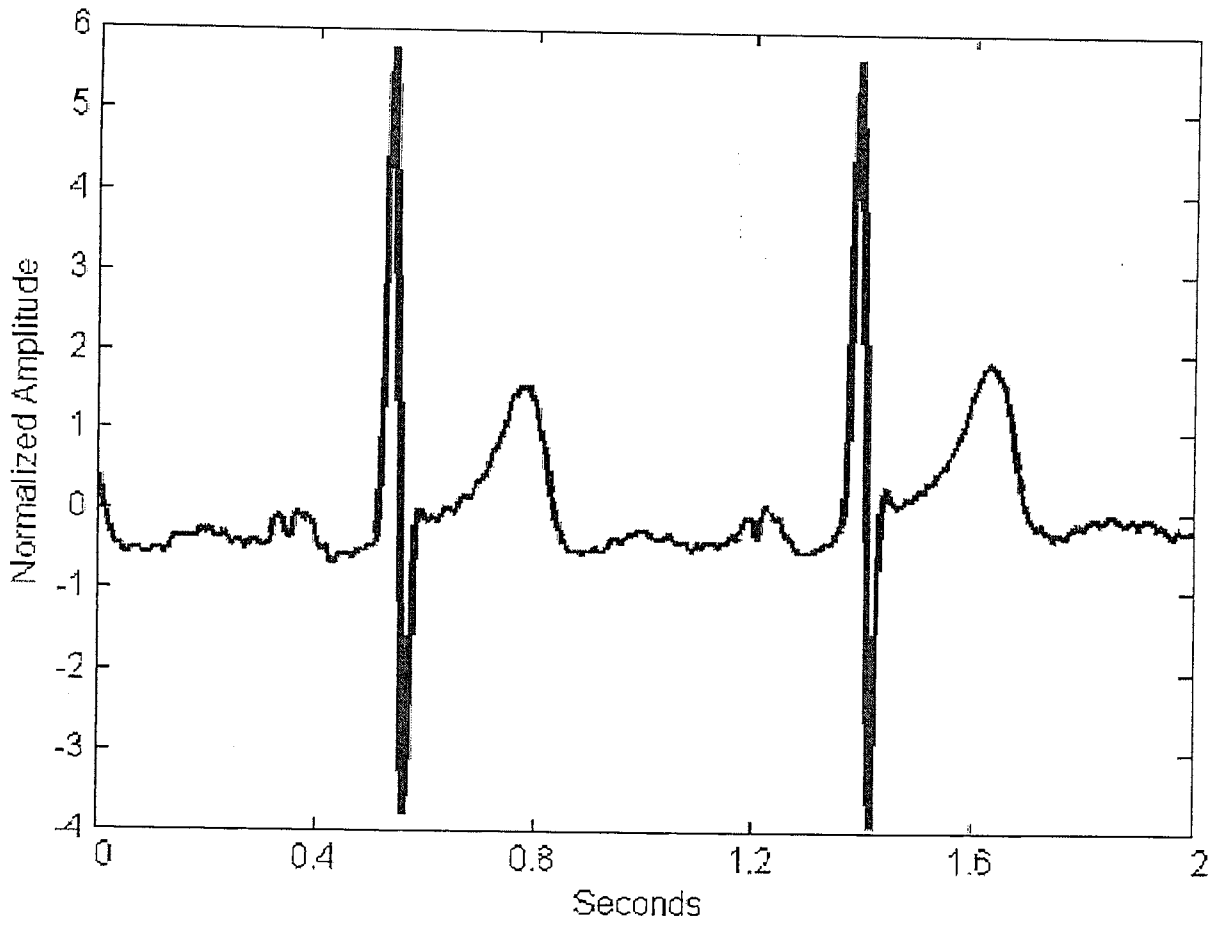
How does heart failure present on an ECG?

Among the ECG markers examined, higher resting heart rate, prolonged QRS duration, abnormal time to ID, left-axis deviation, abnormal QRS-T angle, left ventricular



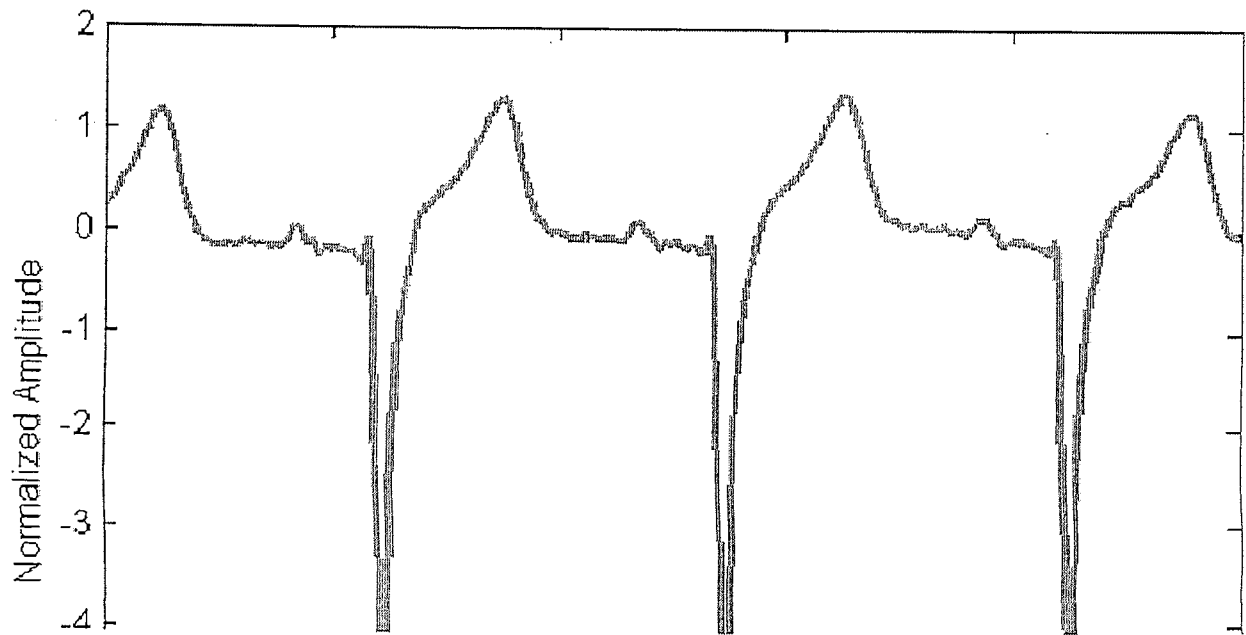


Normal



(a)

CHF



12-Lead 1

HR 63bpm

• Abnormal ECG \*\*Unconfirmed\*\*

16:49:11

• Normal sinus rhythm with sinus arrhythmia

PR 0.200s

• Left axis deviation

QT/QTc:

0.464s/0.474s

• Left bundle branch block

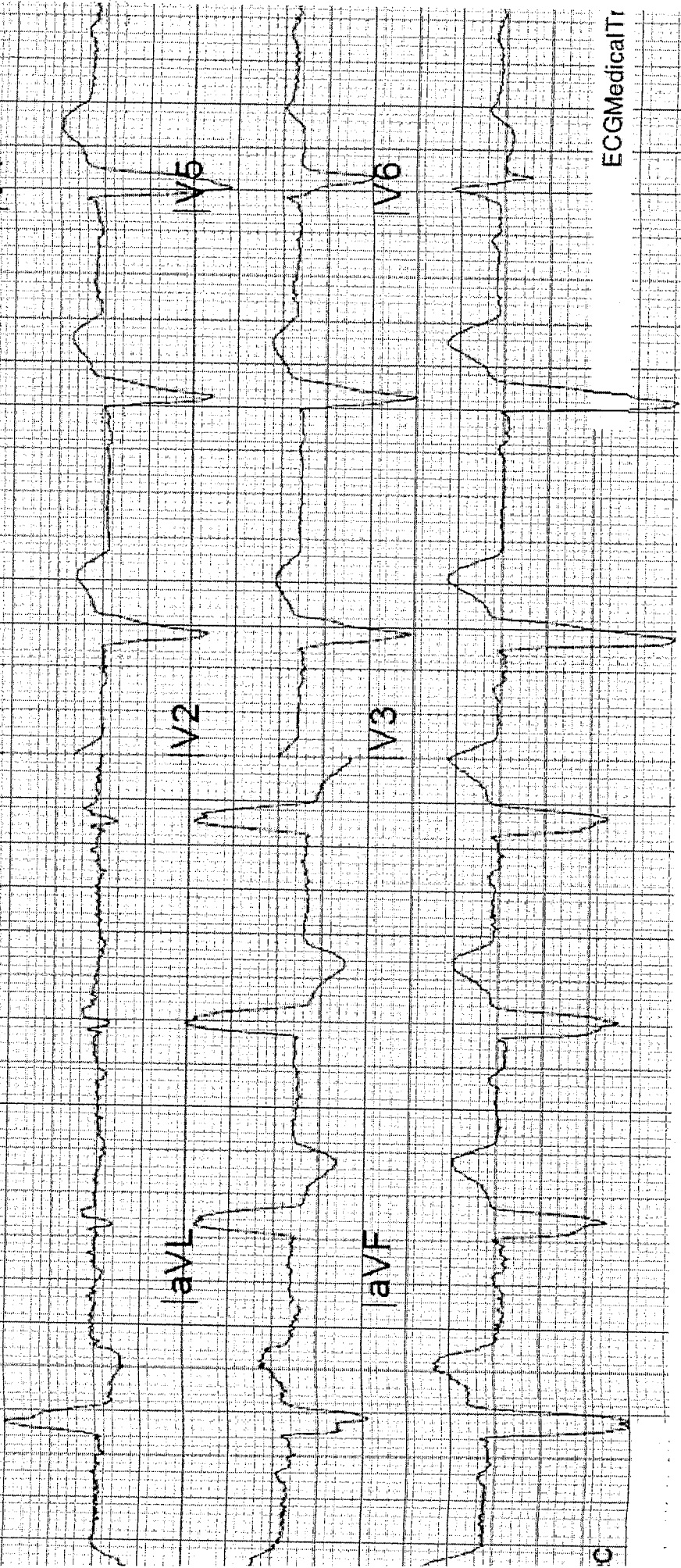
Sex: P-QRS-T Axes:

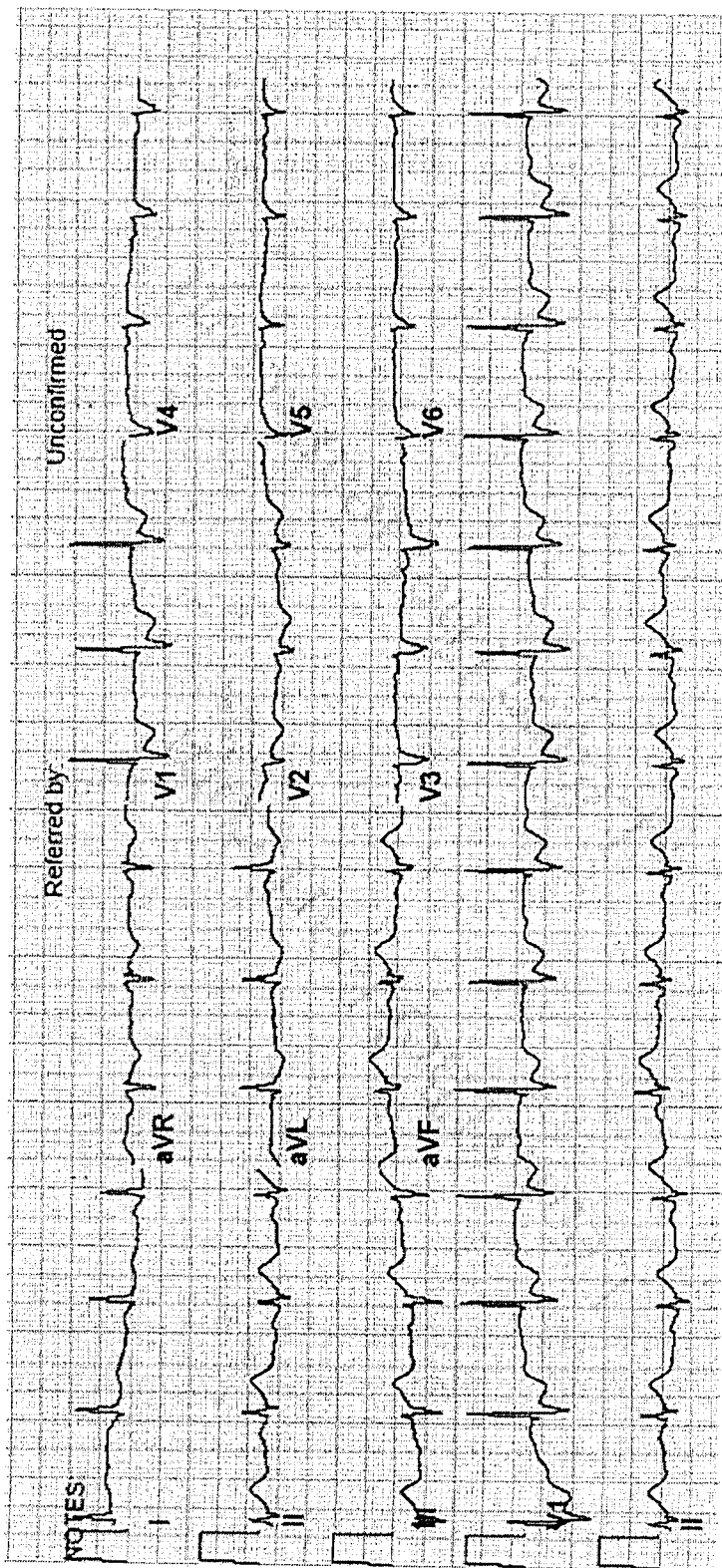
72° -56° 110°

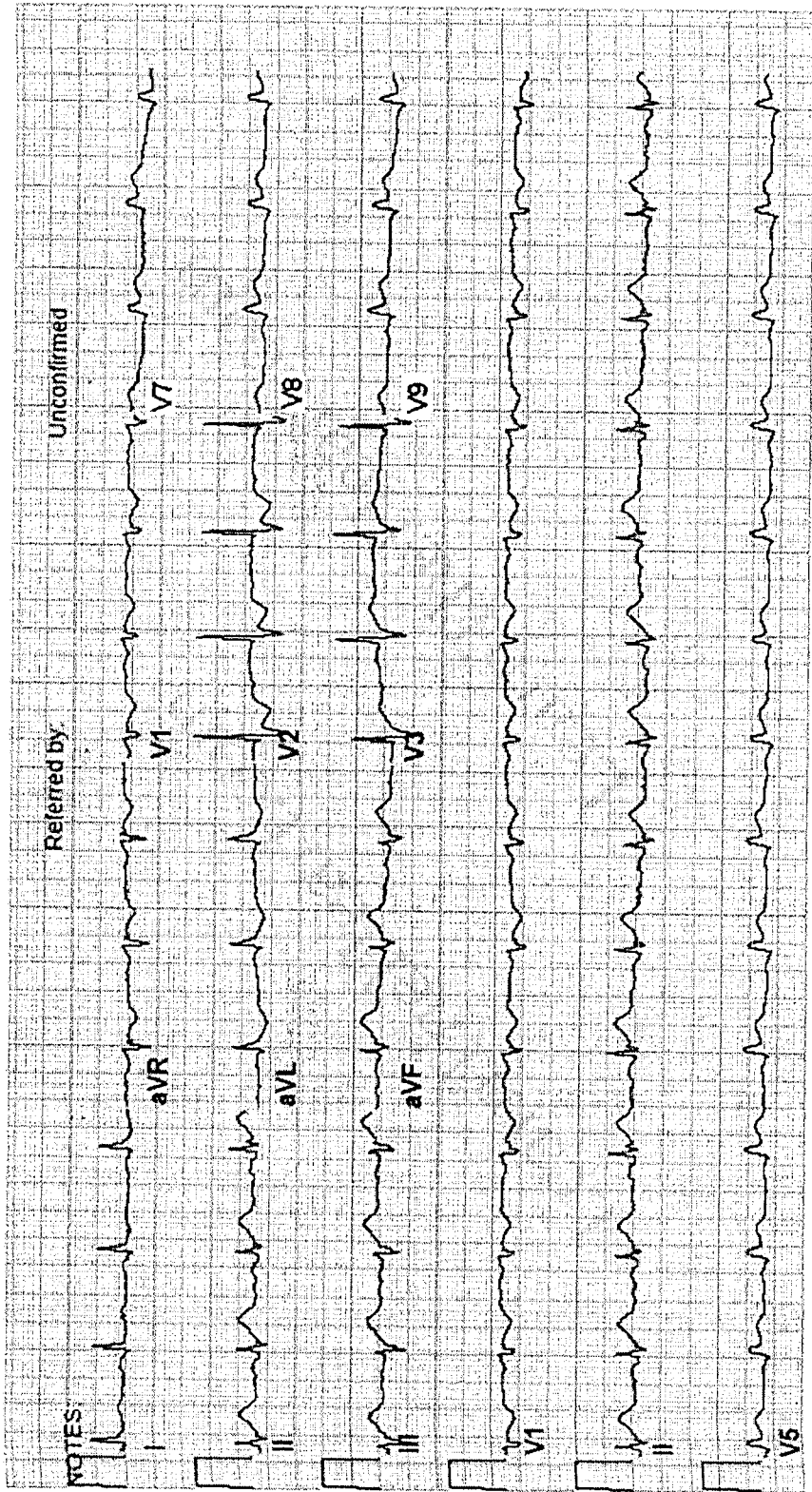
IaVR

V1

V4







EID: Unconfirmed EDT: ORDER: