

- Types of Movement and Skeletal System
- Joints and Disorders
- Quick Reference Table
- Common Mistakes and Misconceptions
- Glossary

Types of Movement and Skeletal System

Locomotion and Movement

Locomotion is the voluntary movement of an individual from one place to another. Examples include walking, running, climbing, and swimming locomotion.

Different types of movement in living organisms include:

- **Amoeboid Movement:** Movement exhibited by macrophages and leucocytes in blood, involving changes in cell shape.
- **Ciliary Movement:** Coordinated movement of cilia, such as in the trachea to remove dust particles and in the fallopian tubes to move ova.
- **Flagellar Movement:** Movement of spermatozoa and certain protozoans like *Euglena*, involving whip-like flagella.
- **Muscular Movement:** Movement of limbs, jaw, and tongue, involving contraction of muscles.

Muscle Structure and Properties

Muscles are specialized tissues of mesodermal origin with properties including excitability, contractility, extensibility, and elasticity.

There are three types of muscles based on location and function:

- **Skeletal Muscles:** Attached to bones, involved in locomotion and posture, striated and voluntary.
- **Visceral (Smooth) Muscles:** Found in walls of hollow organs, non-striated and involuntary.
- **Cardiac Muscles:** Found in the heart, striated and involuntary.

Skeletal muscles are composed of bundles called fascicles, held together by connective tissue called fascia. Each fascicle contains muscle fibers with alternating light (I-band) and dark (A-band) bands due to actin and myosin proteins.

The sarcomere, the functional unit of muscle contraction, lies between two Z lines and contains thin (actin) and thick (myosin) filaments. The sarcomere contains thin filaments and thick filaments.

Thin filaments are composed of two helical F-actin strands, tropomyosin, and troponin. Thick filaments consist mainly of myosin, which has globular heads.

Sliding Filament Theory

Muscle contraction occurs by the sliding of thin filaments over thick filaments, shortening the sarcomere. The process begins with a signal from the brain releasing acetylcholine at the neuromuscular junction, generating an action potential in the sarcolemma.

Muscle fibers are classified as red (aerobic) fibers containing myoglobin and many mitochondria for oxygen storage and white fibers with less myoglobin and fewer mitochondria.

Skeletal System

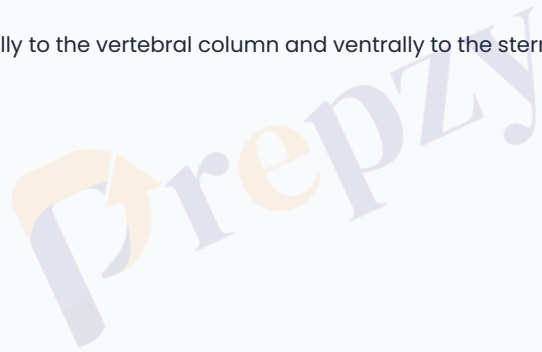
The skeletal system provides the framework of bones and cartilage, consisting of 206 bones in humans. It is divided into two main parts:

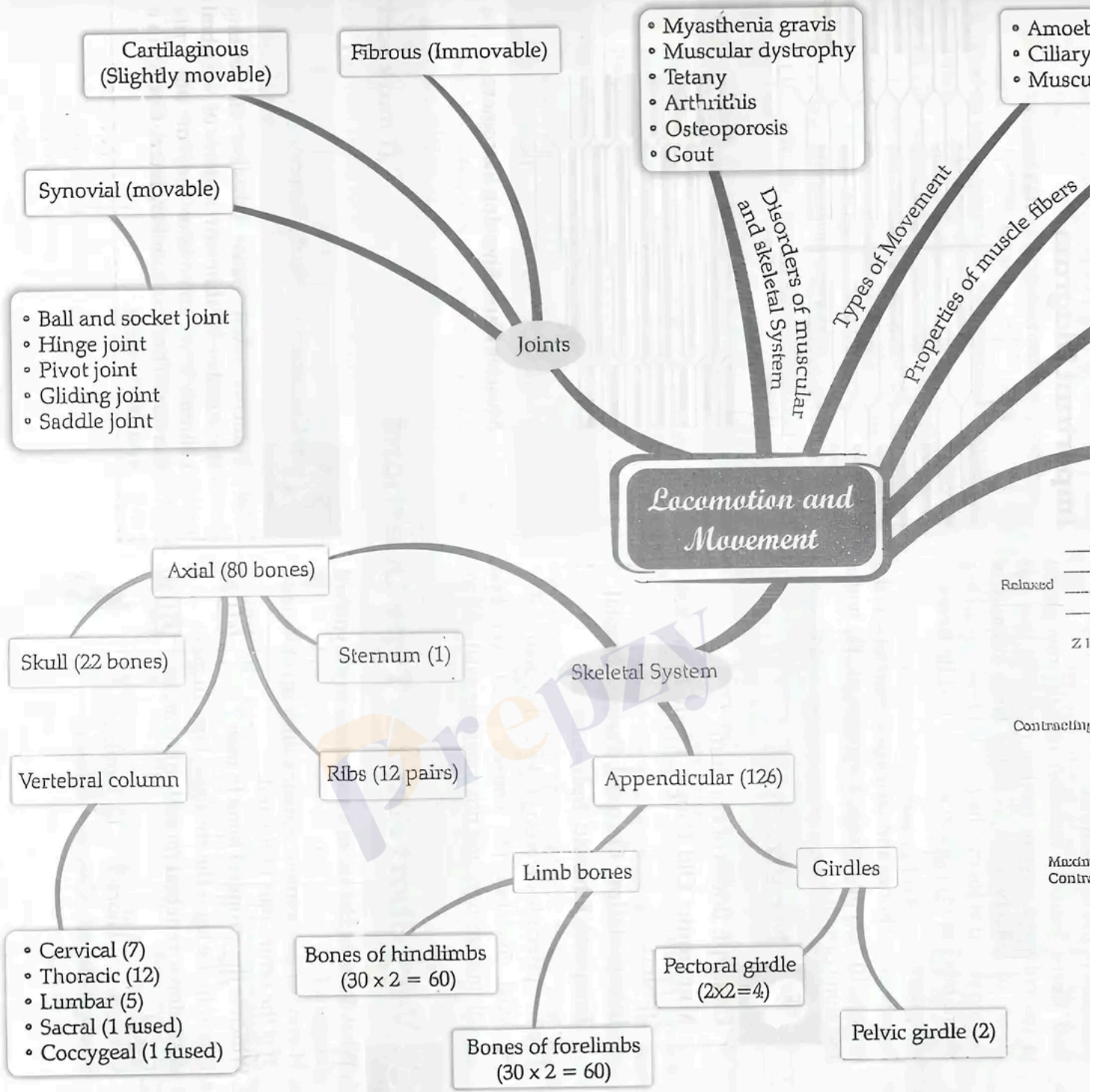
- **Axial Skeleton (80 bones):** Includes the skull, vertebral column, ribs, and sternum.
- **Appendicular Skeleton (126 bones):** Includes bones of limbs and girdles.

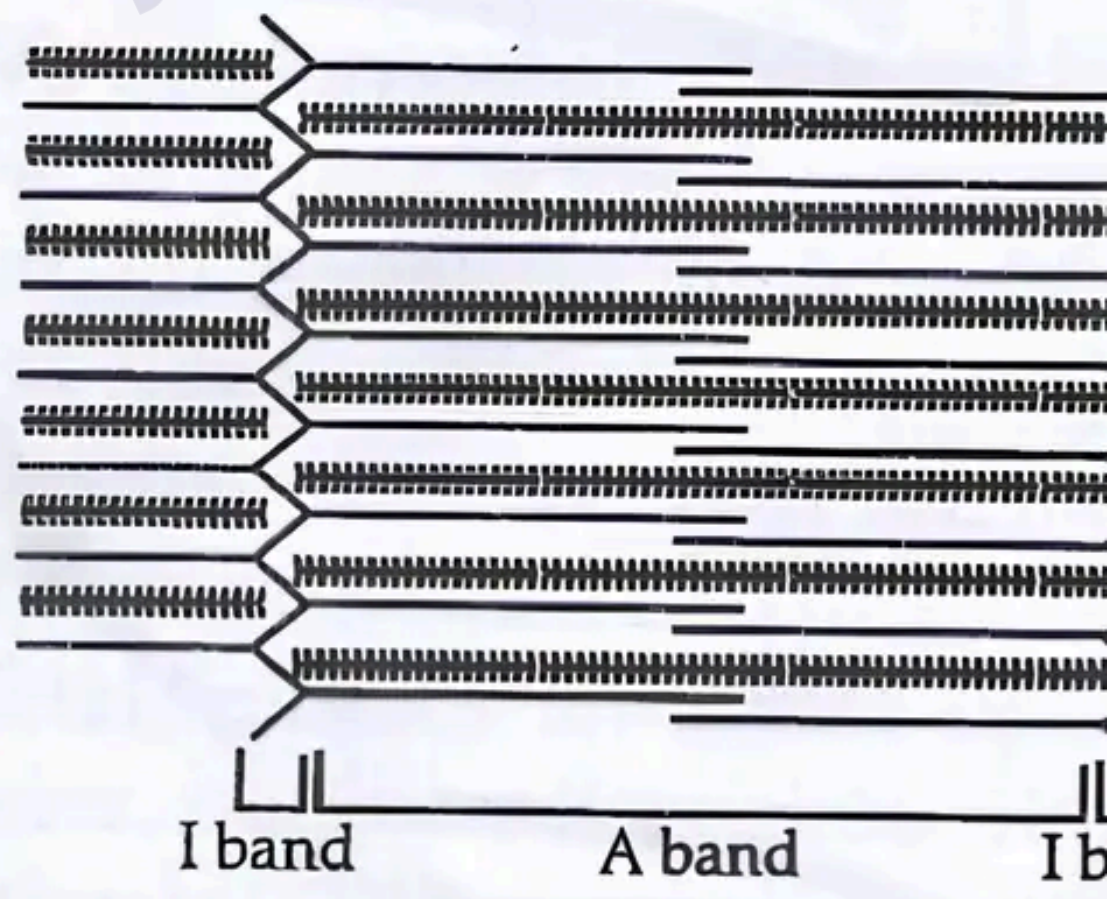
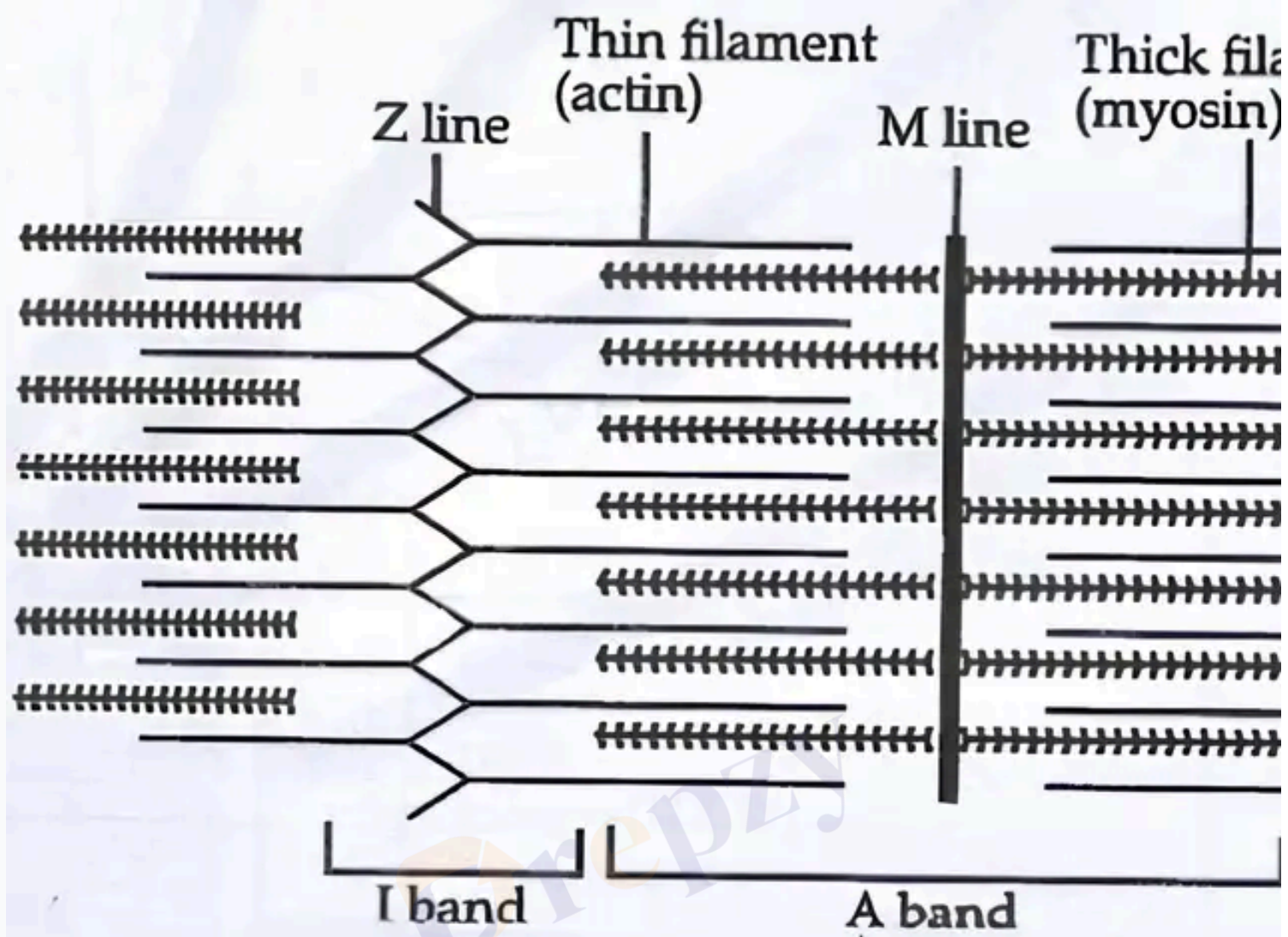
The skull has 22 bones: 8 cranial bones protecting the brain and 14 facial bones forming the front part of the skull. The hyoid bone supports the larynx. The middle ear bones: malleus, incus, and stapes.

The vertebral column has 26 vertebrae: 7 cervical, 12 thoracic, 5 lumbar, 1 sacral, and 1 coccygeal. The first vertebra, atlas, articulates with the scapula.

There are 12 pairs of ribs connected dorsally to the vertebral column and ventrally to the sternum. The 11th and 12th ribs are floating ribs as they are not connected to the sternum.







Muscles fibres Showing Sar

Solved Examples

Example 1: Explain the role of the sarcomere in muscle contraction.

Solution: The sarcomere is the basic contractile unit of a muscle fiber, located between two Z lines. It contains thin (actin) and thick (myosin) filaments, shortening the sarcomere and thus the muscle fiber. This sliding is powered by the interaction of myosin heads with actin filaments.

Example 2: Differentiate between axial and appendicular skeleton.

Solution: The axial skeleton consists of 80 bones including the skull, vertebral column, ribs, and sternum, forming the central axis of the body. The appendicular skeleton consists of 120 bones, including the arms and legs, and girdles, responsible for movement and locomotion.

Practice Set

- **Level 1 (Easy):** What are the three types of muscles found in the human body?
- **Level 2 (Moderate):** Describe the structure of a sarcomere and its role in muscle contraction.
- **Level 3 (Challenging):** Explain the differences between fibrous, cartilaginous, and synovial joints with examples.

Answer Key

- **Level 1:** Skeletal muscles, visceral (smooth) muscles, and cardiac muscles.
- **Level 2:** The sarcomere is the functional unit of muscle contraction, located between two Z lines. It contains thin filaments (actin) and thick filaments, shortening the sarcomere and causing muscle contraction.
- **Level 3:** Fibrous joints are immovable joints found in skull bones. Cartilaginous joints allow limited movement and are connected by cartilage. Synovial joints allow free movement and are connected by a fluid-filled cavity, examples include ball and socket joints like the hip.

Joints and Disorders

Types of Joints

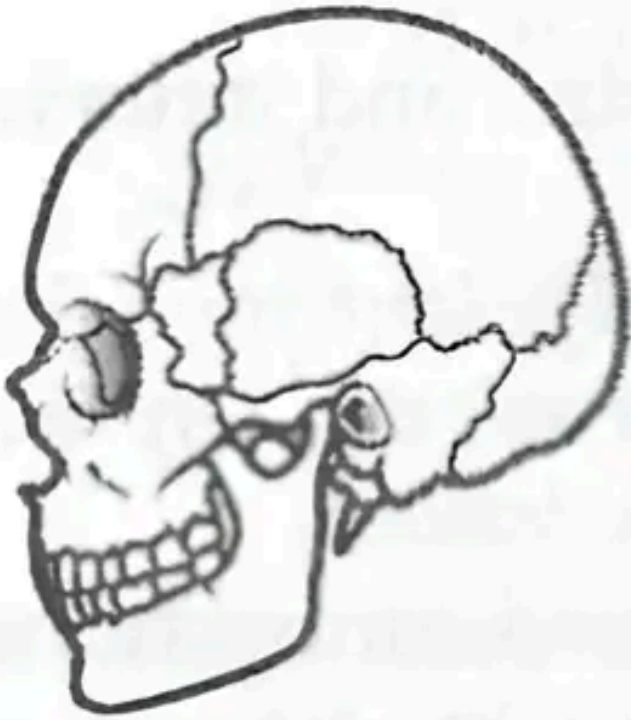
Joints are points of contact between bones or between bones and cartilage. They are classified into three types:

- **Fibrous Joints:** Immovable joints found in flat skull bones forming the cranium.
- **Cartilaginous Joints:** Bones held together by cartilage, allowing limited movement, such as vertebrae.
- **Synovial Joints:** Freely movable joints with a fluid-filled synovial cavity. Types include ball and socket, hinge, pivot, and gliding joints.

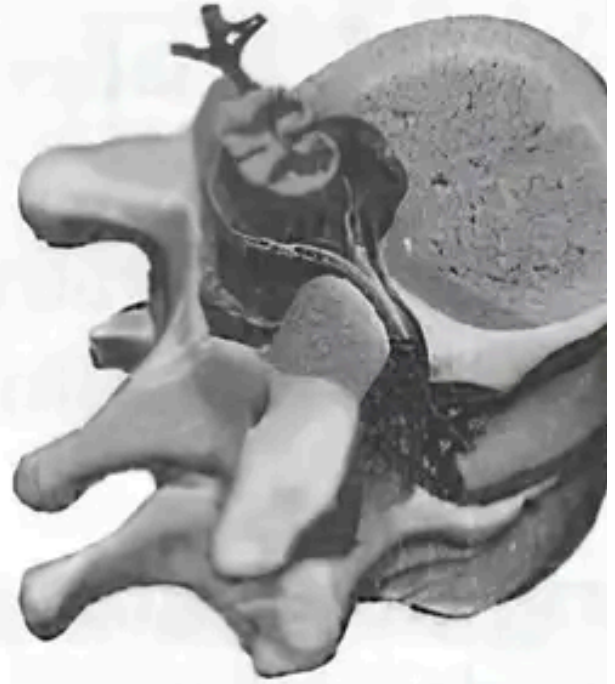
Disorders of Muscular and Skeletal System

- **Myasthenia Gravis:** An autoimmune disorder affecting the neuromuscular junction, causing muscle fatigue and weakness.
- **Muscular Dystrophy:** Genetic disorder causing degeneration of skeletal muscles.
- **Osteoporosis:** Decreased bone mass leading to fractures, common in old age due to decreased estrogen.
- **Arthritis:** Inflammation of joints causing pain and stiffness.
- **Gout:** Inflammation of joints due to accumulation of uric acid crystals.

- **Tetany:** Rapid muscle spasms caused by low calcium levels in body fluids.



**Fibrous
joints**



**Cartilaginous
joints**

Types of Joint

Solved Examples

Example 1: What type of joint is found in the human skull and what is its movement capability?

Solution: The joints in the human skull are fibrous joints. They are immovable, providing protection to the brain.

Example 2: Name a disorder caused by the degeneration of skeletal muscles and describe its effect.

Solution: Muscular dystrophy is a genetic disorder causing degeneration of skeletal muscles, leading to muscle weakness and loss of function.

Practice Set

- **Level 1 (Easy):** Define synovial joints and give two examples.
- **Level 2 (Moderate):** List three disorders of the muscular and skeletal system and their causes.
- **Level 3 (Challenging):** Explain the autoimmune nature of myasthenia gravis and its effect on muscles.

Answer Key

- **Level 1:** Synovial joints are freely movable joints with a fluid-filled cavity. Examples include ball and socket joints (hip) and hinge joints (elbow).
- **Level 2:** Myasthenia gravis (autoimmune disorder affecting neuromuscular junction), muscular dystrophy (genetic degeneration of muscle fibers).
- **Level 3:** Myasthenia gravis is an autoimmune disorder where antibodies attack the neuromuscular junction, impairing signal transmission.

Quick Reference Table

- **Locomotion:** Voluntary movement from one place to another.
- **Muscle Types:** Skeletal (striated, voluntary), Visceral (smooth, involuntary), Cardiac (striated, involuntary).
- **Sarcomere:** Functional unit of muscle contraction between two Z lines.
- **Joints:** Fibrous (immovable), Cartilaginous (slightly movable), Synovial (freely movable).
- **Disorders:** Myasthenia gravis, muscular dystrophy, osteoporosis, arthritis, gout, tetany.

Common Mistakes and Misconceptions

- Not all movements are locomotion; locomotion specifically refers to movement from one place to another.
- Confusing muscle types: skeletal muscles are voluntary and striated, while smooth muscles are involuntary and non-striated.
- Assuming all joints allow movement; fibrous joints are immovable.
- Believing muscle contraction shortens thick filaments; actually, thin filaments slide over thick filaments.

Glossary

- **Neuromuscular Junction:** The synapse between a motor neuron and a muscle fiber.
- **Isotonic Contraction:** Muscle contraction with constant tension and change in length.
- **Isometric Contraction:** Muscle contraction with increased tension but no change in length.
- **Motor Unit:** A motor neuron and all the muscle fibers it innervates.
- **Rigor Mortis:** Postmortem stiffening of muscles due to chemical changes.
- **Sprain:** Injury caused by twisting or tearing of ligaments in joints.
- **Dislocation:** Displacement of a bone from its joint.
- **Rheumatoid Arthritis:** Inflammation of synovial membrane in joints.