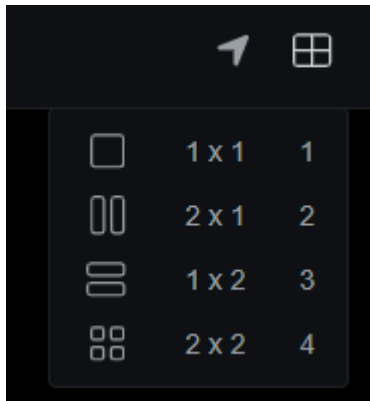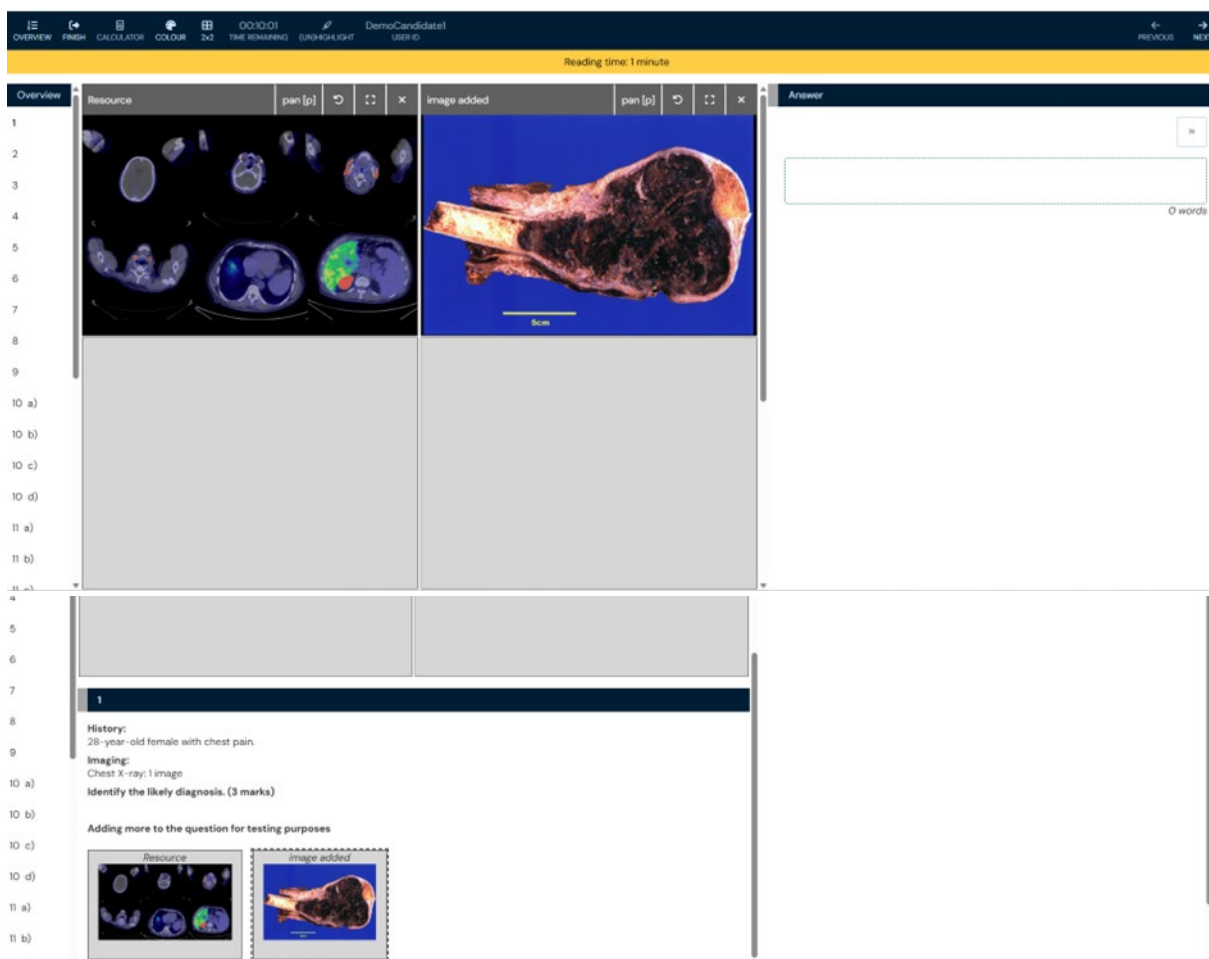


1. We have had user feedback requesting the option to view images in a 2 X 1 grid. So they could read the question and view the images.
2. We have confirmed the interface our users practice on offers the following:





3. In risr/assess the current written exam view, if the user has 2 images in the 2 X 2 the question is thrown to the bottom of the page and there is wasted space taken up with empty grid squares:



4. In risr/assess current OSCER view - it wouldn't have much difference if the 2 X 1 option was added (for our exams anyway)

Frontal CXR | scroll (140) | connect to 21001 Examiner\_21001 Demo

Case History | Matchscore

**Case History**

29-year-old woman admitted to ICU with high fever and tachypnoea.

**CARDIO - Sample Case 5 - Sickle Crisis**

A grade is assigned to each of the observable criteria.

**DIAGNOSTIC HISTORY**

What are the key findings? (10x 2 marks)

- Sickle (dense air space consolidation at Jones CT, NG in situ, Vascem in RA, ill-shaped vertebrae (1))
- Left humeral bone infarct (1)
- Cholecystectomy clips

**INTERPRETATION**

Given the appearance of the bones what is the most likely diagnosis? (10x 2 marks)

- Sickle crisis
- Acute chest syndrome

**MANAGEMENT**

Why is a Vascath the preferred vascular access line for patients with acute Sickle Cell crisis? (10x 2 marks)

Frontal CXR | scroll (140)