

## Hyperpolarized interstitial pH imaging reveals grade dependent acidification in prostate cancer

**Robert R. Flavell**<sup>1,2,7</sup>, David E. Korenchan<sup>1</sup>, Sinan Wang<sup>1</sup>, Kristina Liu<sup>1</sup>, Renuka Sriram<sup>1</sup>, Robert Bok<sup>1</sup>, Hao Nguyen<sup>3</sup>, David M. Wilson<sup>1</sup>, Davide Ruggero<sup>3</sup>, Michael Evans<sup>1,3</sup>, John Kurhanewicz<sup>1,2,3</sup>

<sup>1</sup>Departments of Radiology and Biomedical Imaging, <sup>2</sup>Pharmaceutical Chemistry, and <sup>3</sup>Urology, University of California, San Francisco

### BACKGROUND

There is an unmet clinical need for imaging biomarkers distinguishing indolent from aggressive localized prostate cancer. Recently, we have developed a high-resolution method for imaging tissue interstitial pH using hyperpolarized <sup>13</sup>C MRI (HP pH MRI) in murine prostate cancer models. We hypothesized that decreased tumor interstitial pH is associated with the presence of high grade, potentially lethal prostate cancer.

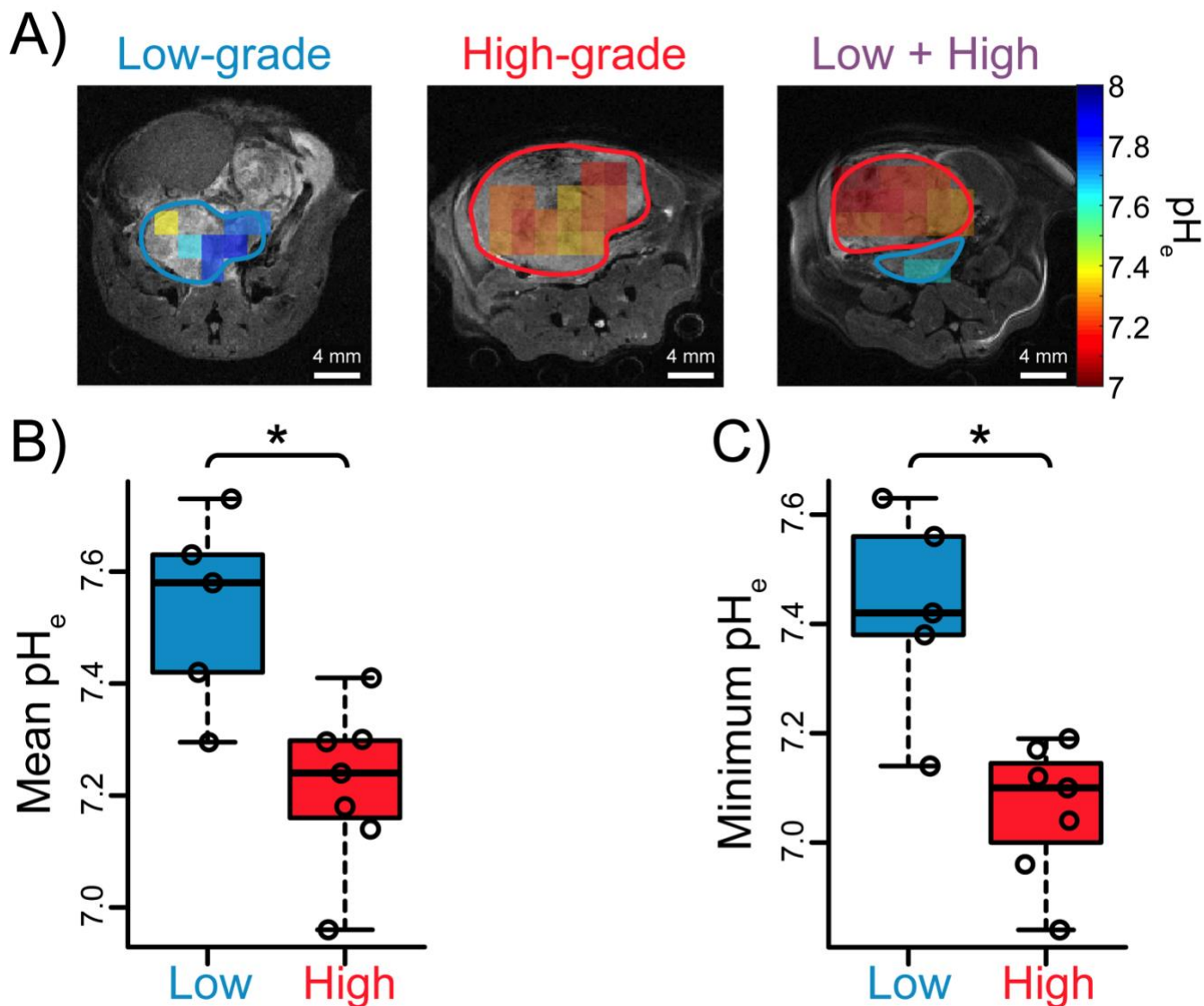
### METHODS

Mouse imaging protocol: TRAMP mice were anesthetized, placed within a 14 T Varian imaging system, and imaged with <sup>13</sup>C MRI including HP [<sup>13</sup>C]bicarbonate (BiC), produced from [<sup>13</sup>C]1,2-glycerol carbonate.

Pathology: The mouse was euthanized, and tumor regions were classified by a trained pathologist as low- or high-grade.

### RESULTS

We performed HP pH MRI in a cohort of TRAMP mice (Figure 1A). Histologic analysis demonstrated both pure low and high grade tumors, as well as some containing both high and low grade tumor components, mimicking the situation commonly seen in human prostate cancer. Notably, high grade tumors demonstrated acidic extracellular pH compared against low grade counterparts, with a statistically significant difference seen between the two groups (Figure 1B, 1C). These data demonstrate that acidic pH is associated with high grade disease and aggressive behavior in the TRAMP model.



**Figure.** A) Representative overlays of extracellular pH measured with hyperpolarized  $[^{13}\text{C}]$ bicarbonate in TRAMP mice. High grade tumors are circled in red, and low grade in blue. B-C) Scatter plots demonstrating significant differences in pH metrics obtained from HP  $^{13}\text{C}$  images between low- and high-grade regions over all mice: B) mean; and C) regional-minimum ( $n = 5$  low-grade,  $n = 7$  high-grade).  $*p < 0.05$

## CONCLUSIONS

Using HP pH MRI, we observed a decrease in  $\text{pH}_e$  when comparing high and low grade mouse TRAMP tumors, including in cases where both low and high grade tumors were observed in the same animal. These results establish interstitial acidification as a biomarker of PCa indolent-to-aggressive transition, and suggest feasibility for this method in a subsequent translational study to distinguish low and high grade prostate cancer.

**Conflicts of interest:** None

**Funding Acknowledgements:** Dr. Flavell would like to acknowledge the David Blitzer PCF Young Investigator Award, a Department of Defense Physician Research Training Award (PC150932), NIH R21 CA0121429, and startup funds from the University of California, San Francisco Department of Radiology and Biomedical Imaging.