

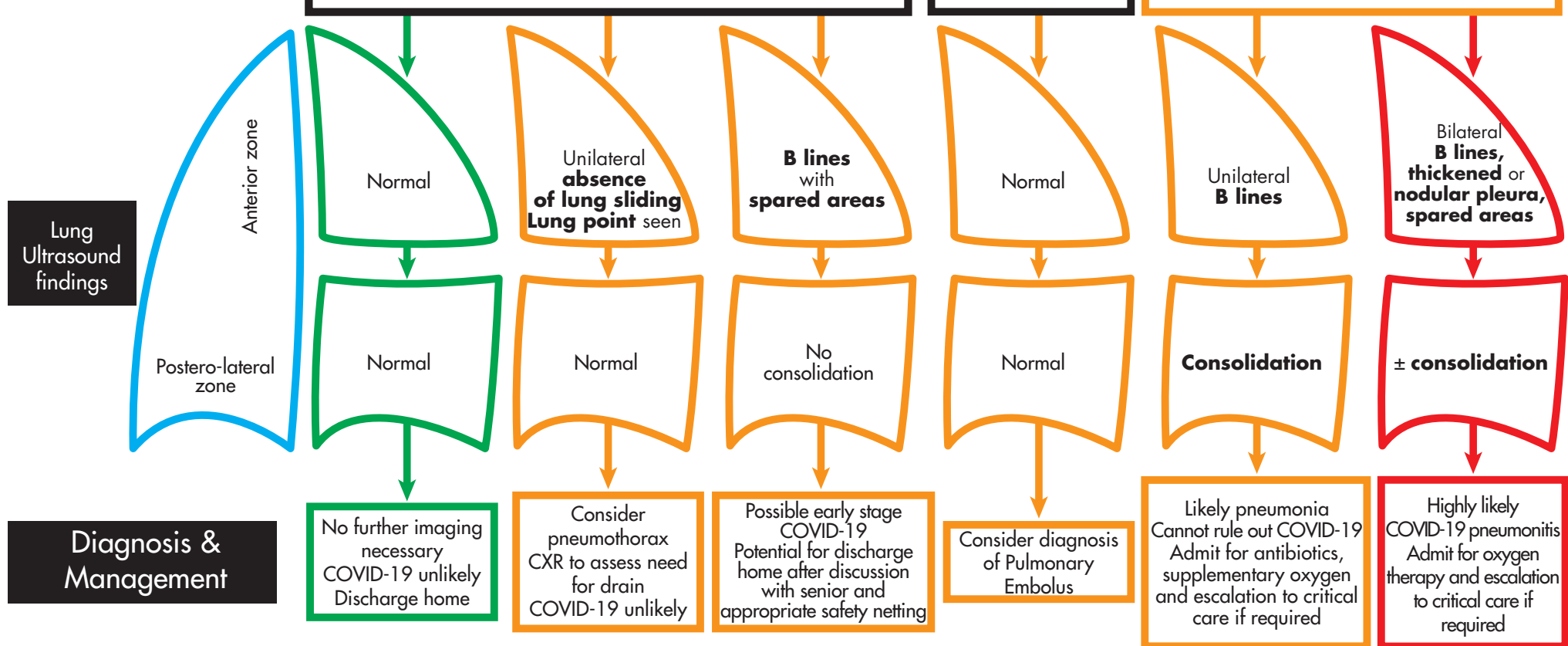
Lung ultrasound decision tree for newly presenting patients with suspected COVID-19 and no significant past medical history

Patient with shortness of breath / cough / fever
No significant past medical history and satisfies triage criteria for full escalation

Oxygen saturations $\geq 94\%$ on minimal exertion

Wells score ≥ 2

Oxygen saturations $\leq 94\%$ on minimal exertion



Both lungs should be scanned using a total of at least 6 zones

References:
1. Uehara et al. Relevance of lung ultrasound in the diagnosis of acute respiratory failure: the BLUE protocol. Chest 2008.
2. Huang Y, Li Y, Zhang Y, et al. A preliminary study on the ultrasonic manifestations of peripheral lesions of non-critical novel coronavirus pneumonia during the 2019-2020 epidemic. Intensive Care Med 2020.
3. Feng QX, Wang XJ, Zhang JN. Findings of lung ultrasonography of novel coronavirus pneumonia during the 2019-2020 epidemic. Intensive Care Med 2020.