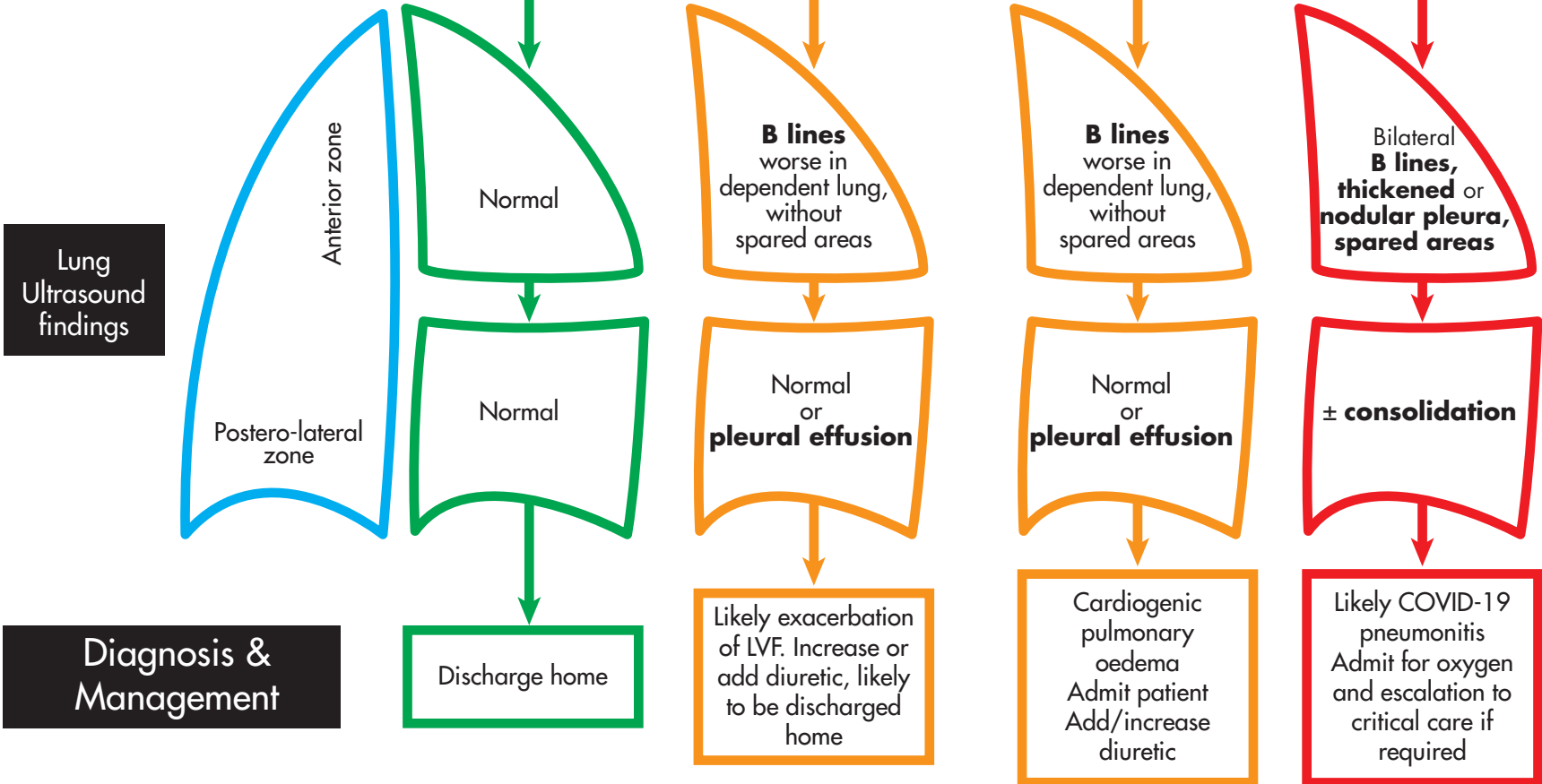


Lung ultrasound decision tree for newly presenting patients with suspected COVID-19 and mild LVF (NYHA I and II)

Patient with shortness of breath / cough / fever
Past medical history is of mild LVF (NYHA grade II or II) and satisfies triage criteria for full escalation

Oxygen saturations $\geq 94\%$ on minimal exertion

Oxygen saturations $\leq 94\%$ on minimal exertion



Both lungs should be scanned using a total of at least 6 zones

This decision tree is designed for patients who meet criteria for full escalation.
The ultrasound signs described are still accurate in individuals with more severe LVF and can be used as a diagnostic guide