

# VascuFlex® Multi-LOC

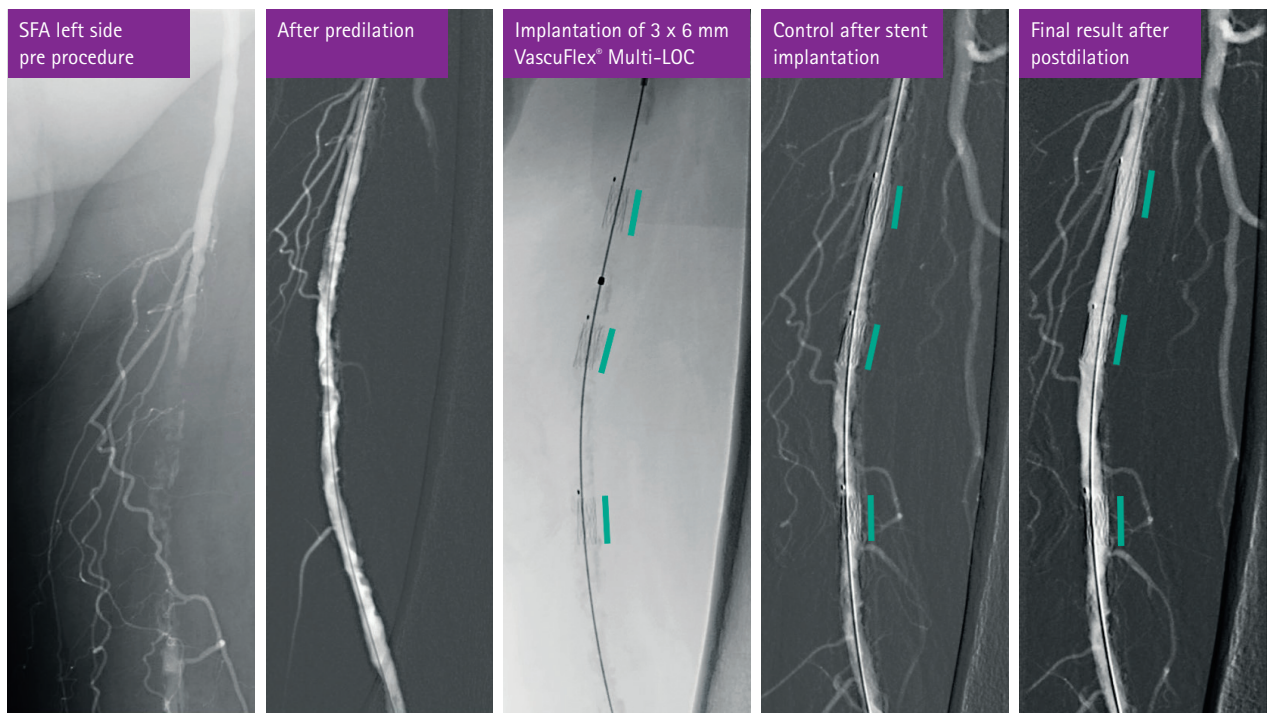
## CASE REPORT: CALCIFIED SFA WITH TOTAL OCCLUSION

### CLINICAL DATA

- 75y old male patient
- Severe calcification & occlusion of SFA left side
- Rutherford class 3
- ABI 0.68
- Walking distance 30 m
- Ex smoker & hypertension

### TREATMENT STRATEGY

- Retrograde crossover approach right side
- 4F sheath & pigtail angio
- 6F sheath (Destination)
- 4F guiding catheter & V18 guidewire
- Predilation with 5x120 mm & 6x120mm POBA
- Change to 0.035" guidewire
- Implantation of 3x VascuFlex® Multi-LOC stent (6 mm)
- Postdilation with 6x100 mm POBA



Courtesy of Dr. Klaus Amendt, Germany