

VascuFlex® Multi-LOC: Spot Stenting With SeQuent® Please OTW DCB

Realizing the concept of leave-less-behind after DCB angioplasty in atherosclerotic lesions of the femoropopliteal artery.

BY KLAUS AMENDT, MD, AND RALF LANGHOFF, MD



Klaus Amendt, MD



Ralf Langhoff, MD

Percutaneous intervention is the preferred first-line treatment modality for femoropopliteal lesions, but questions about optimizing therapy remain—especially when it comes to stent application.

The “full metal jacket” concept of lesion coverage was questioned by the FESTO trial,¹ which showed stent fractures predominantly close to hinge and flex points in the femoropopliteal artery, leading to reduced patency rates. Nitinol stents with a helical cell design capable of mimicking arterial movement were developed to combat these biomechanical properties. This second generation of nitinol stents showed improved data but was still inferior to historical results with open bypass surgery. Chronic trauma of the vessel wall, such as the continuous outward force caused by oversizing stent diameter, vessel-to-stent interaction due to arterial motion (torsion, compression, and distention), and pulsatile distension were noted as reasons for late failure.

INCORPORATING DRUG-ELUTING TECHNOLOGIES

To inhibit intimal hyperplasia, stents were covered with antiproliferative drugs (eg, sirolimus).² The fast release of the drug from stent (drug-eluting stent [DES]) to vessel wall showed an initial benefit compared to a non-DES, but after 6 months, disappointingly, the effects diminished.

Stents with release of paclitaxel showed encouraging results in comparison to optimal results with standard

percutaneous transluminal angioplasty (PTA) and provisional implantation of an identical non-drug-eluting nitinol stent.³ The positive results, however, were limited to short and medium lesion lengths only, making it necessary to optimize balloon results for long lesions and avoid stents.

Most recently, proof of concept has been shown in numerous trials supporting drug-coated balloon (DCB) technology, and it is now adopted into routine treatment. However, DCB pivotal trials enrolled only patients with short lesion lengths (mean, 5–8 cm), meaning they did not entirely represent the complexity of day-to-day practice.

In contrast to all other proof-of-concept DCB trials, the CONSEQUENT trial (NCT01970579) showed statistically significant superiority of the SeQuent® Please OTW DCB (B. Braun Melsungen AG) cohort when compared to PTA alone, even in long femoropopliteal lesions (mean, 13.2 cm) after 6 and 12 months. In the CONSEQUENT randomized, angiographically controlled, core lab–adjudicated trial, rates of late lumen loss (0.35 mm vs 0.72 mm; $P = .006$) and binary restenosis (22.2% vs 43.1%; $P = .019$) were excellent, supported by superiority in 12-month target lesion revascularization (TLR) rates (17.8% vs 37.7%; $P = .008$), walking capacity (165 vs 94 m; $P = .012$), and Rutherford clinical class shift (2.5 ± 1 vs 1.8 ± 1.3).⁴ Nevertheless, as in all other DCB trials, the rate of bailout stenting was 16.3% due to flow-limiting dissections, recoil, and calcification. The stent rate in DCB studies increases with lesion length and severity of vessel calcification.⁵ In long lesions, coverage with long DESs does not show superiority over DCB in regard to bailout stenting.⁶

TABLE 1. 12-MONTH TRIAL RESULTS

	Zilver FLEX Arm	Zilver PTX Arm	SuperNOVA (Innova)	MAJESTIC (Eluvia)	4EVER (Pulsar)	DEBAS (Pulsar + Passeo-18 Lux)
N	—	474	299	57	120	65
Average lesion length	6.6 cm	6.6 cm	9.3 cm	7.1 cm	7.1 cm	18.8 cm
Ankle-brachial index	—	—	—	0.73 at baseline to 1.02	0.68 at baseline to 0.98	0.39 at baseline to 1.03
Diabetic	42%	49.6%	40.5%	35.1%	35.9%	54.9%
CLI	—	—	—	1.8%	16.7%	58.9%
Occlusion	25%	30%	—	46%	20.8%	—
Calcification	57%	72.6%	70.2%	78.9%	30.8%	66.6%
Primary patency	73%	83.1%	66.4%	96.1%	81.4%	94.1%
Freedom from TLR	—	90.5%	85.8%	96.2%	89.3%	94.1%

Abbreviations: CLI, critical limb ischemia; TLR, target lesion revascularization.

Still, the question remains whether to stent the entire lesion or to perform spot stenting after PTA failure when scaffolding is needed. It becomes evident that endovascular treatment combined with paclitaxel (either on a stent platform or applied with a DCB) is superior to non-drug-supported standard therapy (Table 1). Data from the Zilver PTX trial⁷ (Zilver Flex vs Zilver PTX), the direct comparison from the MAJESTIC⁸ results to those of the SuperNOVA trial⁹ (Eluvia and Innova Stent), and data from the 4EVER trial¹⁰ and the DEBAS trial¹¹ support the drug effect for femoropopliteal stenting. The DEBAS trial systematically investigated the combined and intentional use of the Pulsar-18 stent (Biotronik) followed by local drug delivery with a Passeo-18 Lux DCB (Biotronik).¹¹ Although the mean lesion length was 18.8 cm, the 12-month primary patency was 94.1%.

These findings are supported by the IN.PACT Global registry, which prospectively included a long lesion imaging cohort of femoropopliteal lesions (n = 164).¹² The mean lesion length was 26.4 ± 8.61 cm treated with a DCB, resulting in a provisional stent rate of 40.4% (63/156 patients). Nevertheless, the cumulative primary patency after 12 months by Kaplan-Meier analysis was 91.1%, which is an unexpectedly good result with regard to lesion length and provisional stent use.

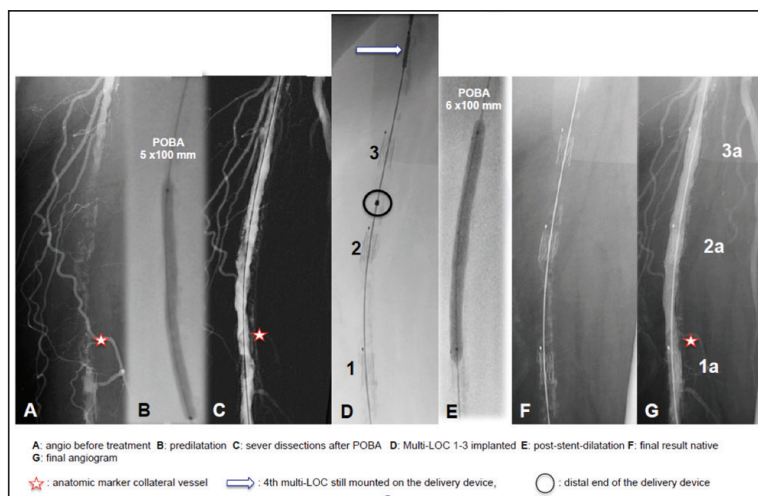


Figure 1. Spot stenting with VascuFlex® Multi-LOC.

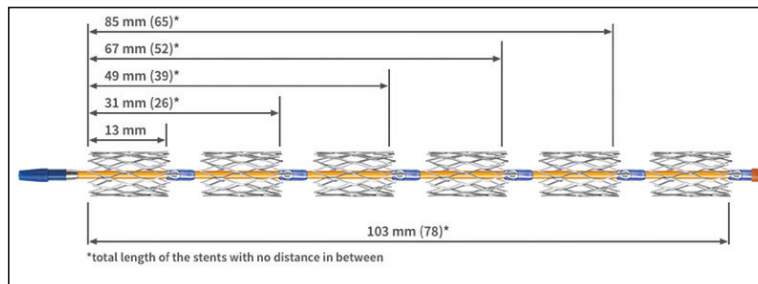


Figure 2. Each stent has a length of 13 mm and is separated by 5-mm spacers.

These results reflect daily practice, as long and complex lesions do not always respond to a PTA- or DCB-only approach in terms of immediate technical success. Scaffolding is mandatory in a certain number of lesions




Figure 3. Each stent on the VascuFlex® Multi-LOC has a closed-cell design.

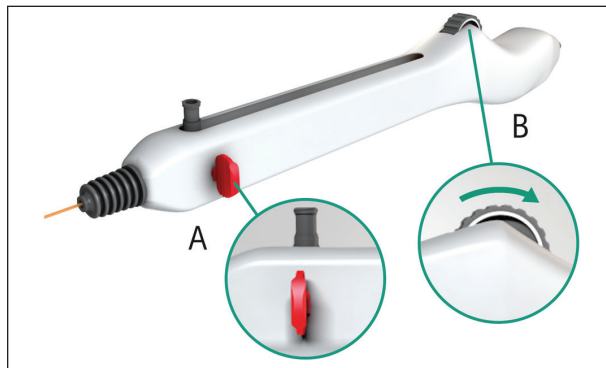


Figure 4. Stents are individually released by the single-hand wheel mechanism.

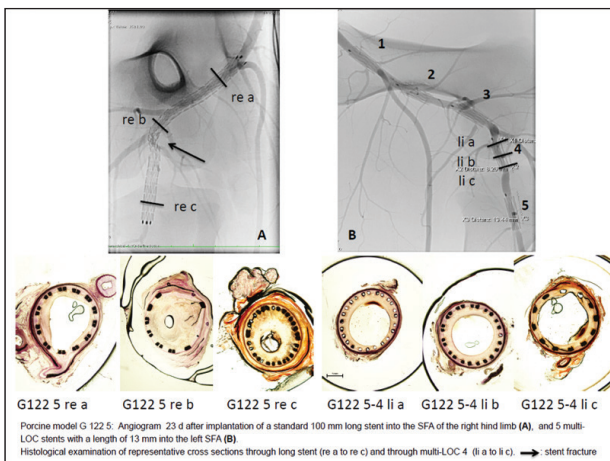


Figure 5. Several preclinical animal models showed a clear benefit of the VascuFlex® Multi-LOC.

depending on the lesion morphology. It is proven that with an increase in lesion length, SFA stent trials show a decrease in primary patency.

STENTS REMAIN INDISPENSABLE

To avoid the chronic trauma of long stents to the vessel wall, a new concept of stenting in combination with DCBs was considered. The idea was to develop a device that enables the interventionalist to implant more than one short individual stent into areas where stenting is mandatory after DCB or standard PTA in the femoropopliteal artery. Spot stenting eliminates flow-limiting dissection or flaps and segments with elastic recoil due to calcification or scar tissue after previous interventions. This reduces the mass of foreign body implants and the associated trauma due to chronic outward force by ongoing radial expansion, especially when stent diameters are oversized (Figure 1). On the other hand, stents must also show sufficient crush resistance to prevent vessel lumen collapse in calcified

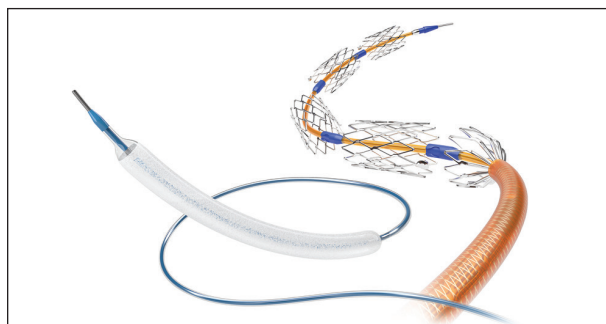


Figure 6. The VascuFlex® Multi-LOC Multiple Stent Delivery System and SeQuent® Please OTW.

lesions with strong recoil. Spot stenting also reduces the negative influence of metal implants on high-movement arterial segments, addressing the biggest demand of the interventional community—to leave nothing or as little as possible behind.

The VascuFlex® Multi-LOC (B. Braun Melsungen AG) is a new device that has up to six individual nitinol stents loaded (Figure 2). Each stent has a closed cell design (Figure 3), a length of 13 mm, and is available in diameters from 5 to 8 mm. The radial force and crush resistance are remarkably high and comparable to standard nitinol stents. The stents are mounted on a 6-F multiple stent delivery system (MSDS) with each stent separated by spacers of 5 mm length and individually releasable with a single-hand wheel mechanism (Figure 4).

Each stent has a radiopaque tantalum marker. This marker is fixed into an excavation of the spacer, preventing the stent from jumping. As long as the marker is covered by the sheath, the stent remains fixed on the delivery system. Slow withdrawal of the outer sheath enables a controlled deployment of each single spot stent. This mechanism is pivotal for a precise, controlled stent release.

The flexibility of the system allows crossover procedures even in complex and tortuous iliac arteries, and the 80-cm and 130-cm working lengths make antegrade access possible.

DATA SUPPORTING SPOT STENTING

After several preclinical animal models showed a clear benefit of the VascuFlex® Multi-LOC MSDS compared to standard nitinol stents, a prospective multicenter registry was established (Figure 5). The LOCOMOTIVE all comers registry¹³ (NCT02531230) documents procedural data as well as preliminary safety and efficacy data of the first results of this novel MSDS. The primary endpoint is the 6-month TLR rate. Femoropopliteal lesions are prepared with uncoated and/or paclitaxel-coated peripheral balloon catheters. When flow-limiting dissections, elastic recoil, or calcification require stenting, short individual spot stents of 13 mm in length are implanted. Duplex ultrasound follow-up and clinical assessments are scheduled at 6 and 12 months after the intervention.

The preliminary results of the first 6 months were presented at LINC 2017 in Leipzig, Germany.¹³ A total of 75 patients were followed (aged 72.9 ± 9.2 years; 20 patients with critical limb ischemia [CLI]; 55 patients with intermittent claudication [IC]). Of the total 176 target lesions, 51.1% (90/176) were TASC class C/D lesions (CLI = 73.1%, IC = 41.9%). The overall total lesion length was 14.5 ± 9 cm, (CLI = 19 ± 9.5 cm, IC = 12.9 ± 8.3 cm); 97.2% of the lesions were severely calcified.

After 6 months, the clinical follow-up rate was 93%. The low TLR rates of 4.3% (TLR_{CLI} = 5.3%, TLR_{IC} = 3.9%) were confirmed by duplex ultrasound. Primary patency was 91.4% overall (patency_{CLI} = 94.7%, patency_{IC} = 90.2%). Clinical results at 6 months after PTA revealed that the MSDS strategy was safe and highly effective in patients with femoropopliteal lesions. The total amount of implanted nitinol stent length was reduced by 50% with a technical success rate of 100% (defined as no flow-limiting dissections or residual stenosis > 30%). Additionally, this led to persisting improvement of ankle-brachial index and walking capacity.

The novel VascuFlex® Multi-LOC MSDS showed excellent performance even in long and severely calcified lesions with a convincing clinical benefit for these severely diseased patients.

Additional studies investigating the combination of DCB angioplasty with optional spot stenting utilizing the SeQuent® Please OTW DCB and VascuFlex® Multi-LOC (Figure 6) are in progress. ■

1. Scheinert D, Scheinert S, Sax J, et al. Prevalence and clinical impact of stent fractures after femoropopliteal stenting. *J Am Coll Cardiol*. 2005;45:312-315.
2. Duda SH, Pusch B, Richter G, et al. Sirolimus-eluting stents for the treatment of obstructive superficial femoral artery disease: six-month results. *Circulation*. 2002;106:1505-1509.
3. Dake MD, Ansel GM, Jaff MR, et al. Sustained safety and effectiveness of paclitaxel-eluting stents for femoropopliteal lesions: 2-year follow-up from the Zilver PTX randomized and single-arm clinical studies. *J Am Coll Cardiol*. 2013;61:2417-2427.
4. Albrecht T. Clinical trial on peripheral arteries treated with SeQuent® Please P paclitaxel coated balloon catheter (ConSeQuent). Presented at: LINC 2017; January 24-27, 2017; Leipzig, Germany.
5. Tepe G. Drug coated balloons: for all or some? Presented at: LINC 2017; January 24-27, 2017; Leipzig, Germany.
6. Scheinert D. First time data release: 2-year results of the REAL-PTX randomised clinical trial comparing Zilver PTX vs. DCB treatment in femoropopliteal lesions. Presented at: LINC 2017; January 24-27, 2017; Leipzig, Germany.
7. Dake MD, Ansel GM, Jaff MR, et al. Paclitaxel-eluting stents show superiority to balloon angioplasty and bare metal stents in femoropopliteal disease. *Circ Cardiovasc Interv*. 2011;4:495-504.
8. Müller-Hülsbeck S, Keirse K, Zeller T, et al. Twelve-month results from the MAJESTIC trial of the Eluvia paclitaxel-eluting stent for treatment of obstructive femoropopliteal disease. *J Endovasc Ther*. 2016;23:701-707.
9. Powell RJ, Jaff MR, Schroë H, et al. Stent placement in the superficial femoral and proximal popliteal arteries with the Innova self-expanding bare metal stent system [published online March 15, 2017]. *Catheter Cardiovasc Interv*.
10. Bosiers M, Deloese K, Callaert J, et al. 4-French-compatible endovascular material is safe and effective in the treatment of femoropopliteal occlusive disease: results of the 4-EVER trial. *J Endovasc Ther*. 2013;20:746-756.
11. Mwiipatayi P. Self-expanding thin strut nitinol stents (Pulsar) plus DEBs: 2-year results from the DEBAS trial are promising. Presented at: VEITH Symposium; November 19, 2015; New York, New York.
12. Brodmann M. A real-world look at treatment effects of IN.PACT Admiral DCB: 12-month results from the IN.PACT Global Study full clinical cohort. Presented at: LINC 2017; January 24, 2017; Leipzig, Germany.
13. Amendt K. 6-month results of the LOCOMOTIVE registry investigating spot stenting in the femoropopliteal tract. Presented at: LINC 2017; January 25, 2017; Leipzig, Germany.

Klaus Amendt, MD

Chief

Department of Internal Medicine

Diakonissenkrankenhaus

Mannheim, Germany

klaus.amendt@diakonissen.de

Disclosures: Inventor of multi stent delivery system (MSDS); lectures for B. Braun.

Ralf Langhoff, MD

Chief

Department of Angiology/Vascular Medicine

Sankt Gertrauden-Krankenhaus

Berlin, Germany

ralf.langhoff@sankt-gertrauden.de

Disclosures: Received honoraria for consulting services and presentations, Terumo Interventional Systems, Boston Scientific Corporation, Abbott Vascular, B. Braun, Contego Medical, CID-Medical, Biotronik, and Medtronic.