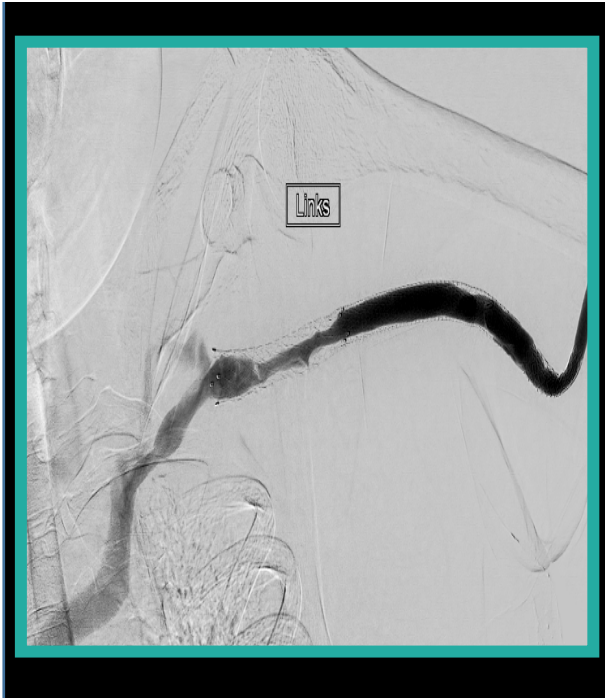



VASCUPEDIA

Stent Graft deployment for AV Graft salvage

Konstantinos Stavroulakis MD
Consultant of vascular and endovascular surgery
University clinic of Muenster
Germany

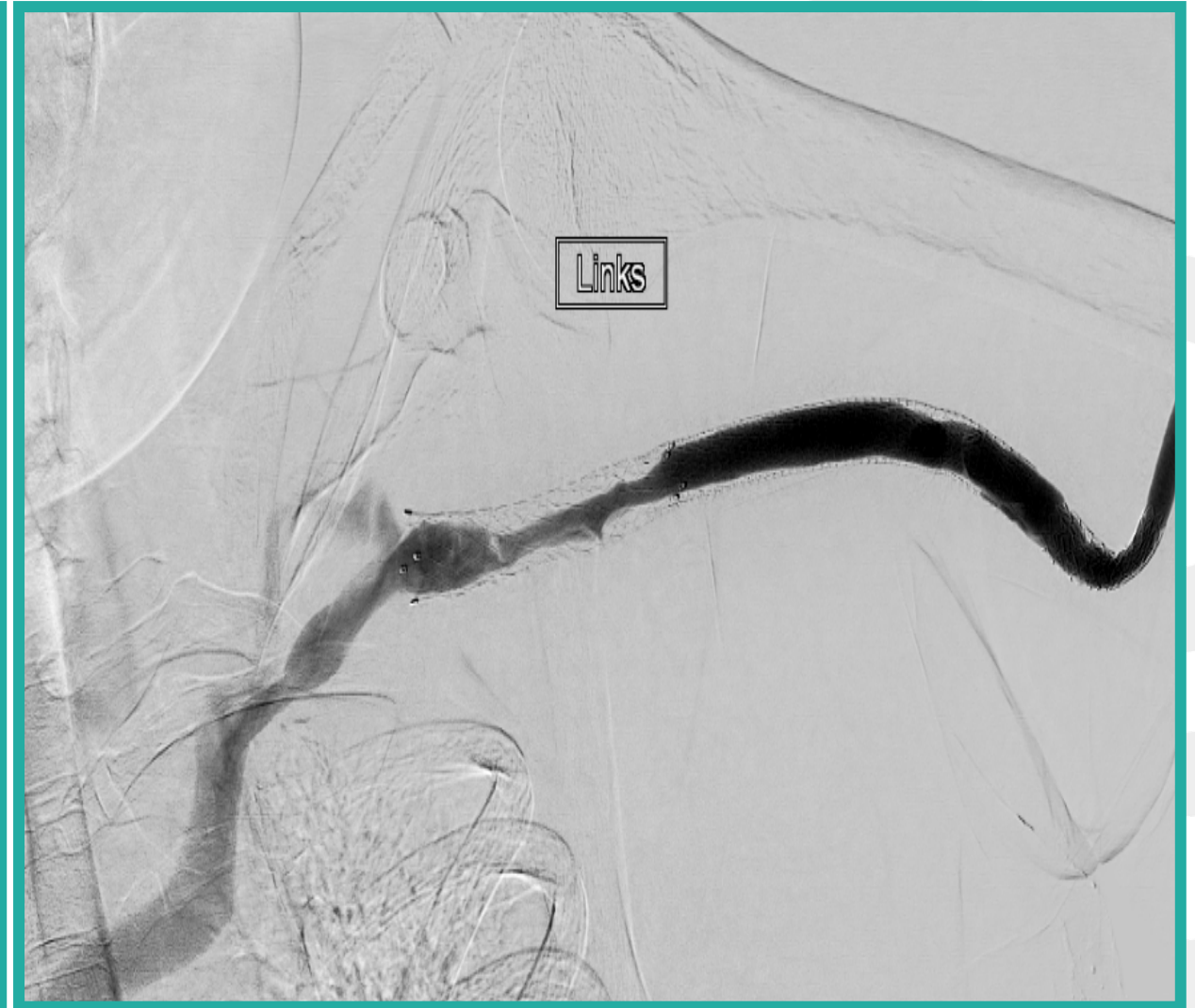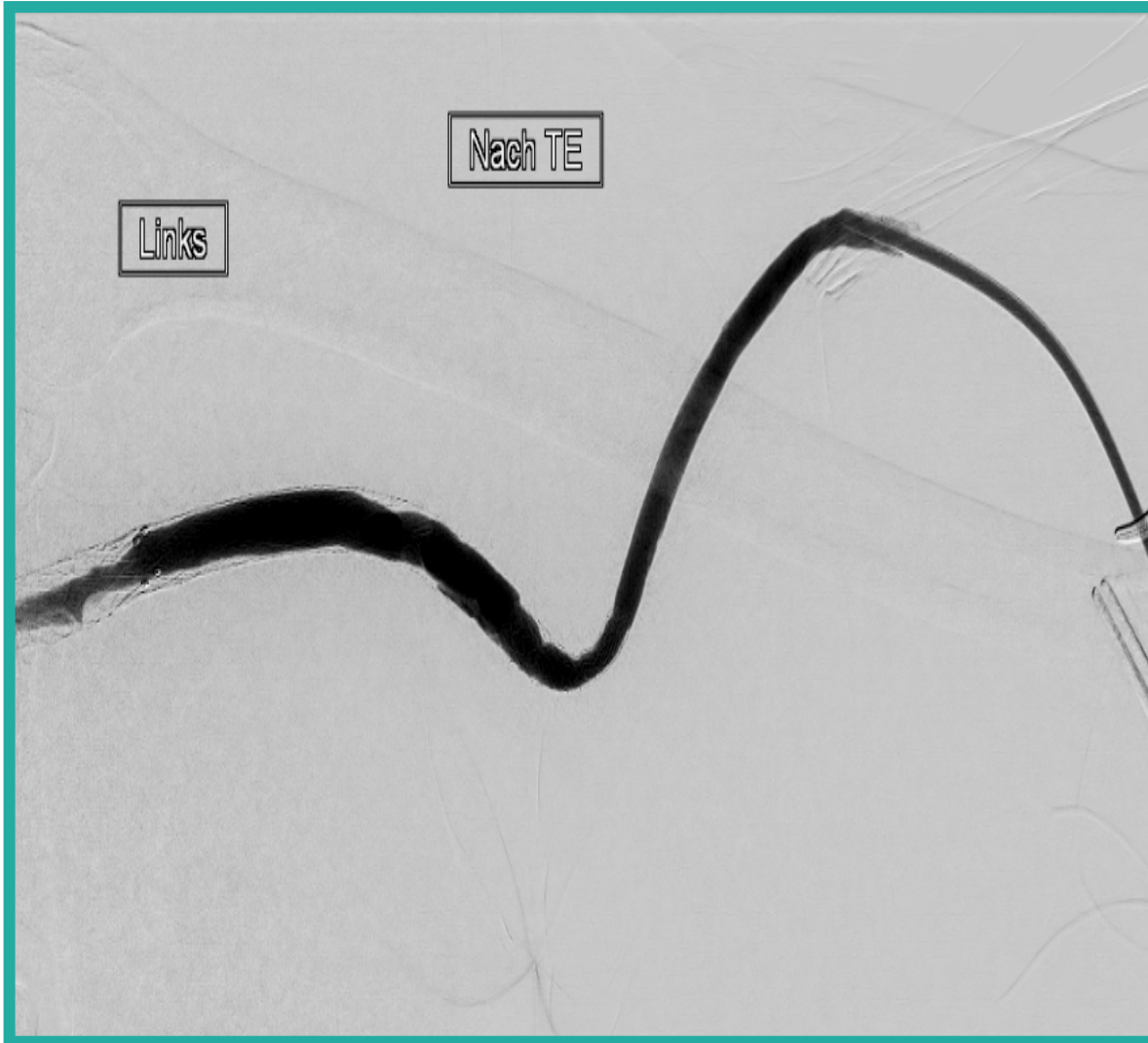




Case Presentation

- Male, 39 yrs. old
- **Comorbidity:** End Stage Renal Disease, Type I diabetes
- Previous deployment of a Bare Metal Stent in the left innominate vein
- Admission with an arterio-venous graft (AV graft) occlusion

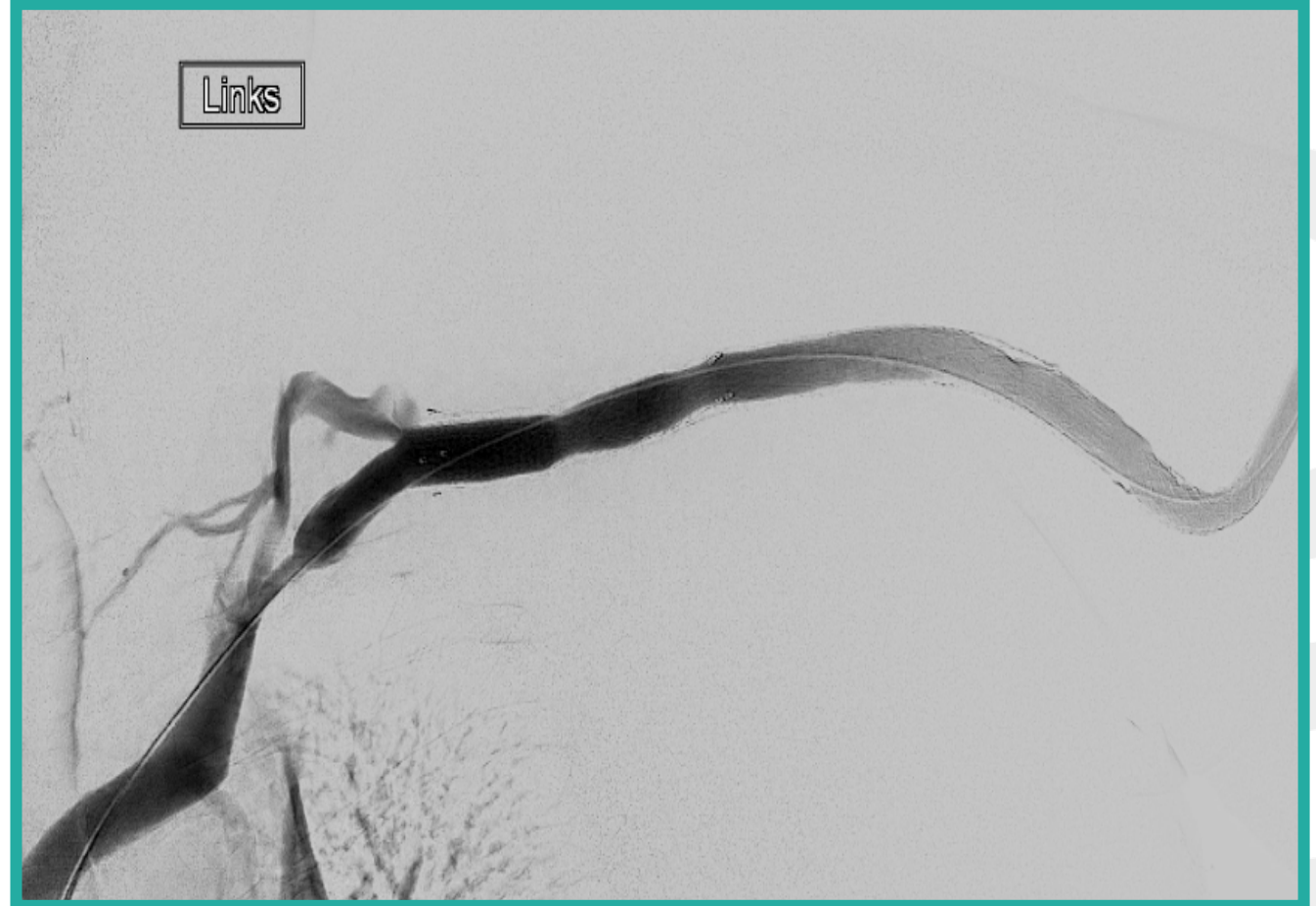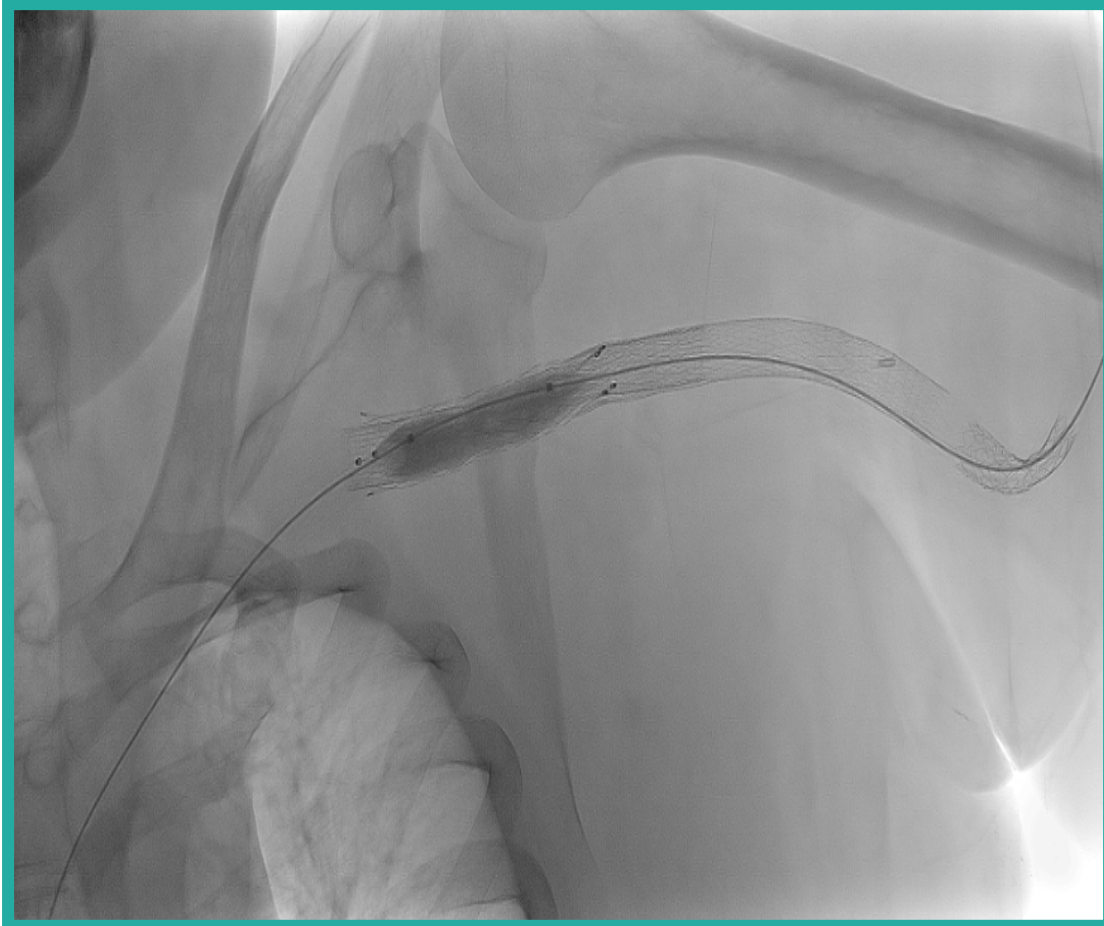
Phlebography after surgical thrombectomy



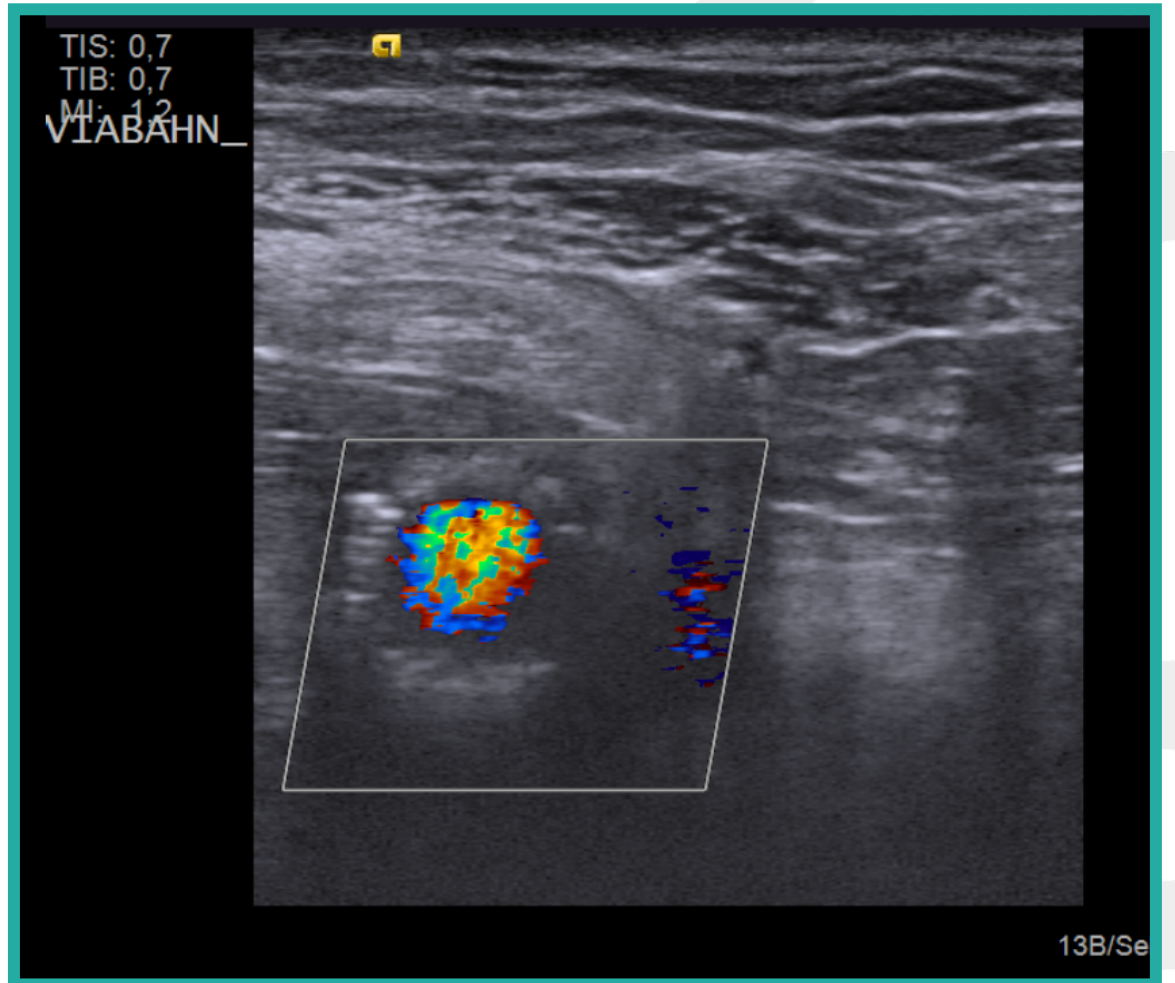
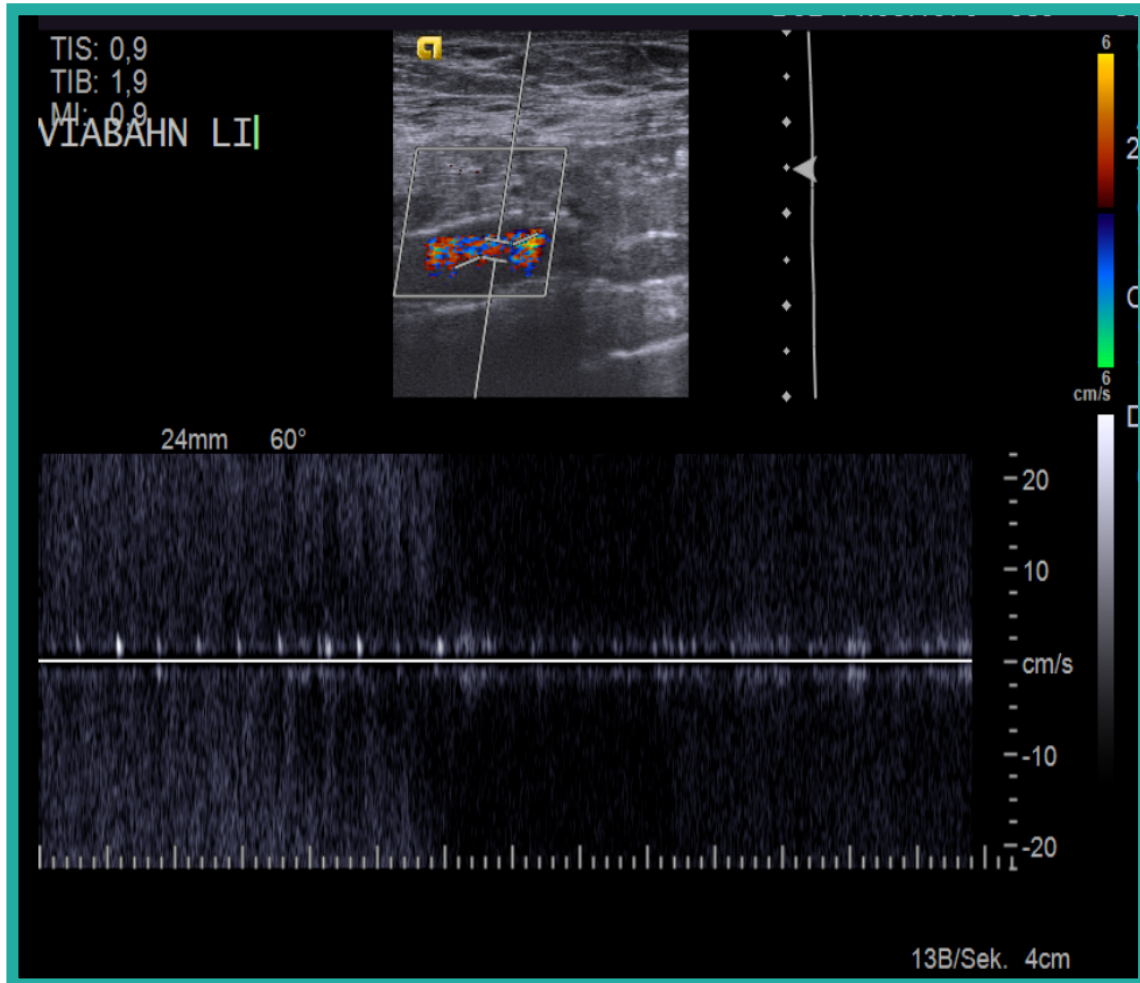
How would you treat this In-Stent Restenosis?

- Drug coated balloon (DCB) angioplasty as standalone therapy?
- Vessel prep + DCB?
- Plain old balloon angioplasty as standalone therapy?
- Stent graft deployment?
- Bare Metal Stent Deployment?

Our Strategy: GORE® VIABAHN® Endoprosthesis



2 Months follow up



Questions to the Vascupedians

- Do you always perform a final phlebography/angiography after Shunt/AV Graft-Thrombectomy?
- How do you avoid over-/under-sizing in vein interventions?
- Do you think that DCB angioplasty +/- Vessel prep should be used for vein ISR?
- Which would be your medical treatment after stent graft deployment: Single antiplatelet therapy, dual antiplatelet therapy, anticoagulation?
- Do you prescribe a statin to improve the patency of an AV Graft/fistula?