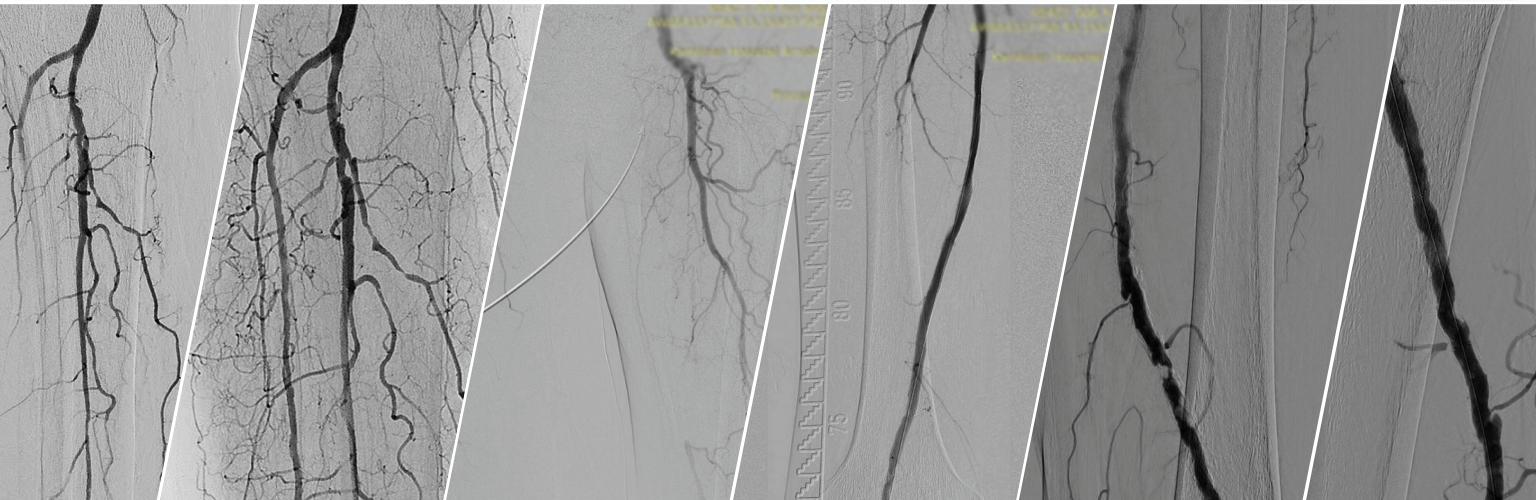


Endovascular TODAY

EUROPE

2020 | Volume 8, No. 4

EXPERT CASES ON CTO MANAGEMENT



Techniques for crossing and
treating challenging occlusions.

CASE REPORT

Low-Profile Crossing and Stenting of a Long SFA Occlusion

BY MICHAEL LICHTENBERG, MD, FESC

A 78-year-old man with severe claudication of the right leg was admitted to our angiology department. Cardiac risk factors included poorly controlled diabetes and hyperlipoproteinemia. On duplex ultrasound, a long 30-cm occlusion of the superficial femoral artery (SFA) from the origin to the popliteal artery (PA) segment 1 was diagnosed. The mid- and distal PA exhibited no significant stenosis. The mid- and distal PA exhibited no significant stenosis. The posterior tibial artery was the only patent artery below the knee, as the anterior tibial artery showed a long occlusion from the proximal third of the vessel. Ankle-brachial index on the right side was 0.55. No wounds were present on the right extremity.

PROCEDURE

Subsequent diagnostic angiography confirmed the long SFA occlusion with diminished contrast flow below the knee and into the foot (Figure 1). For recanalization of the long SFA occlusion, a crossover approach from the left groin over the bifurcation was performed using a 6-F crossover Fortress® reinforced introducer sheath (BIOTRONIK). The flush occlusion of the SFA (Figure 2) was penetrated with an 0.018-inch guidewire and a Carnelian® Support 18 microcatheter (BIOTRONIK). The Carnelian Support microcatheter family has a low tip profile of 1.6* or 1.8 F to enable crossing of chronic total occlusions.¹ It provides a smooth transition from the soft distal tip, allowing trackability to the stiffer proximal part that ensures

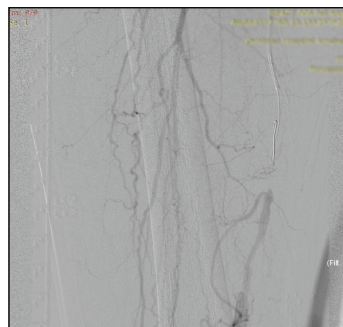


Figure 2. The flush occlusion was crossed using a guidewire and Carnelian Support 18 microcatheter.

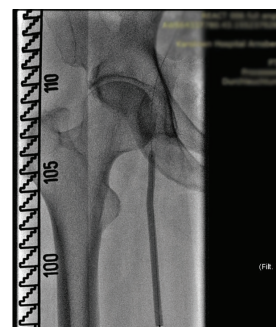


Figure 3. Balloon angioplasty of the lesion.

additional push. Using Carnelian Support to support the guidewire in this case made it easy to achieve distal reentry into the true lumen. Next, a 3-minute lesion preparation was performed with a 5- X 200-mm Passeo®-18 angioplasty balloon (BIOTRONIK) inflated to 10 atm over the entire length of the target lesion, followed by 6-mm-diameter Passeo®-18 Lux™ drug-coated balloons (BIOTRONIK) with 2-minute inflations over the length of the lesion (Figure 3). Subsequent angiographic analysis revealed a persistent long type C dissection after lesion treatment. On-table Doppler ultrasound showed a significant increase of flow velocity (250 cm/sec) within the first 150 mm of the target lesion. Following the REACT™ (REsponse Adapted Combination

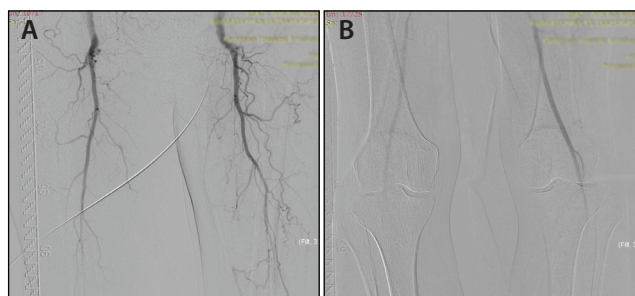

Figure 1. Diagnostic angiography showing a long SFA occlusion (A) and diminished contrast flow (B).

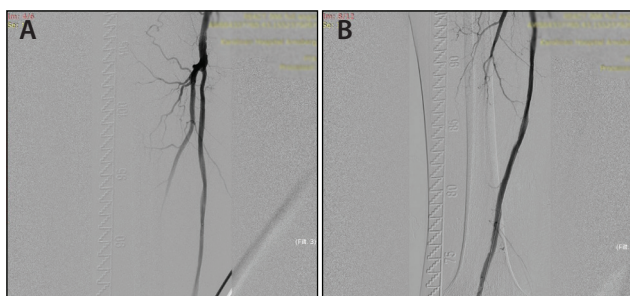


Figure 4. Due to a type C dissection, it was decided to place a Pulsar-18 T3 self-expanding stent (A, B).

*Indicated for below-the-ankle treatment.

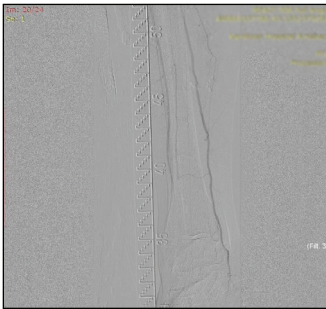

Figure 5. The final result showing flow into the foot via the patent posterior tibial artery.

Therapy) treatment concept, it was decided to proceed with bailout stent implantation using the new triaxial, 4-F Pulsar®-18 T3 nitinol self-expanding stent system (6 X 150 mm; BIOTRONIK; Figure 4).²

The decision to implant a Pulsar-18 T3 nitinol stent was supported by the encouraging outcome data of the PEACE and

other trials, which showed low target lesion revascularization rates even after complex lesion interventions with the Pulsar nitinol stent.^{3-6†}

RESULTS

After implantation of the Pulsar-18 T3 stent and postdilatation, a brisk flow was seen within the whole length of the target and there was a straight flow into the foot via the patent posterior tibial artery (Figure 5). Follow-up

examination of the patient the next day showed an ankle-brachial index of 0.9 on the right side and a significant improvement in pain-free walking distance, with no pain in the target limb on the treadmill test after 500 meters. ■

1. Tokai Medical Products, Inc. data on file.
2. BIO RResponse Adapted Combination Therapy Pilot Study. Clinicaltrials.gov website. <https://clinicaltrials.gov/ct2/show/NCT03547986>. Accessed March 2, 2020.
3. Lichtenberg M, Breuckmann F, Kramer V, et al. Effectiveness of the Pulsar-18 self-expanding stent with optional drug-coated balloon angioplasty in the treatment of femoropopliteal lesions—the BIOFLEX PEACE all-comers registry. *Vasa*. 2019;48:425-432.
4. Lichtenberg M, Kolks O, Hailer B, et al. PEACE I all-comers registry: patency evaluation after implantation of the 4-French Pulsar-18 self-expanding nitinol stent in femoropopliteal lesions. *J Endovasc Ther*. 2014;21:373-380.
5. Deloche K. 4EVER 24m: Long-term results of 4F Pulsar stents in femoropopliteal lesions. Presented at: Leipzig Interventional Course (LINC); January 29, 2014; Leipzig, Germany.
6. Lichtenberg M. Superficial femoral artery TASC D registry: 12-month effectiveness analysis of the Pulsar-18 SE nitinol stent in patients with critical limb ischemia. *J Cardiovasc Surg (Torino)*. 2013;54:433-439.

†Clinical data obtained with Pulsar-18, a predecessor of Pulsar-18 T3 that uses the same stent.

Michael Lichtenberg, MD, FESC

Arnsberg Vascular Center

Arnsberg, Germany

klichte@gmx.net

Disclosures: Honoraria for lecturing, advisory board, and research from BIOTRONIK.

CASE REPORT

Retrograde Approach for a Long Occlusion of the Anterior Tibial Artery

BY ROBERTO FERRARESI, MD

A 72-year-old man with diabetes presented with gangrene of the third toe in the right foot and rest pain. The baseline angiographic study showed patency of the femoropopliteal arteries and extensive disease of the infrapopliteal arteries (Figure 1). The anterior tibial artery (ATA), posterior tibial artery, and plantar arteries were occluded, and the peroneal artery had multiple focal stenoses. The dorsalis pedis artery (DPA) was the only patent artery of the foot, and there was diffuse small artery disease. The aim of the procedure was to restore a direct flow line to the forefoot, and the only possible target was the DPA.

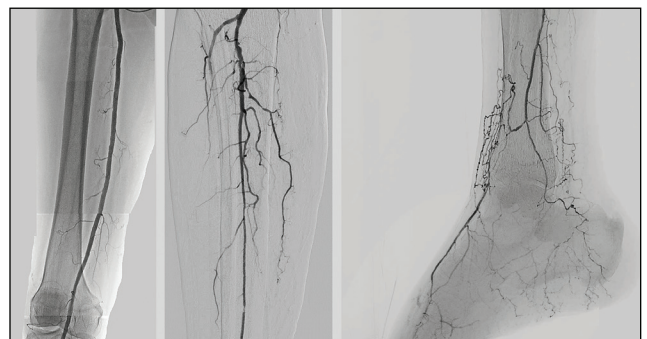


Figure 1. Baseline angiography.

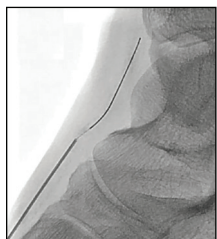


Figure 2. Retrograde puncture of the DPA.

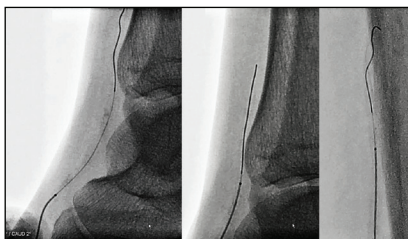


Figure 3. Advancement of the Carnelian Support 14 microcatheter.

PROCEDURE

The procedure was performed via an ipsilateral 4-F antegrade femoral approach. After simple balloon dilatation of the distal peroneal artery, we tried an antegrade endoluminal approach of the ATA with an 0.014-inch guidewire. At the distal third of the ATA, it was impossible to progress, and we shifted to a retrograde approach (Figure 2). When there is a calcified DPA, we use a 30° to 45° contralateral oblique projection in which the artery is separated from the bones, easily visualized, and pierced with a 21-gauge needle. After retrograde wiring of the DPA with a 0.014-inch guidewire, the use of a support catheter is essential. The Carnelian® Support 14 microcatheter (BIOTRONIK) easily crossed the heavily calcified DPA and supported the wire (Figure 3). Through the catheter, we exchanged wires to one with a heavier tip load in order to perform retrograde crossing of the hard, occluded vessel segments and achieve the rendezvous

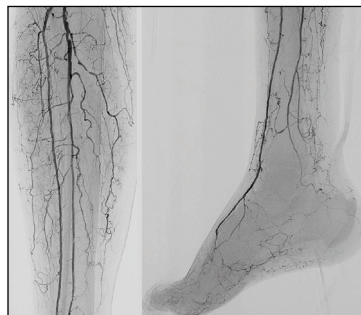


Figure 4. Final angiographic result.

with the antegrade approach. Balloon dilatation was performed.

RESULTS

The final angiographic result demonstrated patency of the previously occluded vessel (Figure 4). The

patient was submitted to third toe amputation and healed in 7 weeks.

An antegrade recanalization approach can fail in up to 20% of cases.¹ Retrograde approaches can favorably modify this failure rate. Support catheters with high trackability represent an essential tool for successful retrograde crossing. ■

1. Montero-Baker M, Schmidt A, Bräunlich S, et al. Retrograde approach for complex popliteal and tibioperoneal occlusions. *J Endovasc Ther.* 2008;15:594-604.

Roberto Ferraresi, MD

Scientific Director, Diabetic Foot Clinic
Clinica San Carlo
Paderno Dugnano, Milan, Italy
Disclosures: Consultant for BIOTRONIK.

CASE REPORT

4-F Treatment of Multiple SFA and BTK Stenoses in a Patient With Recurrent CLI

BY LUIS MARIANO PALENA, MD, AND MARCO MANZI, MD

A 77-year-old man presented to our institution with recurrent critical limb ischemia (CLI). He had diabetes, hypertension, dyslipidemia, and chronic renal failure (creatinine, 1.5 mg/dL) and had undergone a previous transmetatarsal amputation that was not healing. Imaging revealed multiple stenoses in the superficial femoral artery (SFA), including a

medium occlusion in the distal SFA, heavy calcification, and a Texas University class 3D lesion in the previous amputation (Figure 1). The pedal artery and tarsal branch were identified, but there was no direct outflow to the foot. There was occlusion of the anterior and posterior tibial arteries, with only one-vessel runoff (the peroneal artery).

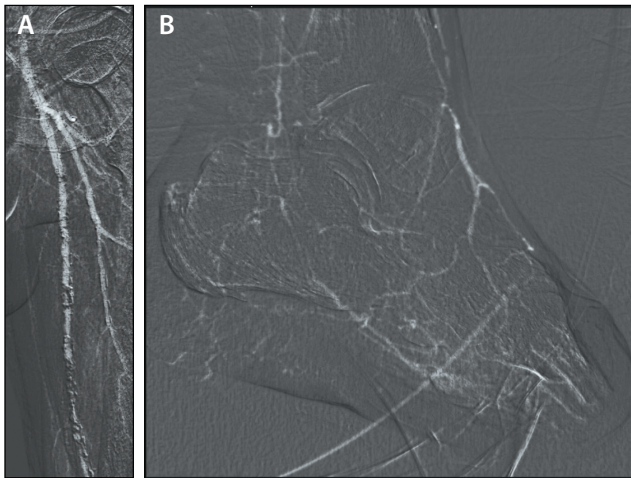


Figure 1. Multiple lesions were identified in the SFA, as well as occlusion of the anterior and posterior tibial arteries (A), and a Texas University class 3D lesion in the previous amputation (B).

PROCEDURE

Antegrade access was achieved via the common femoral artery. Balloon angioplasty was performed using a 5- X 200-mm semicompliant balloon with a prolonged inflation and increased pressure after 1 or 2 minutes, followed by a 6- X 200-mm balloon. This allowed opening of the artery, but there was recoiling, and due to the calcification, much of the plaque remained unmodified. To fix the dissections and improve the recoiling it was decided to place three Pulsar®-18 T3 nitinol self-expanding stents (BIOTRONIK) because of the 4-F low-profile, low metal burden, and precise triaxial deployment system. First, we placed a 7- X 150-mm stent to save the collateral, and it was very well expanded. A second 7- X 150-mm stent was placed to cover the proximal plaque before a final 7- X 100-mm stent. After postdilatation, there was a very good result, and even in the curved area of the vessel, the

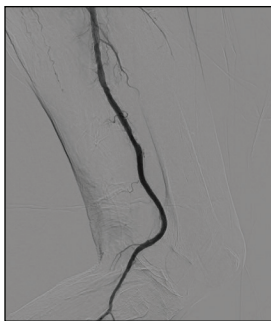

Figure 2. Three Pulsar-18 T3 stents were placed in the SFA and proximal popliteal artery, which performed very well even with flexion of the knee.

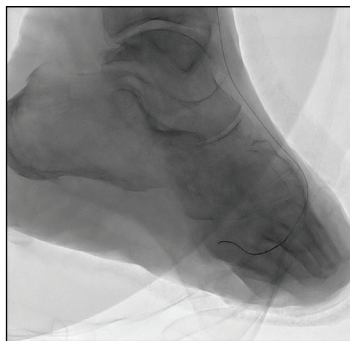

Figure 3. Engagement of the arch using the Carnelian Support 14 microcatheter.

stent performed well (Figure 2).

A 4-F catheter was deployed with an 0.018-inch V-18 ControlWire guidewire (Boston Scientific Corporation) to cross the anterior tibial artery and reach the foot, but it was challenging to

arrive in the arch because of the diseased pedal artery. The wire was exchanged for a 0.014-inch Hi-Torque Command guidewire (Abbott), and the Carnelian® Support 14 microcatheter (BIOTRONIK) was then used to easily reach the partially occluded arch and engage the lateral plantar artery (Figure 3). Predilatation was performed with a 2- X 40-mm balloon to open up multiple stenoses in the arch, followed by dilatation with a 2.5- X 220-mm balloon of the pedal arteries and anterior tibial artery. Finally, another 2- X 40-mm balloon was used to open residual stenosis in the distal dorsalis pedis and improve the lateral plantar artery.

RESULTS

Final angiography demonstrated good inflow and outflow (Figure 4). Perfusion was restored with very nice flow to the forefoot to allow healing of the transmetatarsal amputation and clear blush to the calcaneal region.

For patients with CLI, it is not usually enough to open the SFA to guarantee lesion healing. In this case, it was necessary to fix the recoiling with stenting, which achieved a perfect result. ■

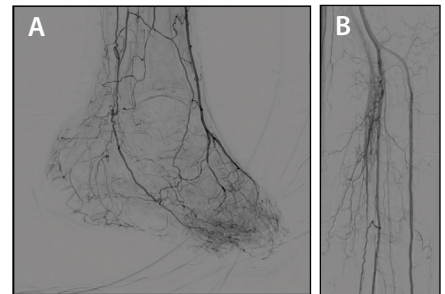


Figure 4. Final result showed antegrade flow in the plantar artery and distal posterior (A) and fast flow in the anterior tibial artery (B).

Luis Mariano Palena, MD

Director, Endovascular Surgery Unit
Endovascular Interventions & Research
Director, CLI Therapy Fellowship Program
Maria Cecilia Hospital – GVM Care & Research
Cotignola, Italy
Disclosures: Receives honoraria from BIOTRONIK.

Marco Manzi, MD

Interventional Radiology Unit
Foot & Ankle Clinic
Policlinico Abano Terme
Abano Terme (PD), Italy
Disclosures: Receives honoraria from BIOTRONIK.

CASE REPORT

Revascularizing BTK Occlusions Using the Carnelian Support Microcatheter

BY JOS C. VAN DEN BERG, MD, PhD

A 77-year-old woman was referred to our vascular center for atypical rest pain in both legs (the left side was more severe than the right side). Her medical history revealed atrial fibrillation, arterial hypertension, stage 2 to 3 chronic renal insufficiency, and rheumatoid and psoriatic arthritis. The patient reported a failed attempt of revascularization of the left side in another hospital. MRA performed in the other hospital (not shown) demonstrated an occlusion of the superficial femoral artery (SFA), the popliteal artery, and all proximal segments of all three below-the-knee (BTK) arteries on the left side. On the right side, the SFA and popliteal artery were patent. The posterior and anterior tibial arteries were occluded, with a single-vessel outflow on the fibular artery.

Given the more severe symptoms on the left side, a revascularization procedure of the left SFA, popliteal artery, and BTK arteries in an ambulatory setting was planned and completed successfully with immediate relief of the rest pain. Given the good clinical outcome on the left

side, an ambulatory revascularization procedure of the right lower leg was planned.

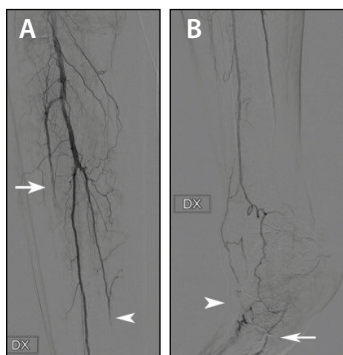


Figure 1. Digital subtraction angiography (DSA) of the proximal right lower leg demonstrating an occlusion of the anterior tibial artery (arrow) and posterior tibial artery (arrowhead; A). DSA of the distal lower leg and foot demonstrating flow in a small-caliber dorsalis pedis artery (arrowhead) and the lateral plantar artery (arrow; B).

plantar artery and a small dorsalis pedis artery (Figure 1). Attempts to cross the occlusion of the posterior and anterior tibial arteries were unsuccessful.

Subsequently, selective angiography of the fibular artery was performed, demonstrating a small anterior collateral branch connecting to the dorsalis pedis and a large posterior collateral branch (with a corkscrew appearance proximally) with a connection to the lateral

plantar artery (Figure 2).

Selective cannulation of the fibular artery with a 4-F multipurpose diagnostic catheter was performed. A 0.014-inch Glidewire Advantage guidewire (Terumo Interventional Systems) was advanced into the distal fibular artery, and the diagnostic catheter was exchanged for a Carnelian® Support BTA microcatheter (BIOTRONIK). It was not possible to advance the guidewire through the tortuous corkscrew segment (Figure 3A), so an exchange was made for a 0.014-inch Glidewire GT guidewire (Terumo Interventional Systems). The latter navigated without issue through the tortuous segment (Figure 3B) into the lateral plantar artery, and the Carnelian Support catheter was advanced over the guidewire into the lateral plantar artery toward the distal posterior tibial artery. It was not possible to advance the Glidewire GT guidewire toward the distal posterior tibial artery, and therefore an exchange was made for a 0.014-inch Hi-Torque Command guidewire (Abbott), leaving the Carnelian Support catheter in place.

After formation of a loop in the tip of the Hi-Torque Command guidewire, it was possible to cross the occlusion

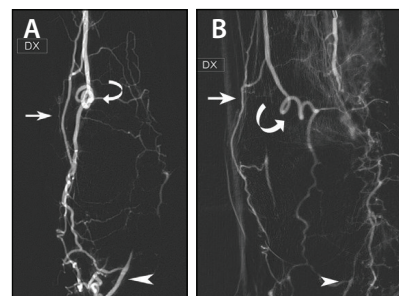


Figure 2. Roadmap image in antero-posterior (A) and oblique view (B) of the right foot obtained with selective injection of the fibular artery showing the anterior branch toward the dorsalis pedis artery (arrow), and posterior collateral (with corkscrew appearance; curved arrow) toward the lateral plantar artery (arrowhead).

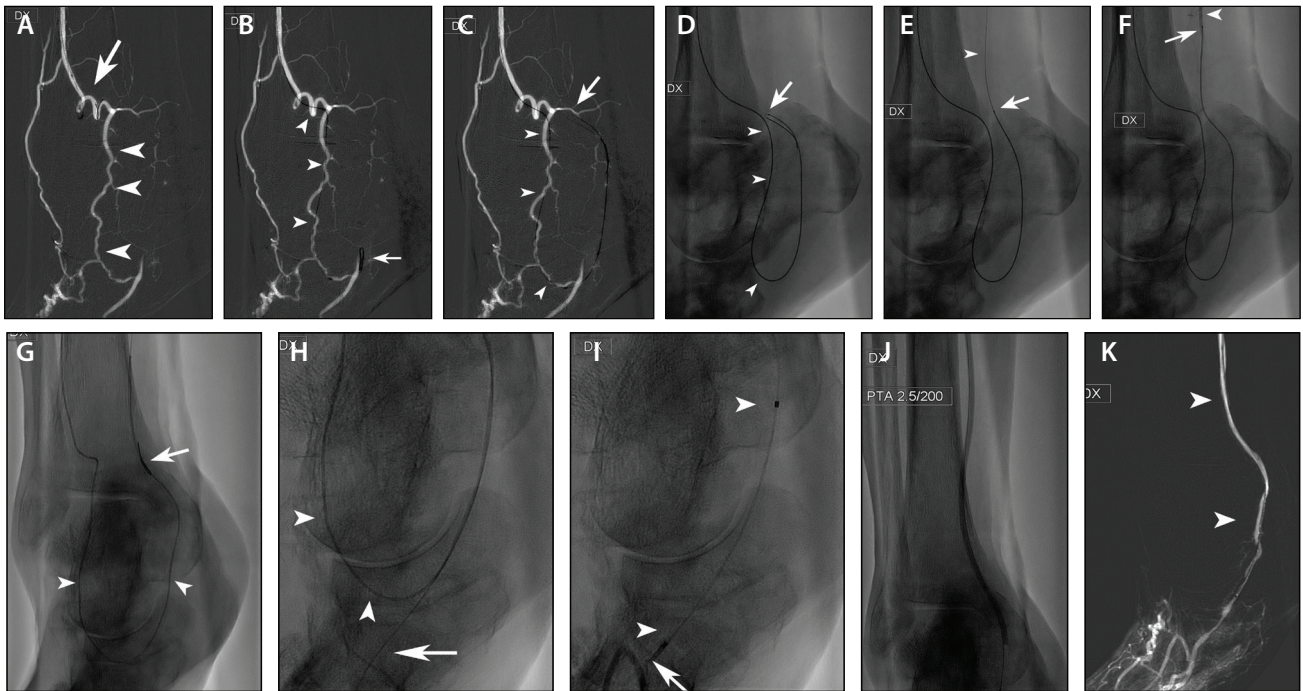


Figure 3. Roadmap image in oblique view demonstrating the distal course of the collateral (arrowheads); the 0.014-inch guidewire advanced through the Carnelian Support microcatheter into the proximal tortuous segment of the collateral (arrow; A). Roadmap image in oblique view after passage of the Carnelian Support microcatheter through the collateral, demonstrating straightening of the collateral (arrowheads) and the looped tip of the 0.014-inch guidewire in the lateral plantar artery (arrow; B). Roadmap image (C) and fluoroscopic image (D) in oblique view demonstrating the Carnelian Support microcatheter after further advancement over the Hi-Torque Command guidewire; the tip of the Carnelian Support can be seen at the level of the distal posterior tibial artery (arrow). Fluoroscopic image showing the tip of the Carnelian Support (arrow) and guidewire crossed into the proximal segment of the posterior tibial artery (arrowhead; E). Fluoroscopic image showing the tip of the Carnelian Support (arrow) and confirmation of intraluminal position after contrast injection (arrowhead; F). Fluoroscopic image showing the Carnelian Support in place (arrowheads) and an antegrade guidewire next to the distal segment of the Carnelian Support (arrow; G). Fluoroscopic image showing the Carnelian Support (arrowheads) and the antegrade guidewire (arrow) after crossing of the guidewire into the lateral plantar artery (H). Fluoroscopic image showing the angioplasty balloon catheter in the lateral plantar artery (arrowheads) and confirmation of intraluminal position with contrast injection (arrow; I). Fluoroscopic image of the inflated 2.5- X 200-mm angioplasty balloon (J). Control angiography showing patency of the posterior tibial artery and the lateral plantar artery (arrowheads; K).

in the distal posterior tibial artery and advance the Carnelian Support catheter into the patent segment of the posterior tibial artery (Figures 3C–3E). Intraluminal positioning of the catheter was confirmed (Figure 3F). The Carnelian Support catheter was left in place, and through the 4-F sheath, a second guidewire (0.014-inch Glidewire Advantage) was inserted in an antegrade fashion next to the Carnelian Support catheter and advanced into the distal segment of the posterior tibial artery (Figure 3G). Using the Carnelian Support catheter as a track, the guidewire was easily advanced in a looped fashion into the lateral plantar artery (Figure 3H). With the antegrade guidewire left in place, the Carnelian Support catheter was withdrawn, an angioplasty balloon was advanced over the antegrade guidewire, and intraluminal positioning in the lateral plantar artery was confirmed (Figure 3I). Percutaneous transluminal angioplasty of the posterior tibial artery was performed using a 2.5- X 200-mm angioplasty balloon (Figure 3J).

RESULTS

Control angiography demonstrated reconstitution of antegrade flow into the lateral plantar artery (Figure 3K) with a triphasic Doppler signal. Hemostasis was obtained with manual compression. The patient was discharged the same day and became fully asymptomatic. ■

Jos C. van den Berg, MD, PhD

Centro Vascolare Ticino
Ospedale Regionale di Lugano, sede Civico
Lugano, Switzerland
Inselspital, Universitätsspital Bern
Universitätsinstitut für Diagnostische, Interventionelle
und Pädiatrische Radiologie
Bern, Switzerland

Disclosures: Consultant for BIOTRONIK.

Pulsar[®]-18 T3

Self-Expanding Stent System

A unique combination
of 3 technologies



4F

Low profile
delivery system

**Smaller puncture
site area**

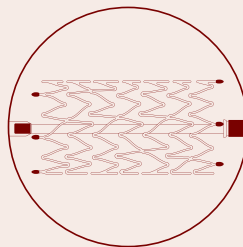
45%

Smaller puncture
site area vs. 6F¹



Tri-axial system
with braided shaft

**Accurate stent
deployment**



Thin struts,
low COF

**Lower risk
of restenosis^{*,2}**

89.3%

24-m FTLR
BIOFLEX PEACE³

* As demonstrated in pre-clinical studies
using comparable stents.



Easy to use, ergonomically
designed handle.

1. BIOTRONIK data on file; 2. Zhao HQ. Late stent expansion and neointimal proliferation of oversized nitinol stents in peripheral arteries. Cardiovasc Intervent Radiol. 2009 Jul;32(4):720-6; 3. Lichtenberg et al. Effectiveness of the Pulsar-18 self-expanding stent with optional drug-coated balloon angioplasty in the treatment of femoropopliteal lesions – the BIOFLEX PEACE ALL-Comers Registry. Vasa [2019], 1-9. doi.10.1024/0301-1526a000785. FTLR for stent only group. Clinical data obtained with Pulsar-18, a predecessor of Pulsar-18 T3 using the same stent.

FTLR=Freedom from Target Lesion Revascularization; COF=Chronic Outward Force.
Pulsar is a trademark or registered trademark of the BIOTRONIK Group of Companies.

www.biotronik.com

© 2020 BIOTRONIK AG - All rights reserved.

Specifications are subject to modification, revision and improvement