



# THORACOABDOMINAL AORTIC ANEURYSMS

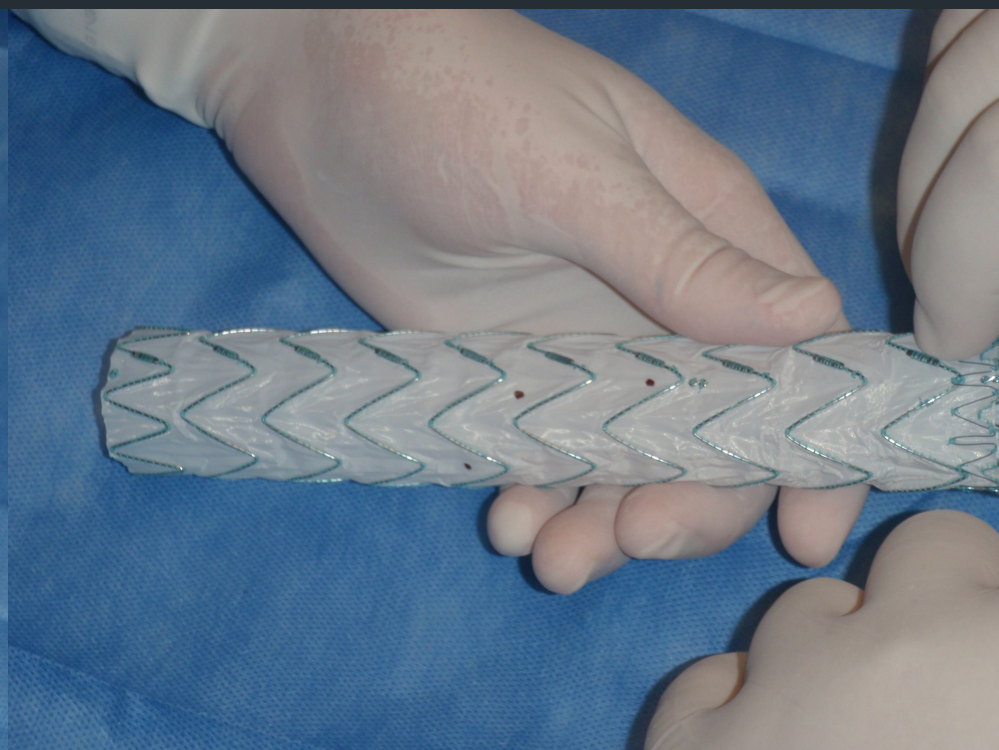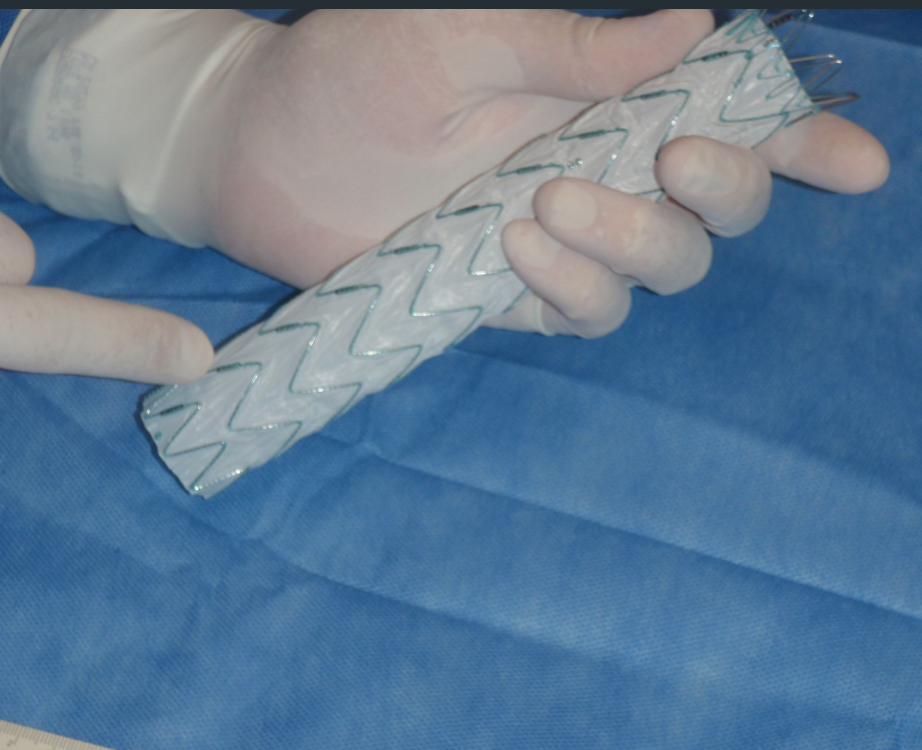Stentgraft with internal branches made by the  
surgeon – Cases

MARCO LOURENÇO

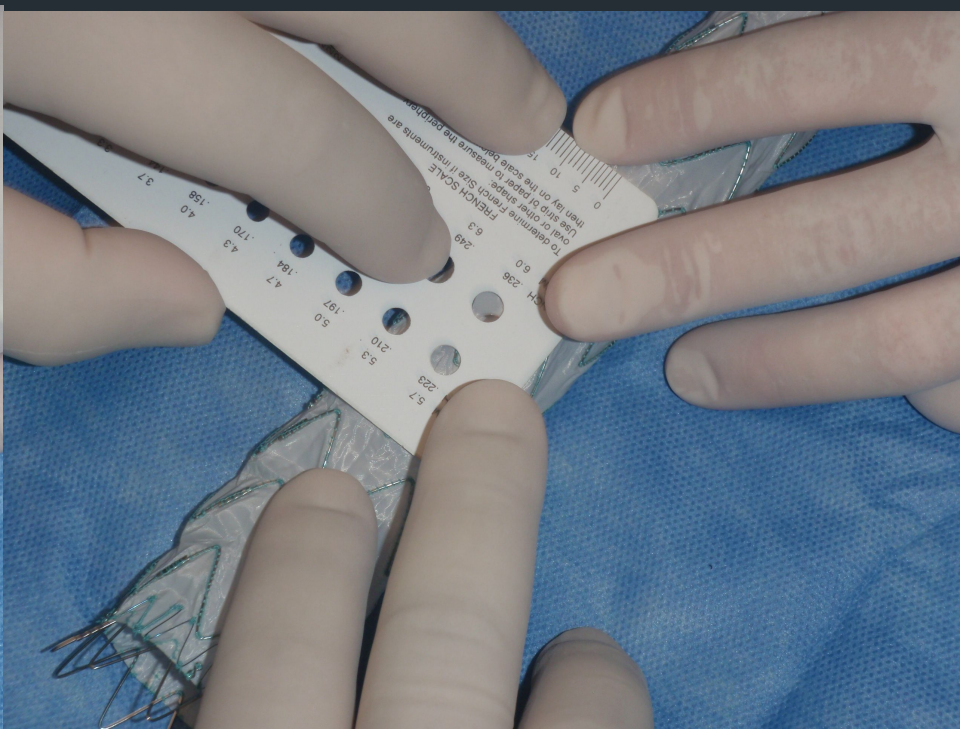
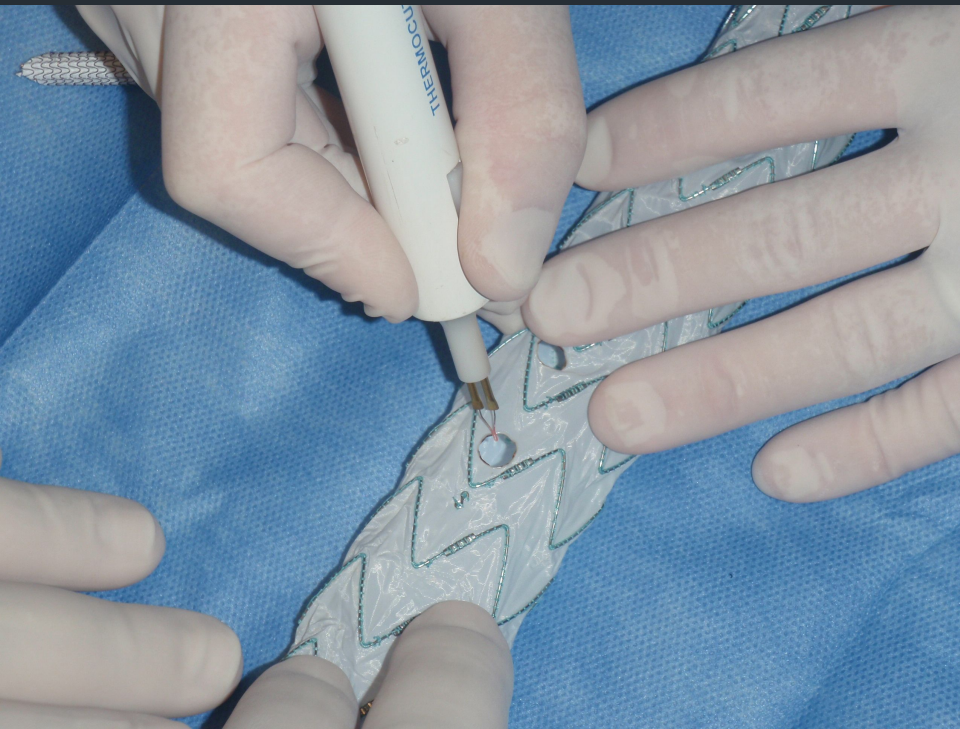
Joice Inglez, Rodrigo Gribosi, Jessica Prado

HOSPITAL SANTA CASA DE CURITIBA - PR

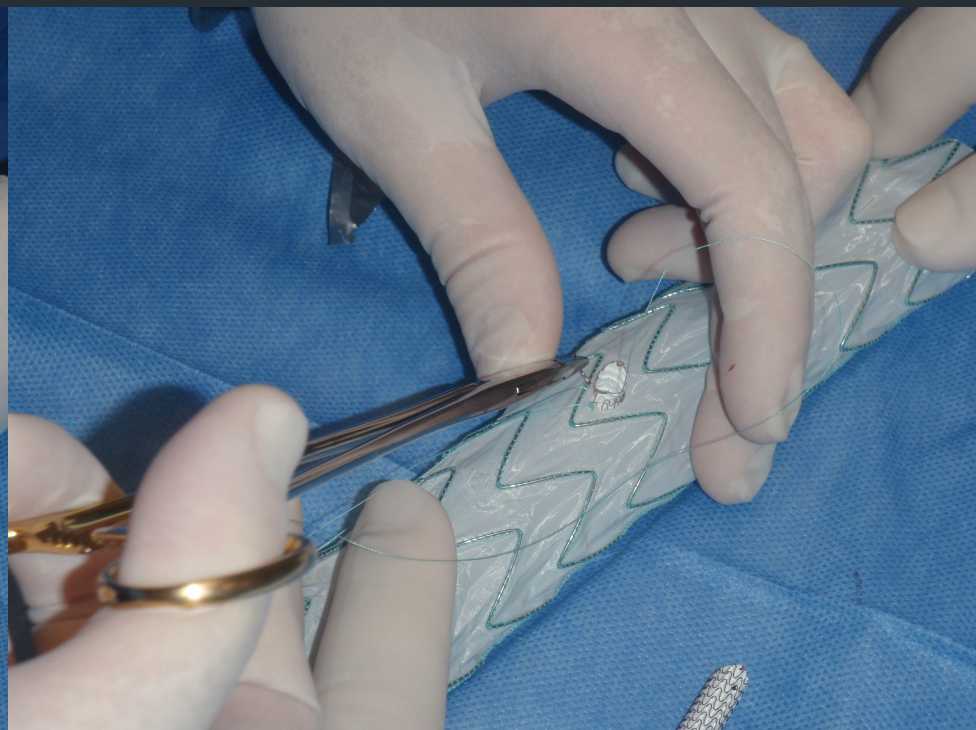
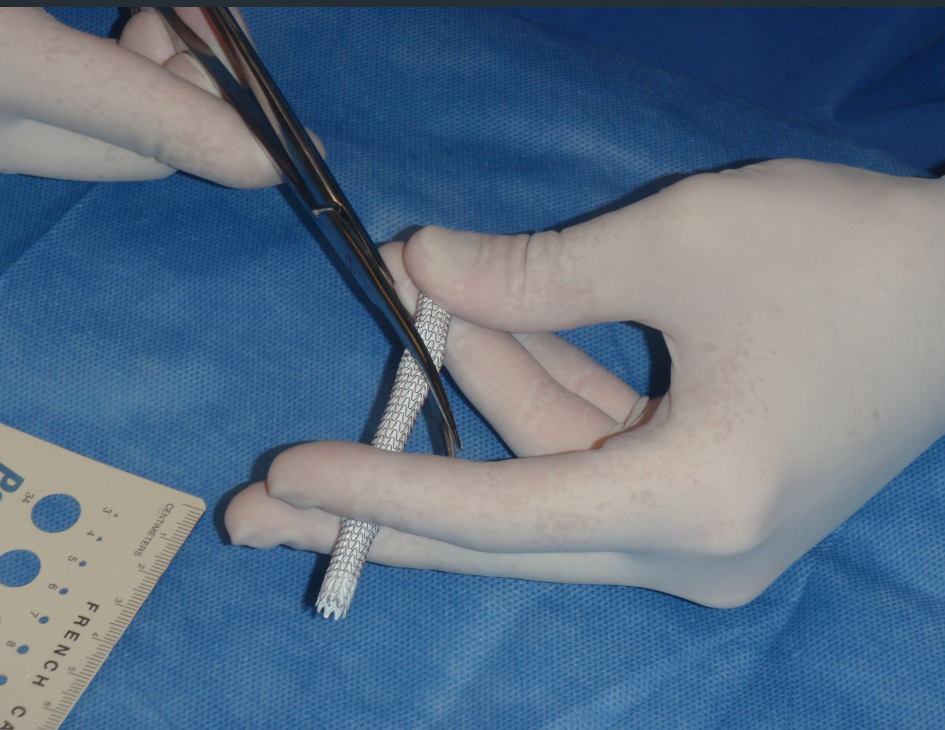
# CUSTOMIZATION



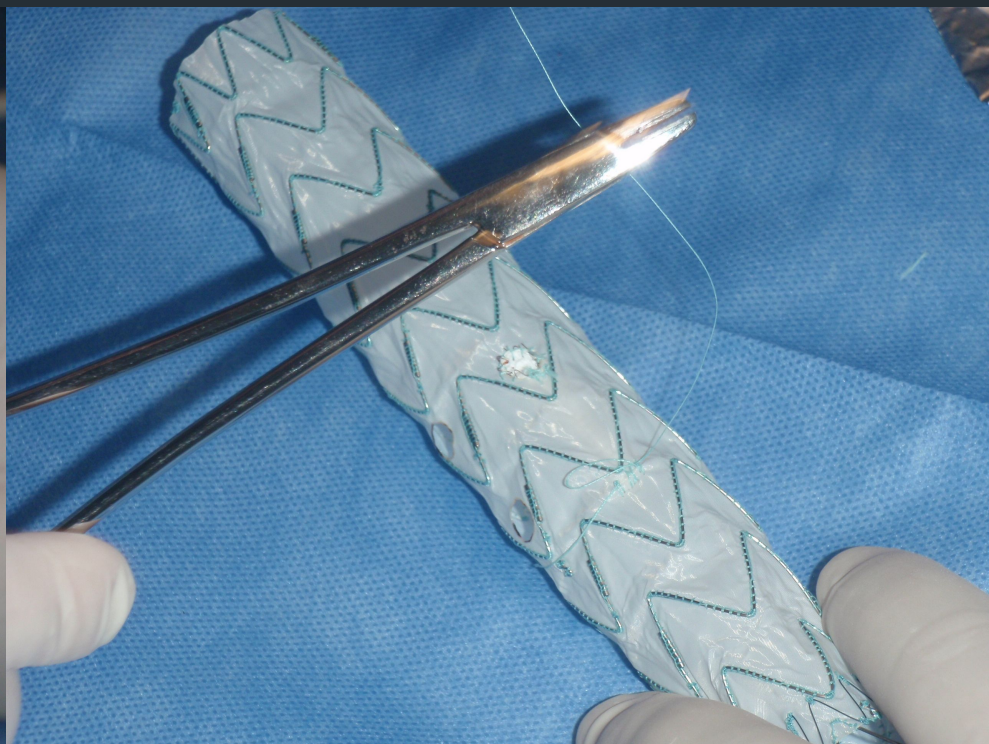
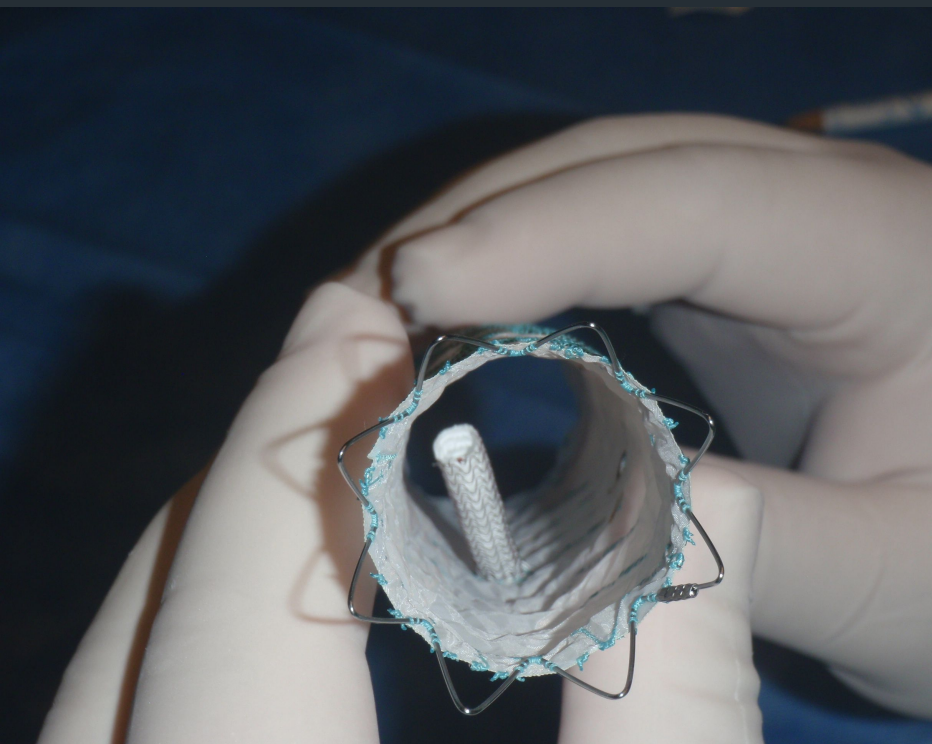
# CUSTOMIZATION



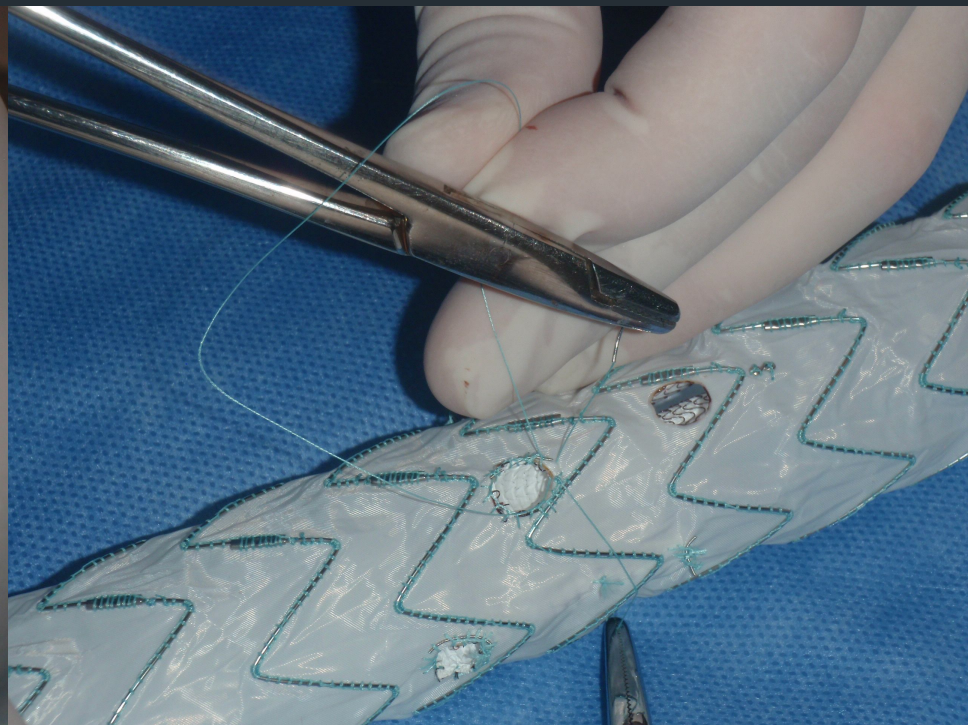
# CUSTOMIZATION



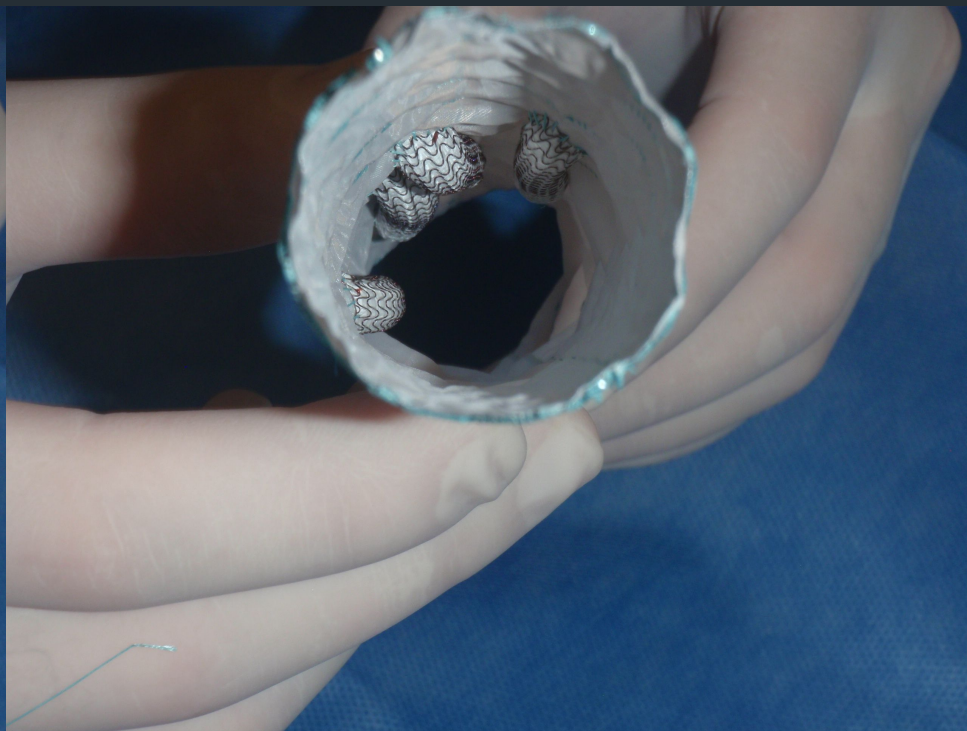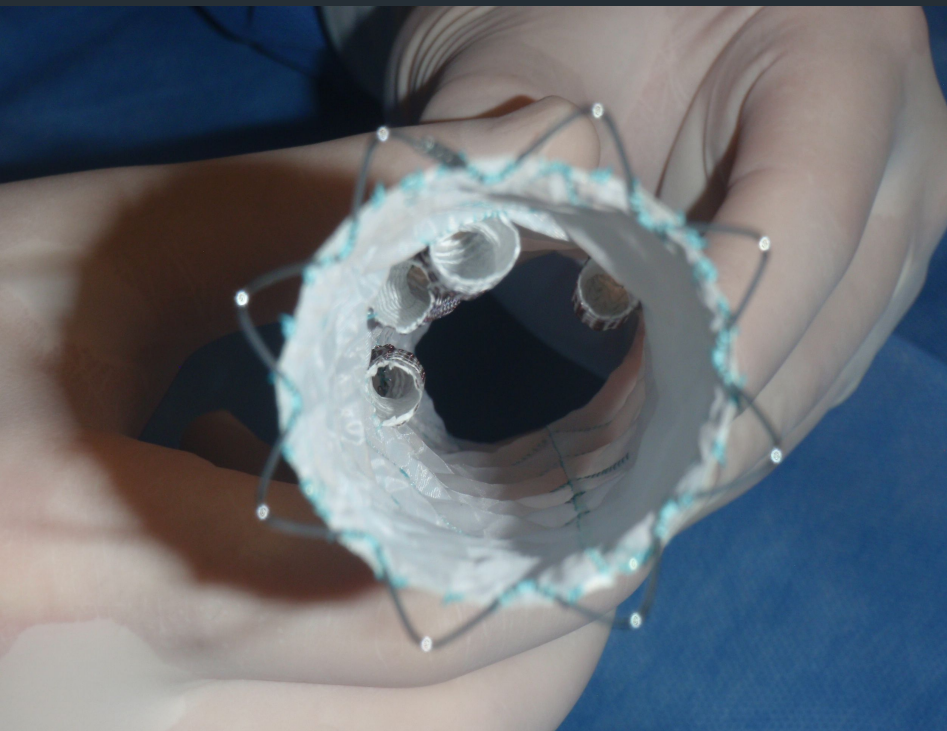
# CUSTOMIZATION



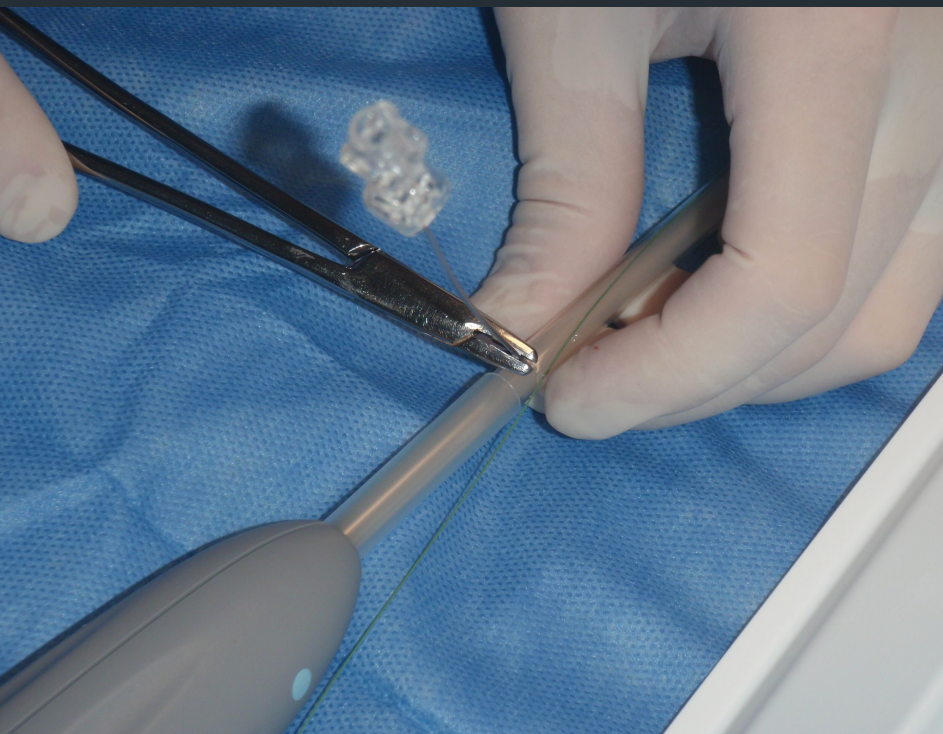
# CUSTOMIZATION



# CUSTOMIZATION



# CUSTOMIZATION

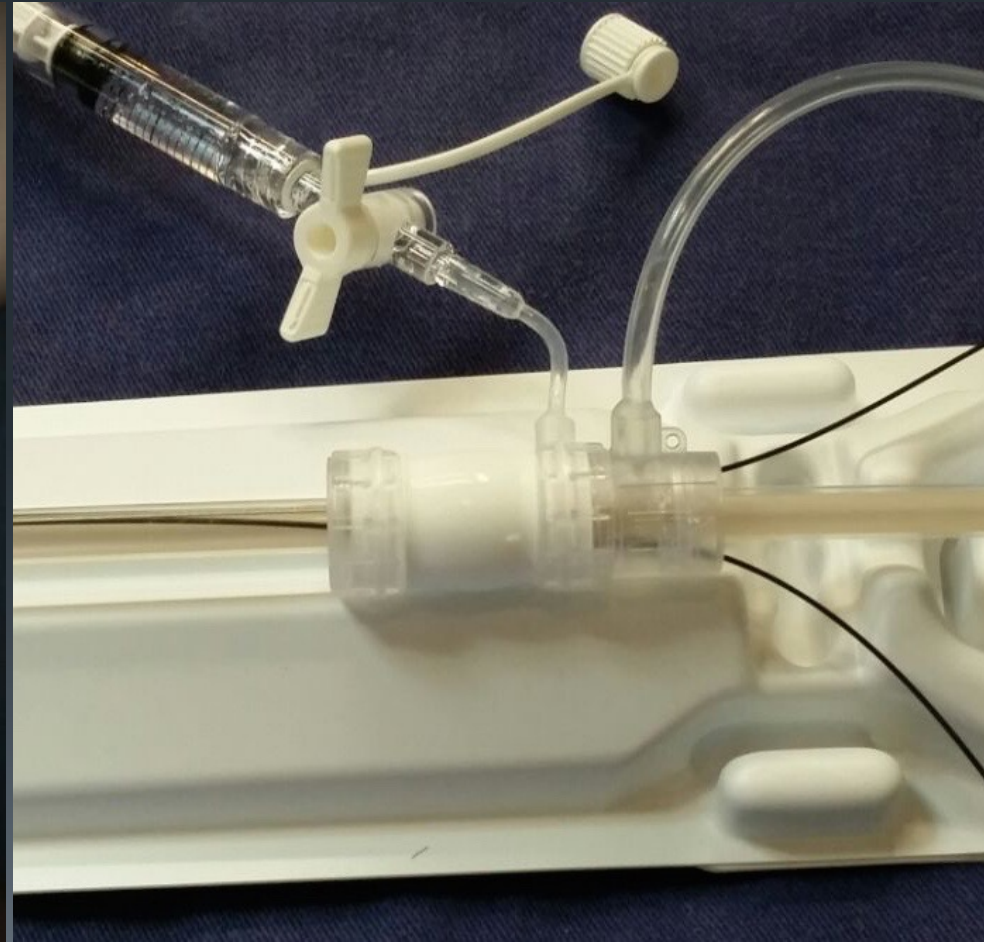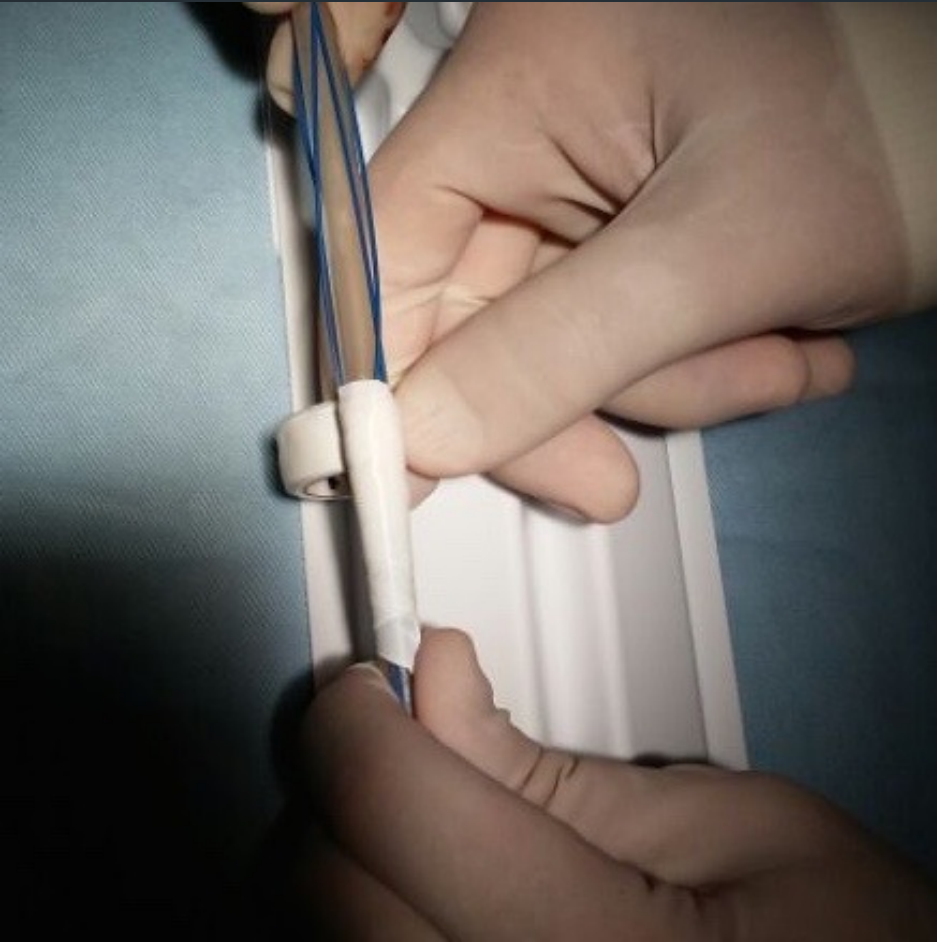




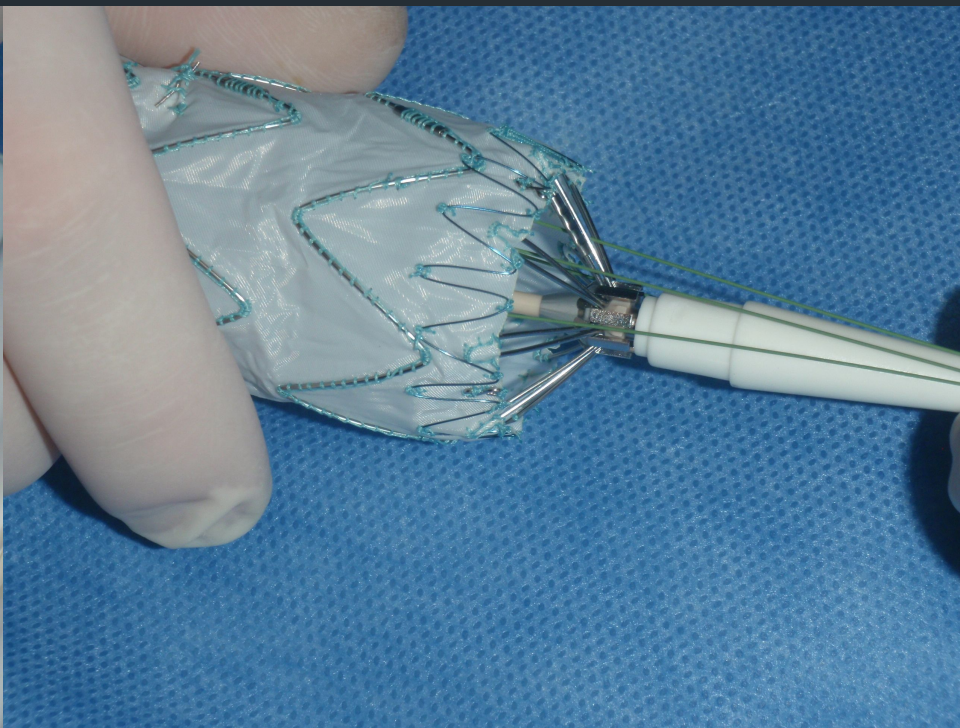
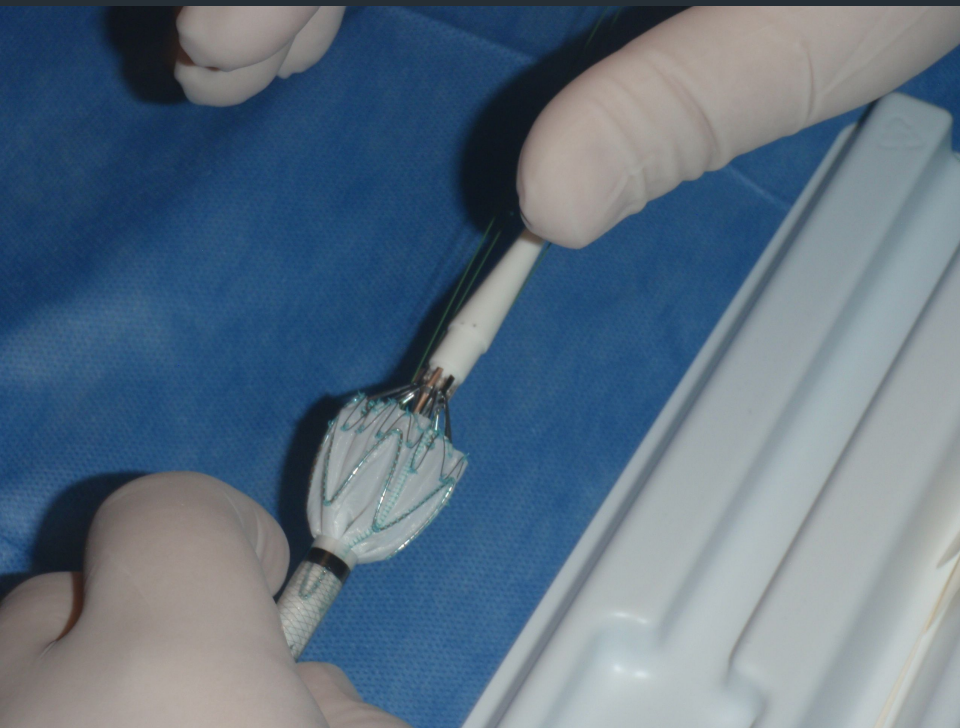# CUSTOMIZATION



CLOSING THE PUNCTURE



# CUSTOMIZATION





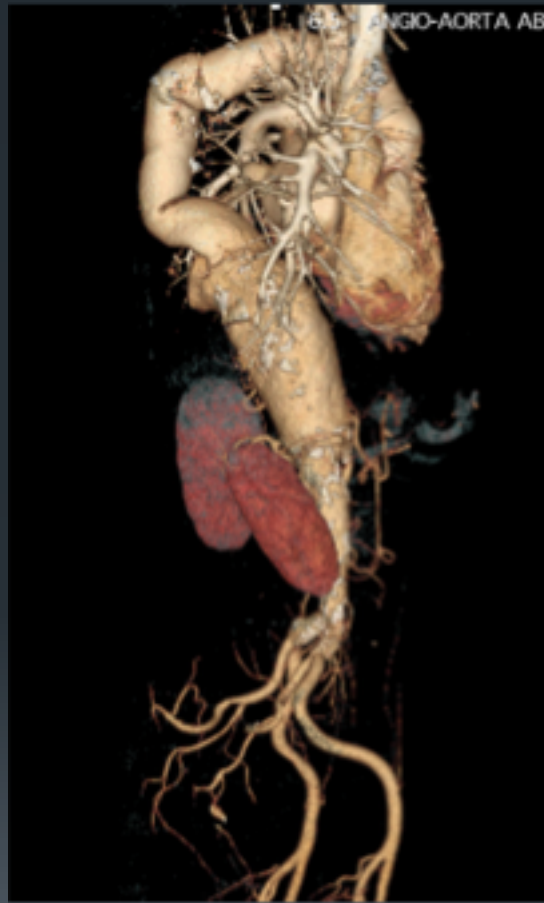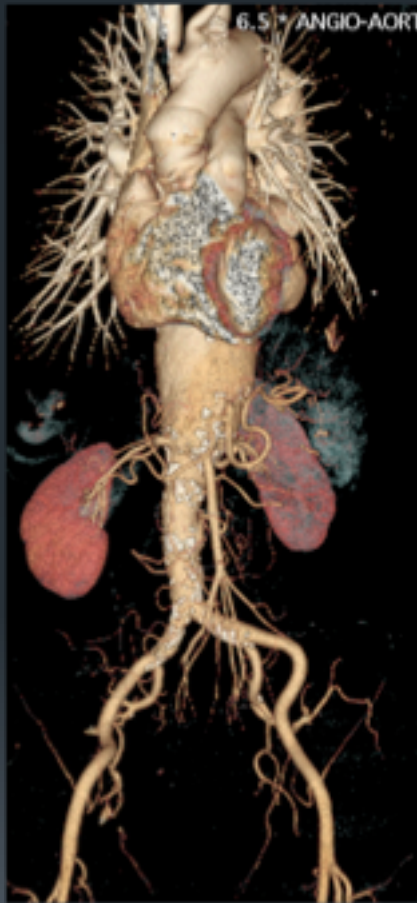# CASE 1

MALE

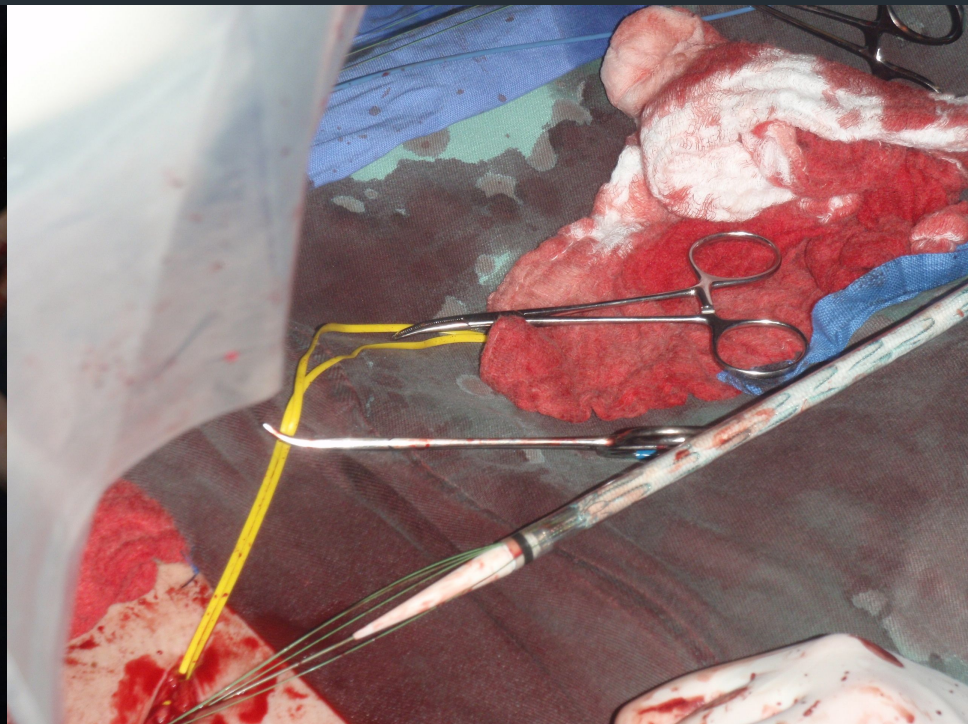
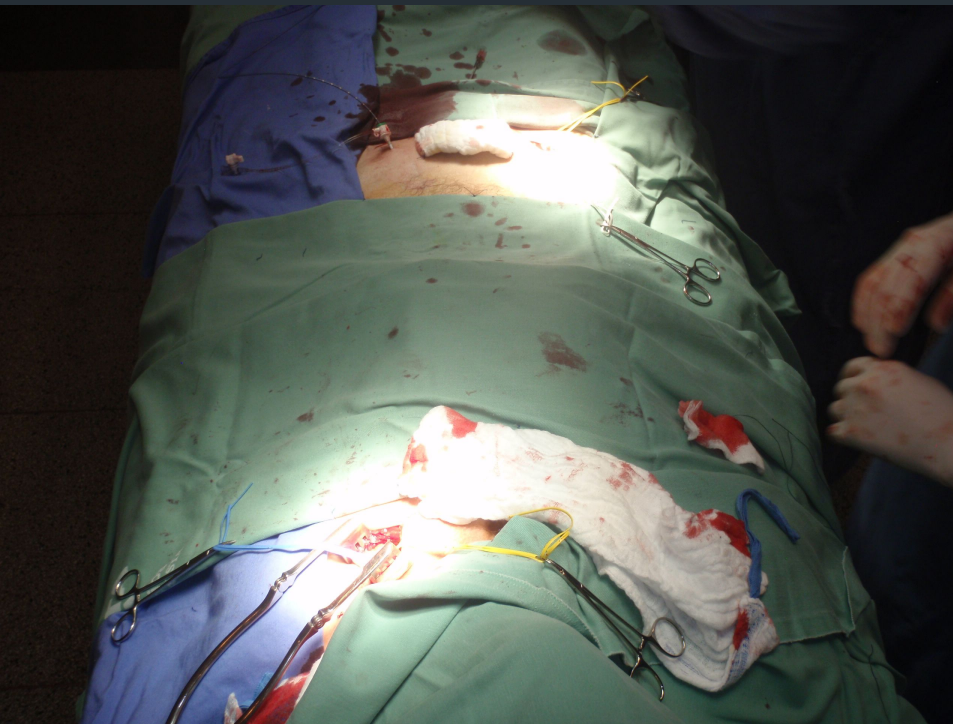
62 YEARS

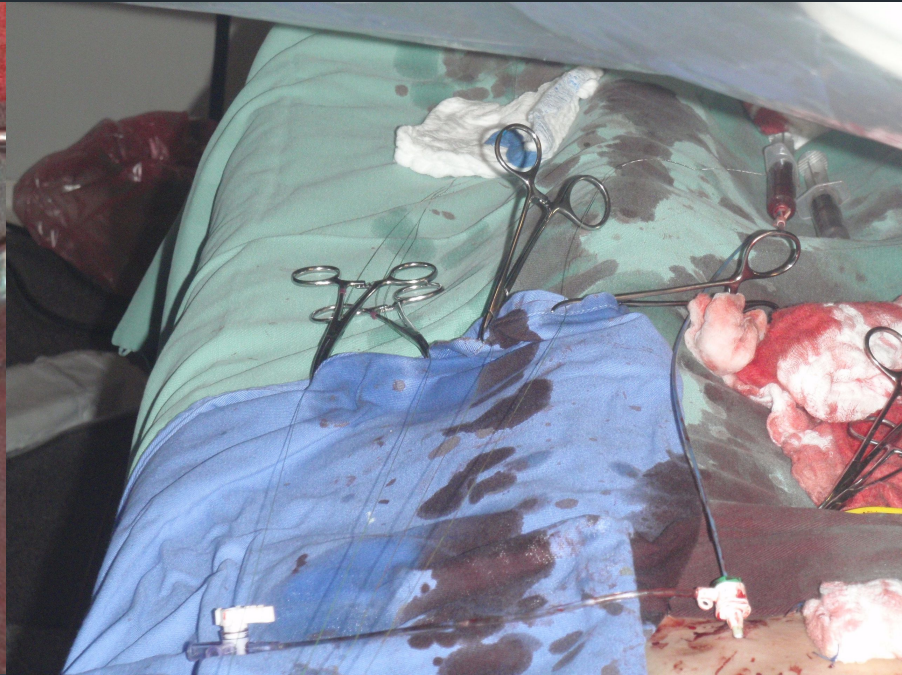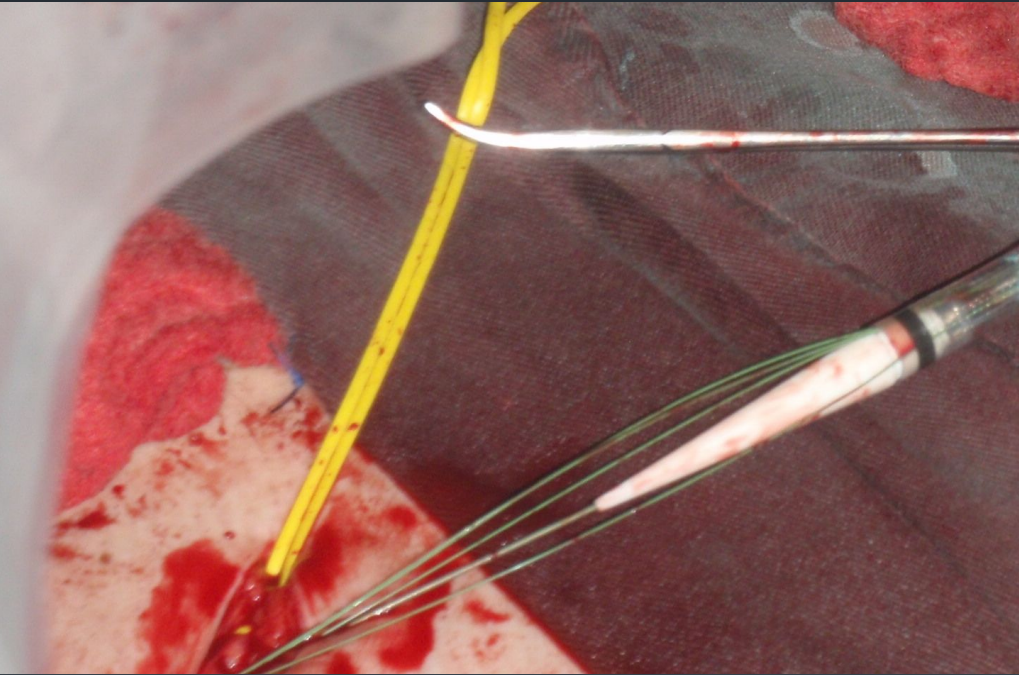
ATA TYPE III 70MM

# CASE 1



# PROCEDURE

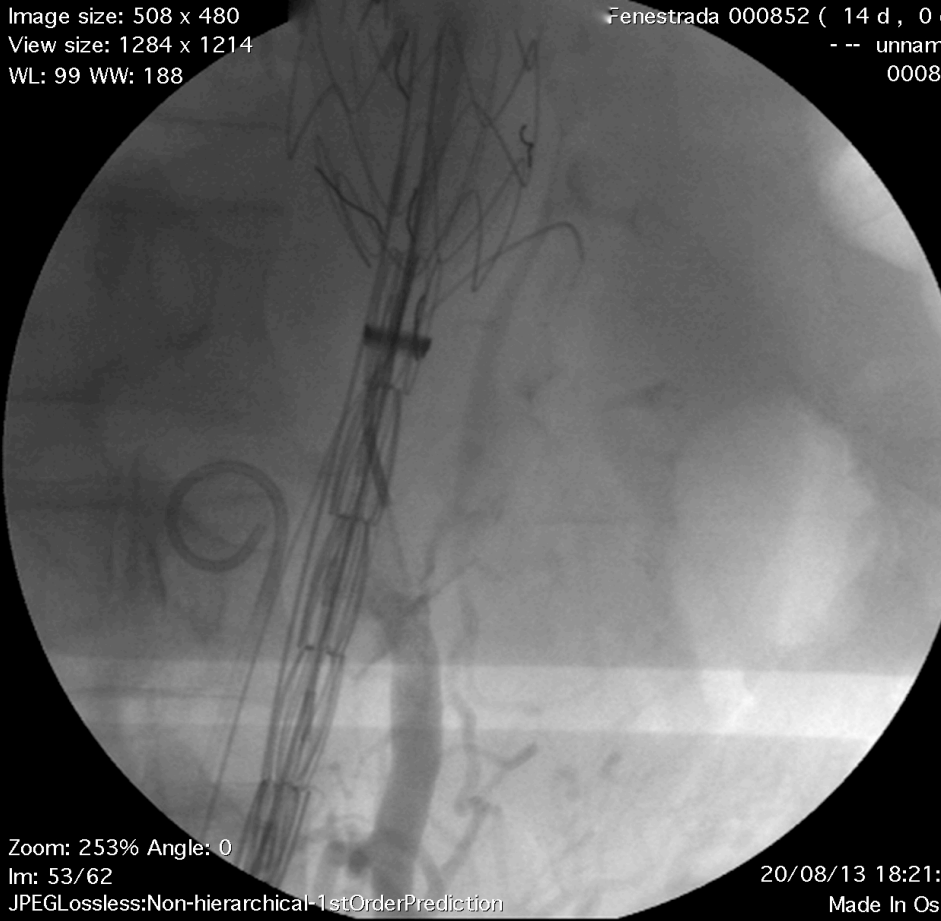



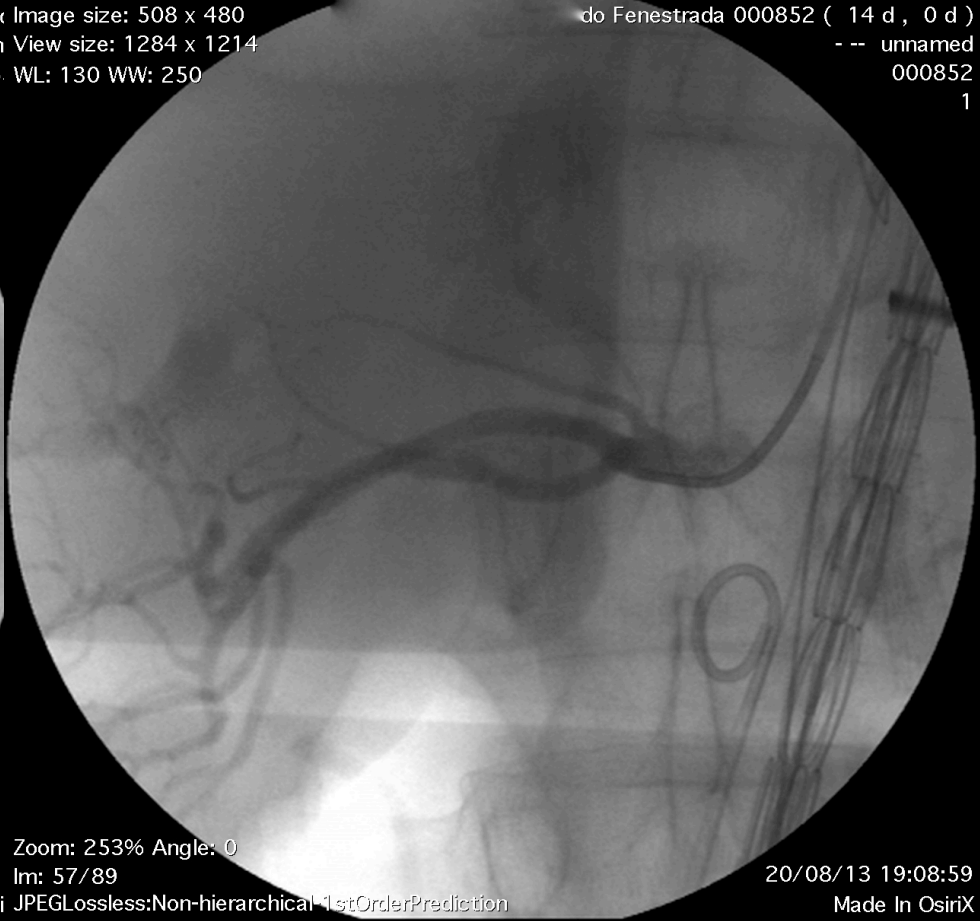
# GRADUAL OPENING STENTGRAFT



Image size: 508 x 480  
View size: 1284 x 1214  
WL: 99 WW: 188



Fenestrada 000852 ( 14 d , 0 r  
-- unnam View size: 1284 x 1214  
0008 WL: 130 WW: 250



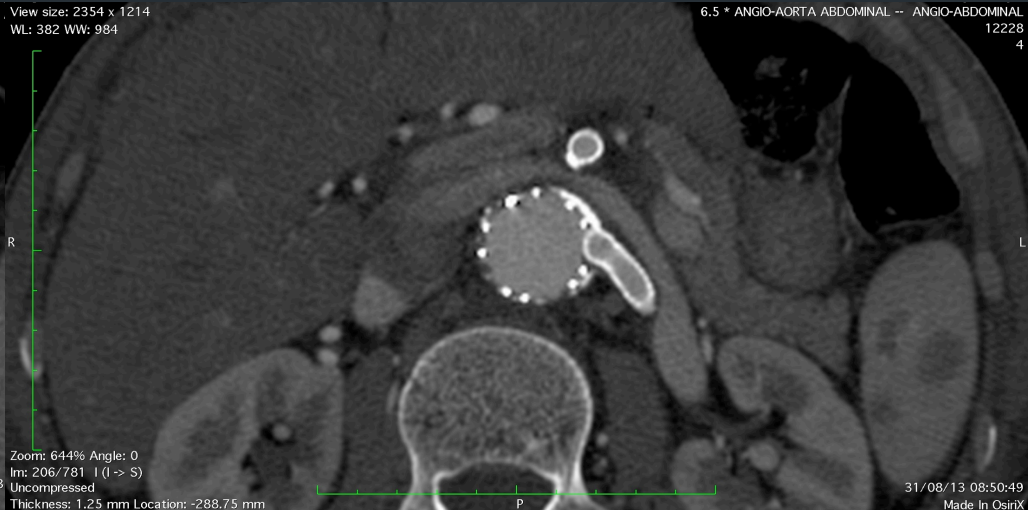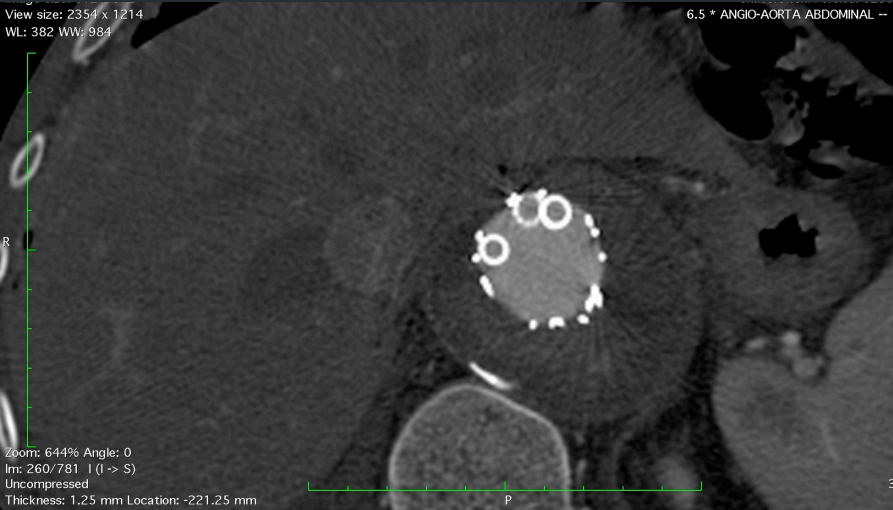do Fenestrada 000852 ( 14 d , 0 d )  
-- unnamed  
000852  
1

Zoom: 253% Angle: 0  
Im: 53/62  
JPEGLossless:Non-hierarchical-1stOrderPrediction

20/08/13 18:21: Im: 57/89  
Made In Osir JPEGLossless:Non-hierarchical-1stOrderPrediction

Zoom: 253% Angle: 0  
20/08/13 19:08:59  
Made In OsirIX

# ANGIOCT POS OP

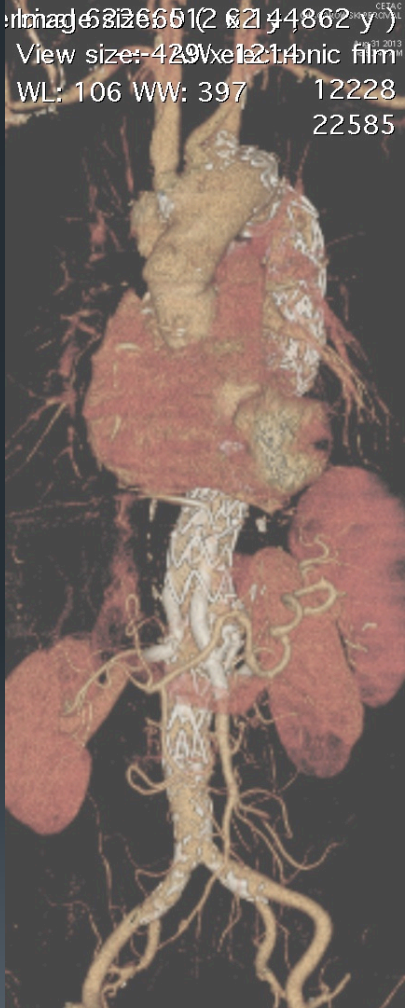




# ANGIOCT POS OP

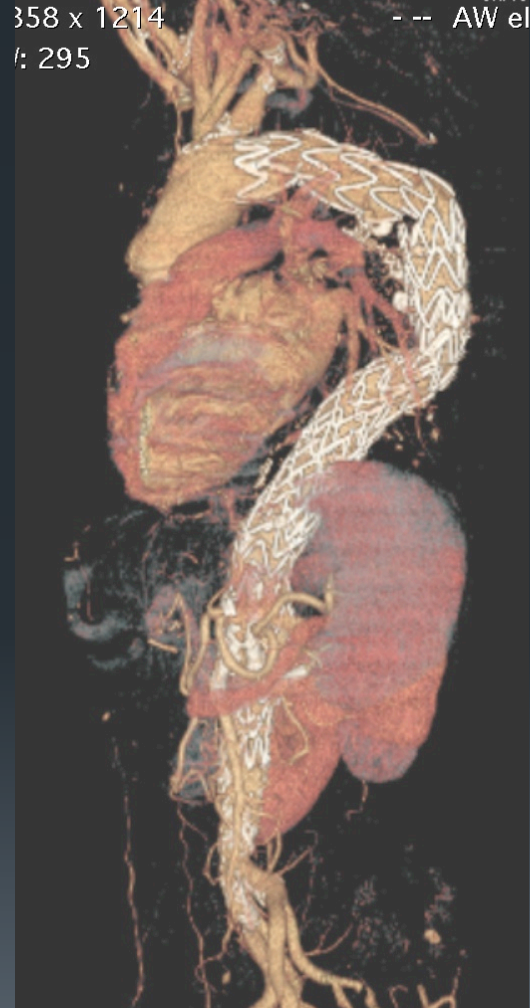


...rimgj6326651(2 82144862 y)  
View size: 429x1214  
WL: 106 WW: 397 12228  
22585



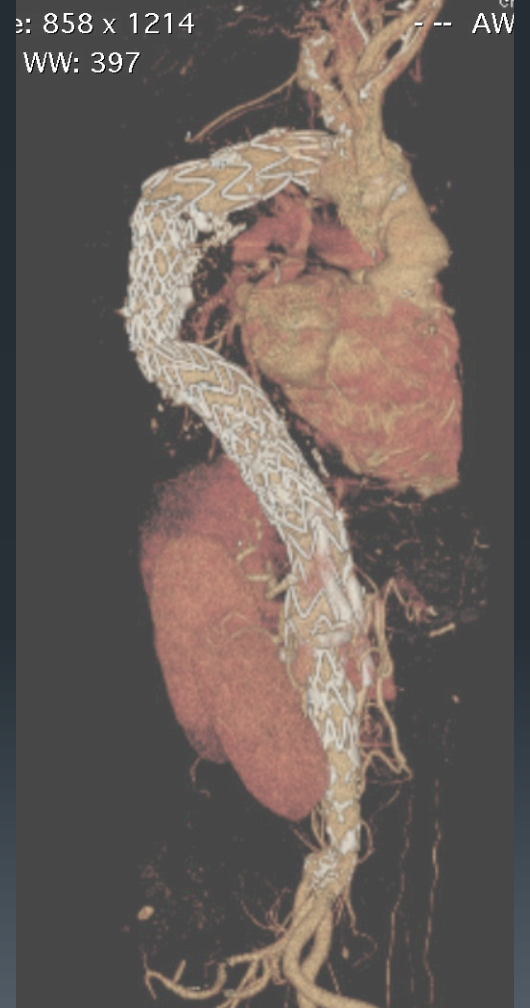
Zoom: 84% Angle: 0  
Im: 5/6 31/08/13 08:45:20  
Uncompressed Made In OsiriX

358 x 1214 --- AW el  
: 295



% Angle: 0  
31/08/

858 x 1214 --- AW  
WW: 397



58% Angle: 0  
essed  
31/08/



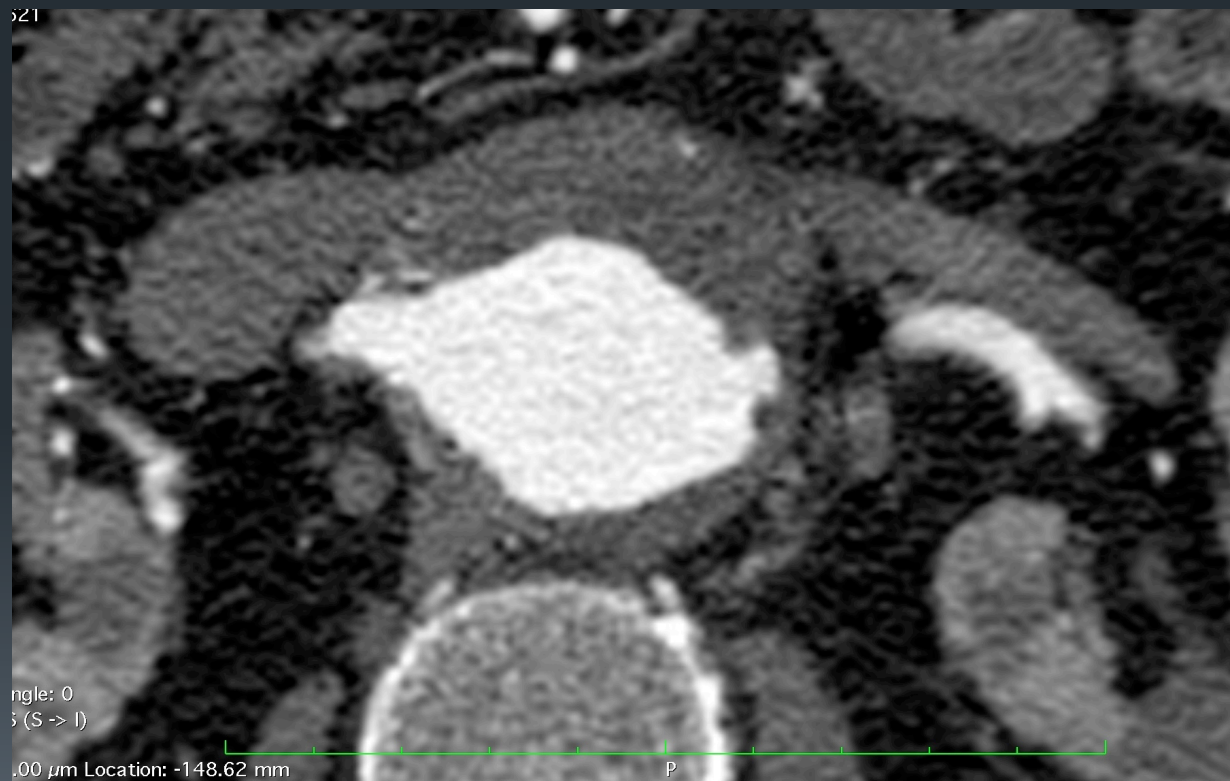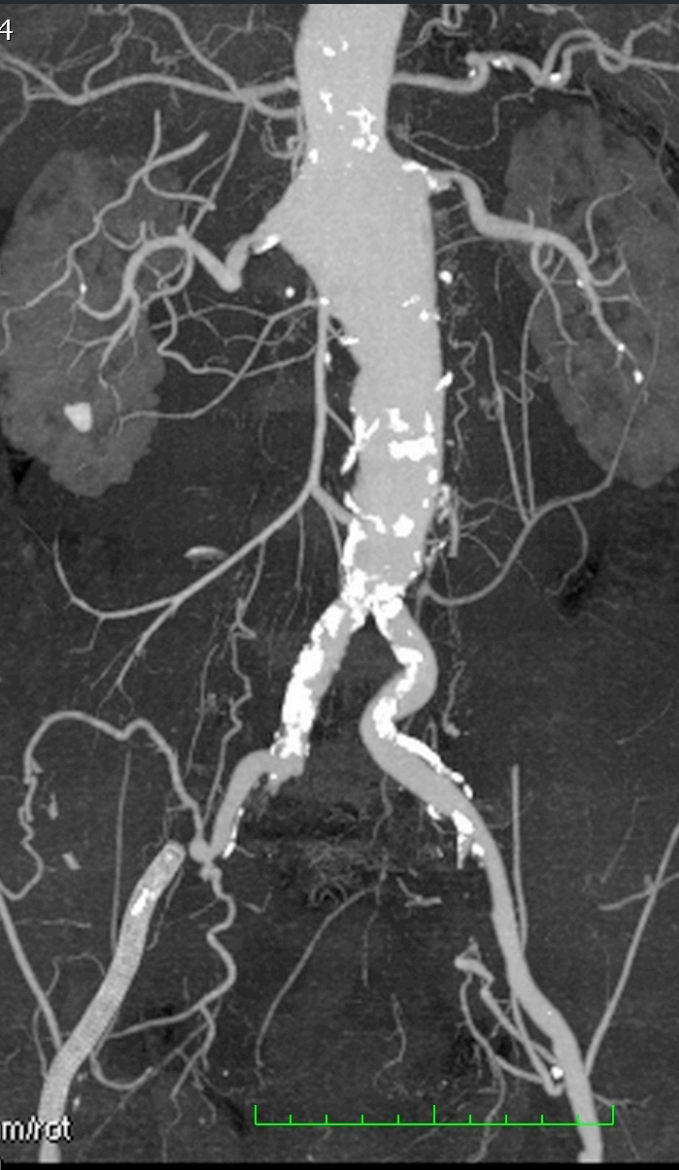# CASE 2

MALE

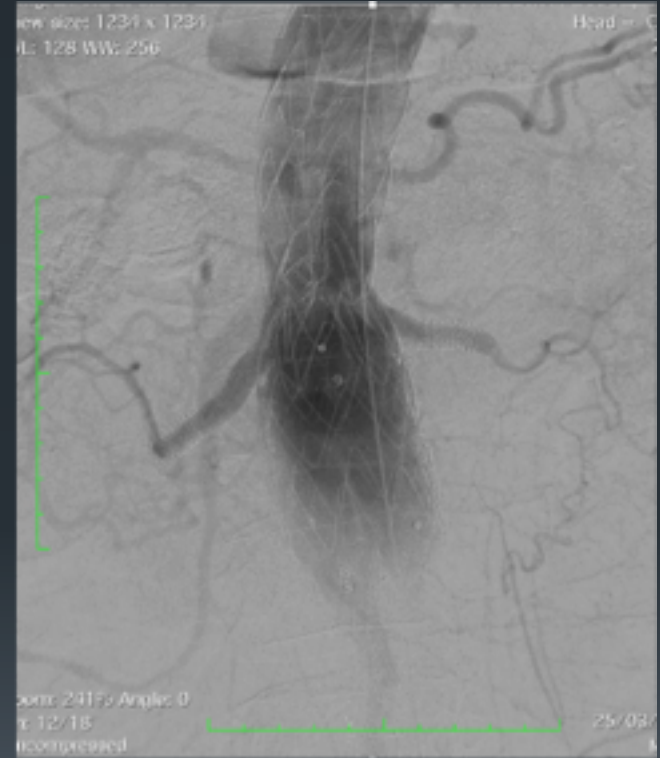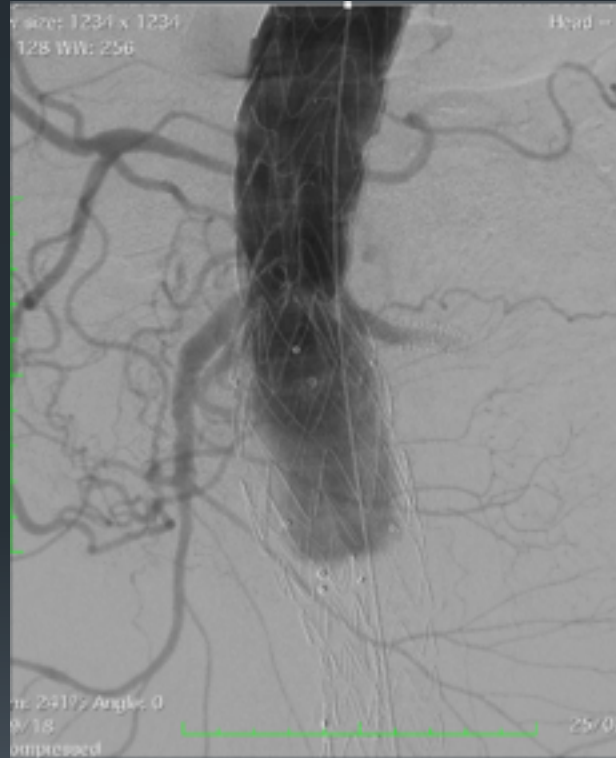
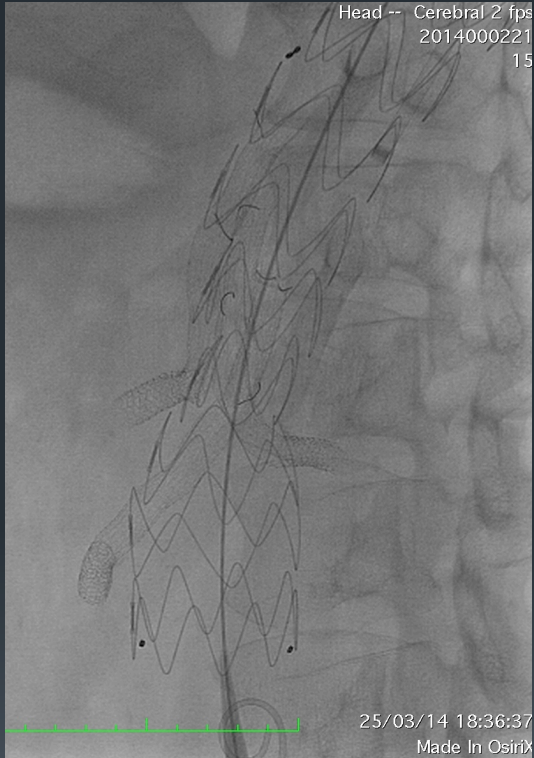
65 YEARS

AAA PARA RENAL 58MM

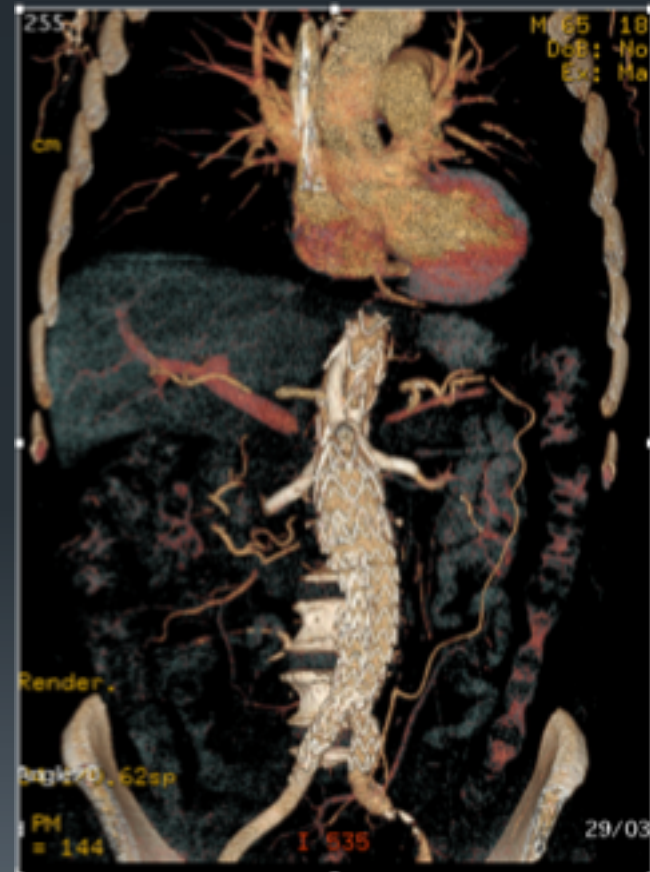
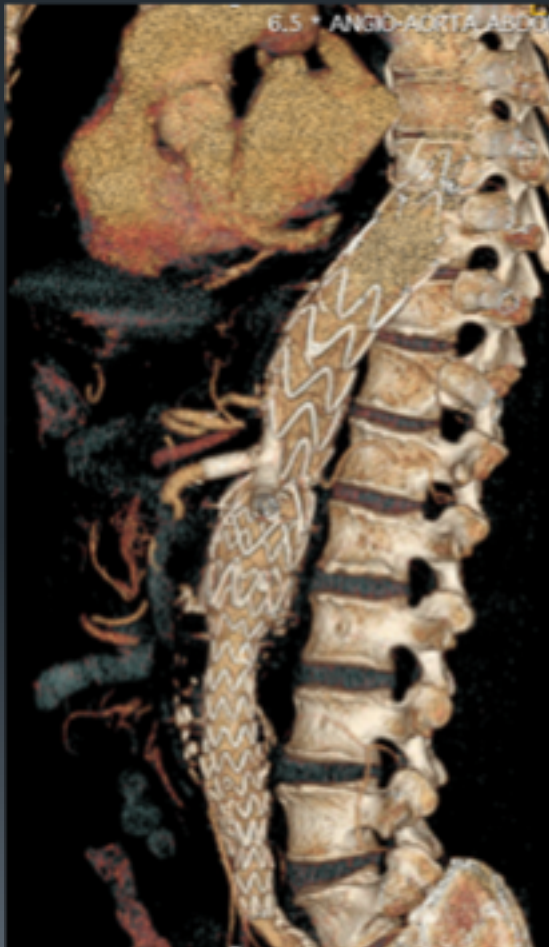# CASE 2



# PROCEDURE



# ANGIOCT POS OP





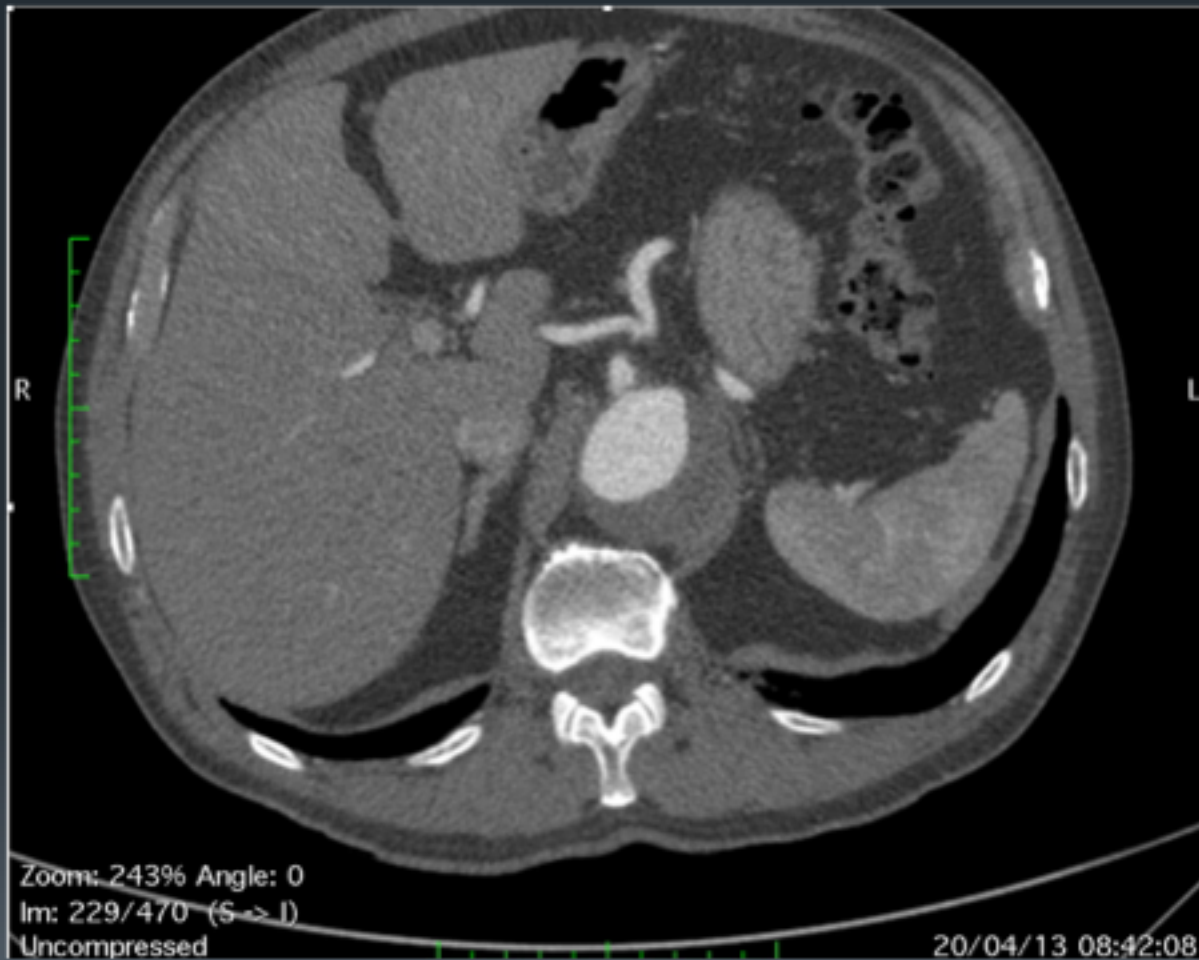# CASE 3

MALE

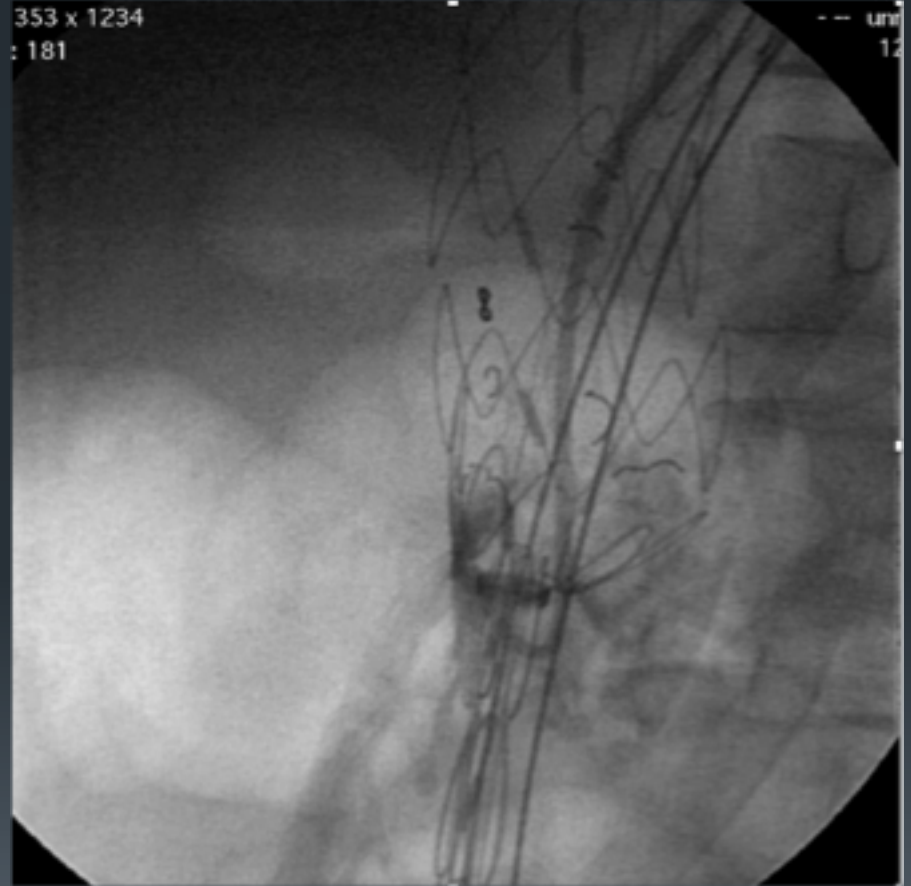
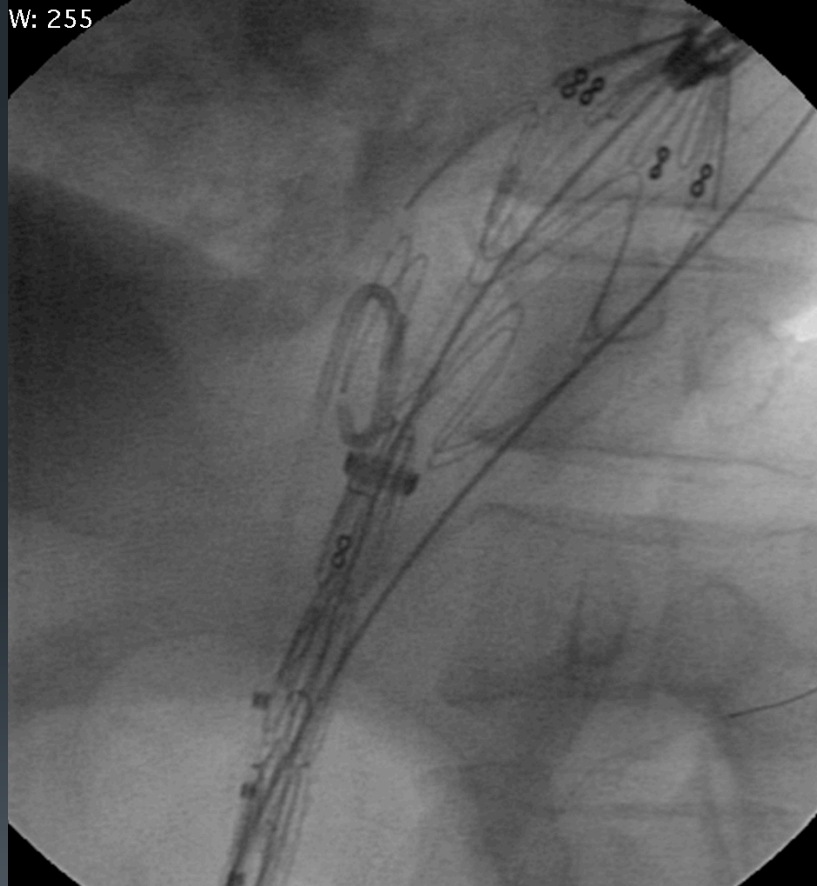
74 YEARS

ATA TYPE IV 78MM

# CASE 3

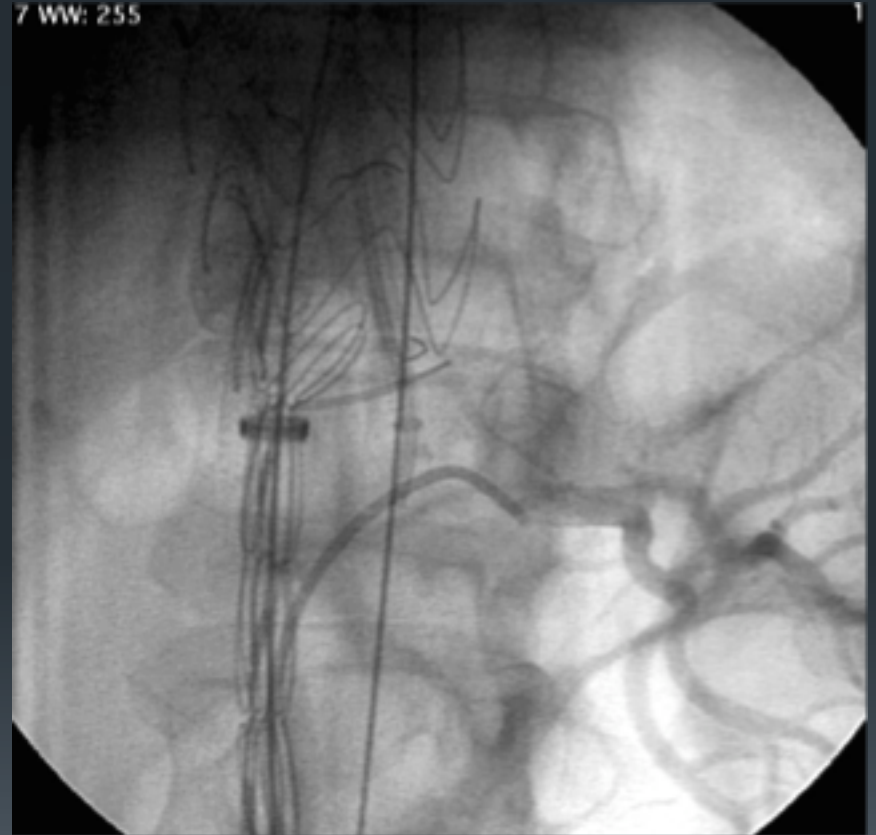
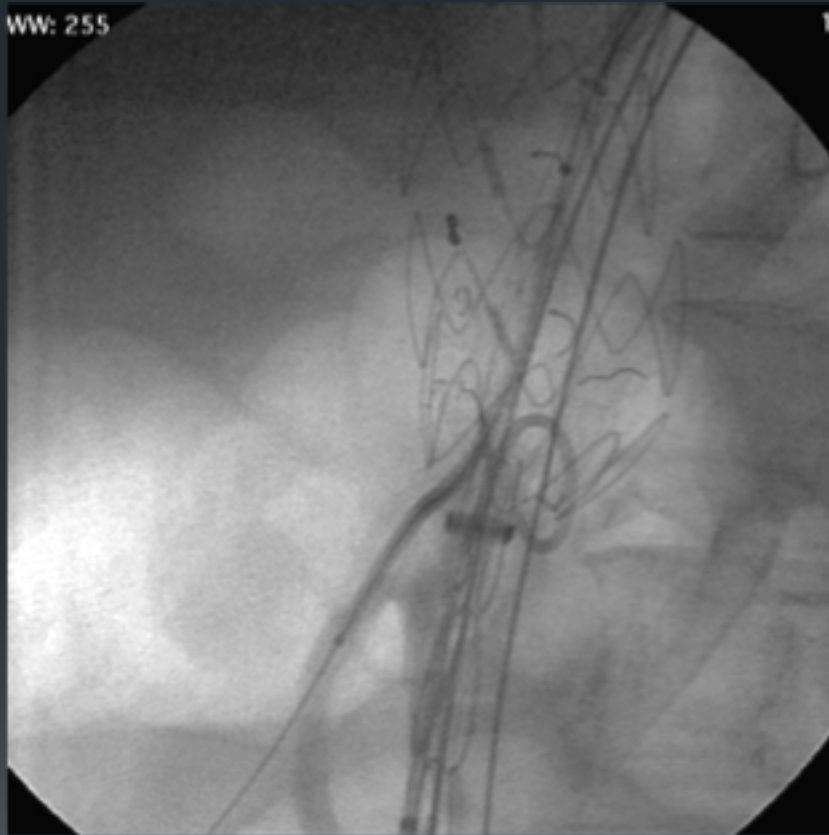


# PROCEDURE

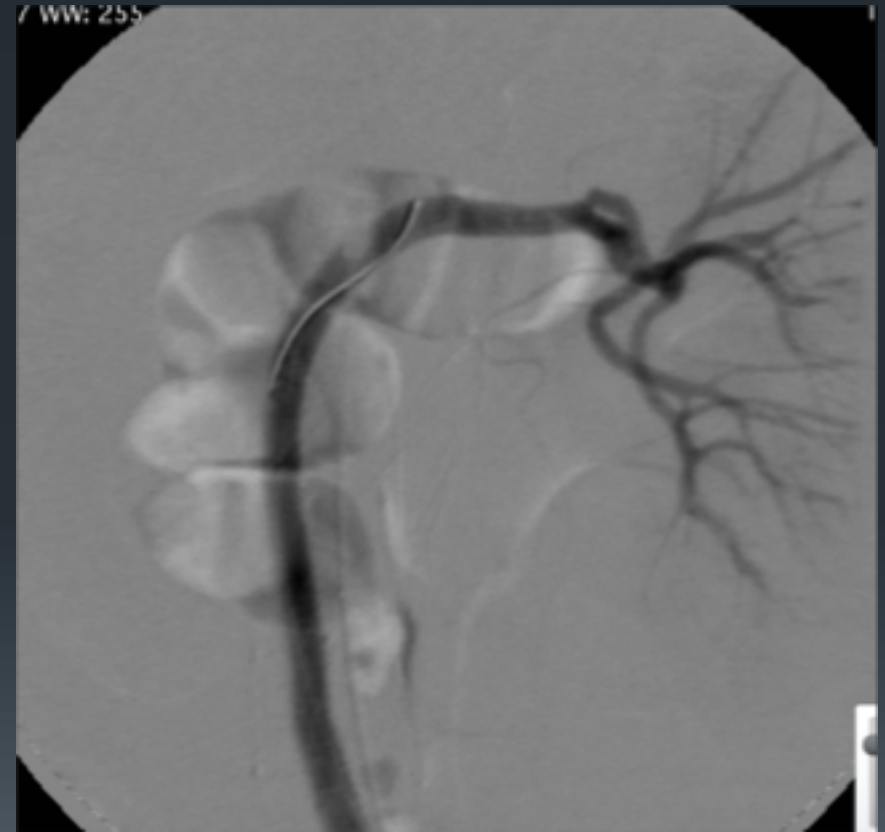
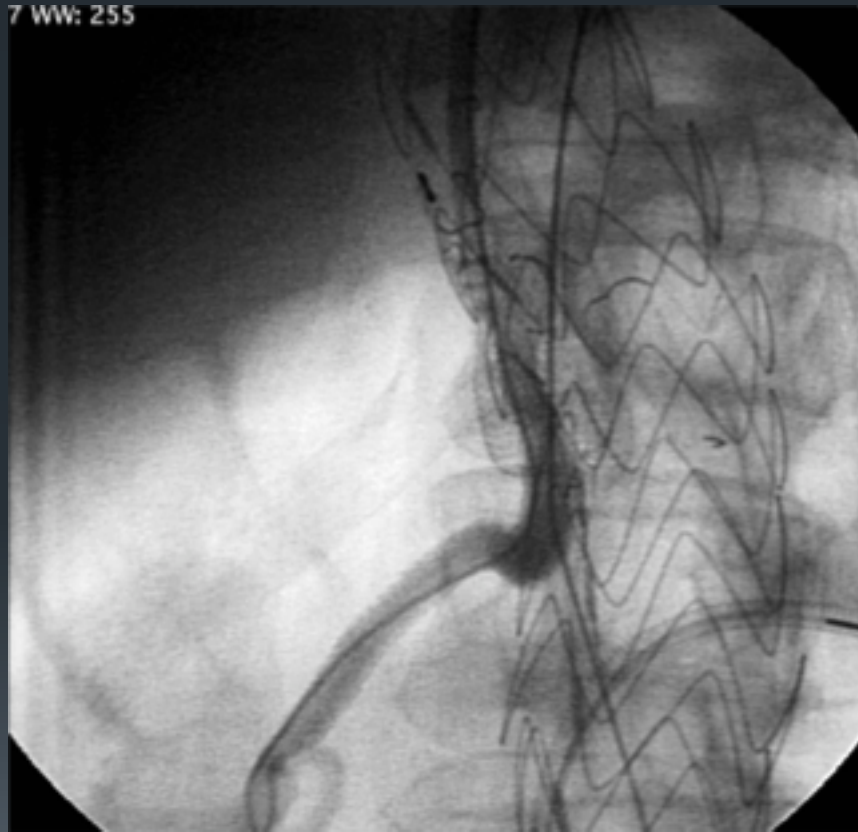


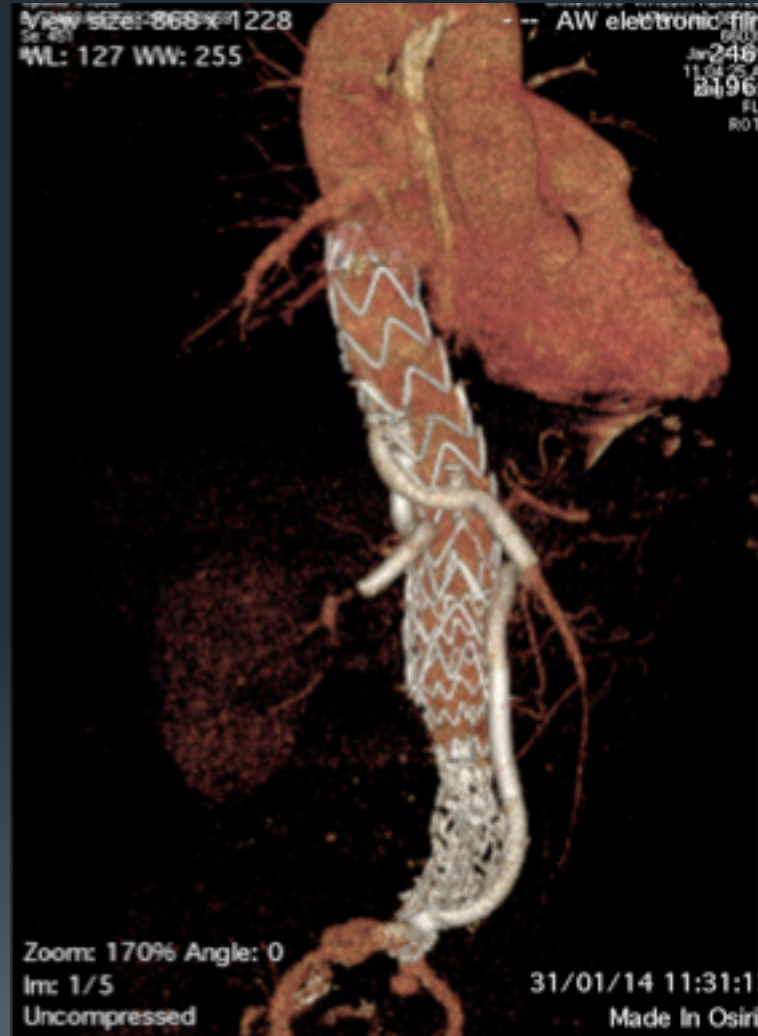
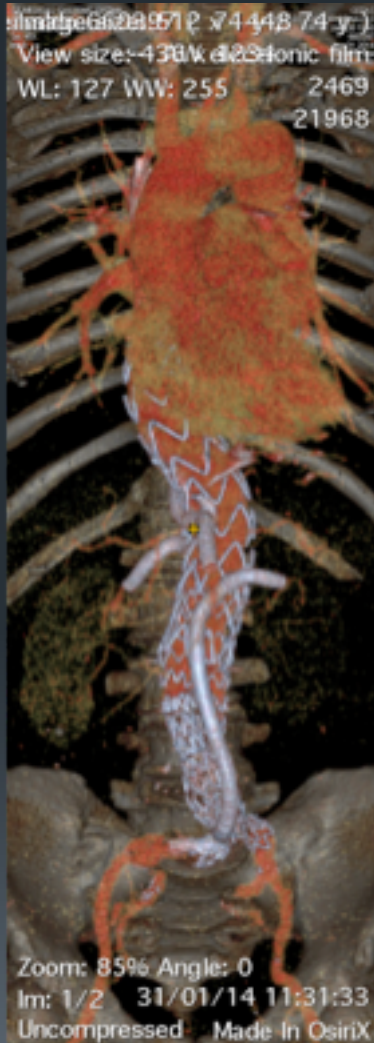
# PROCEDURE



# PROCEDURE



# POST OP

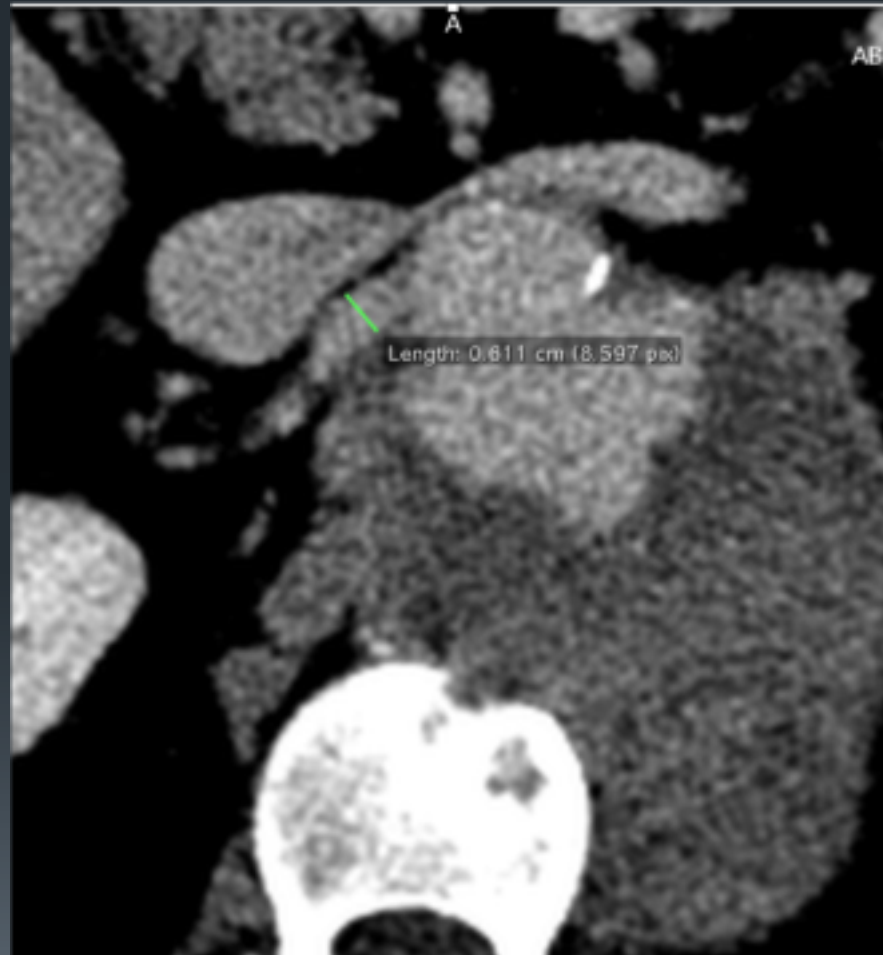




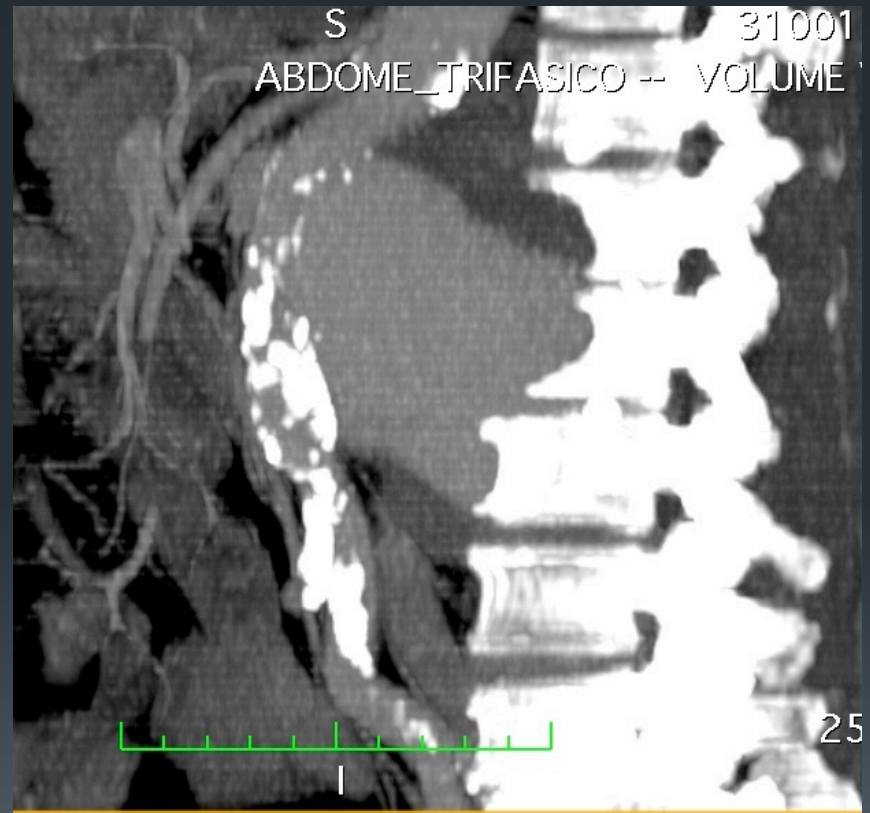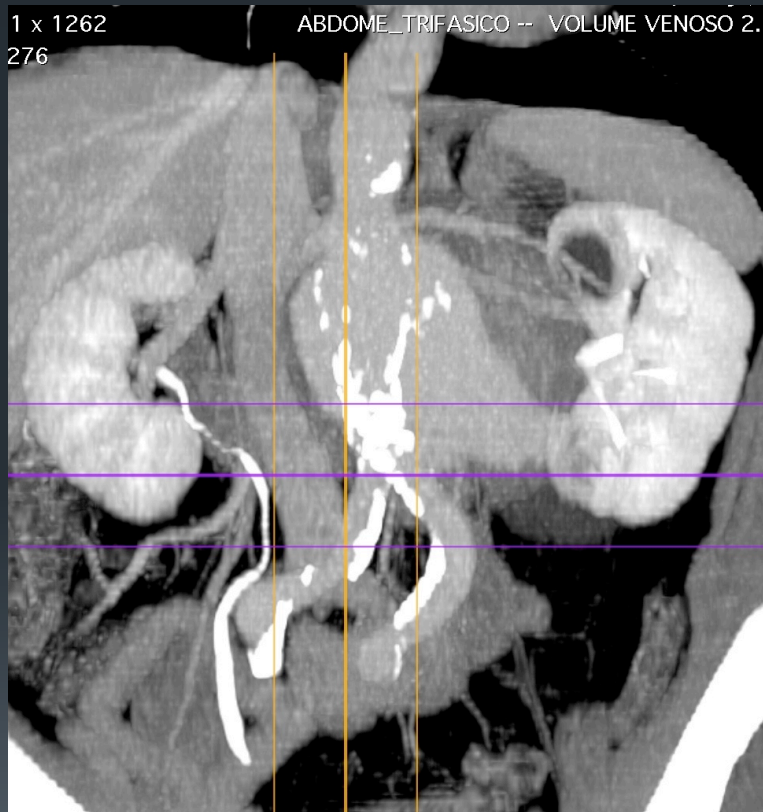## CASE 4

- Male, 70 years old
- Coronary disease
- Pulmonary disease
- AAA Para-renal 12cm


# ANGIO-CT 25/11/14




# ANGIOTC 25/11/14



# PROCEDURE



# PROCEDURE

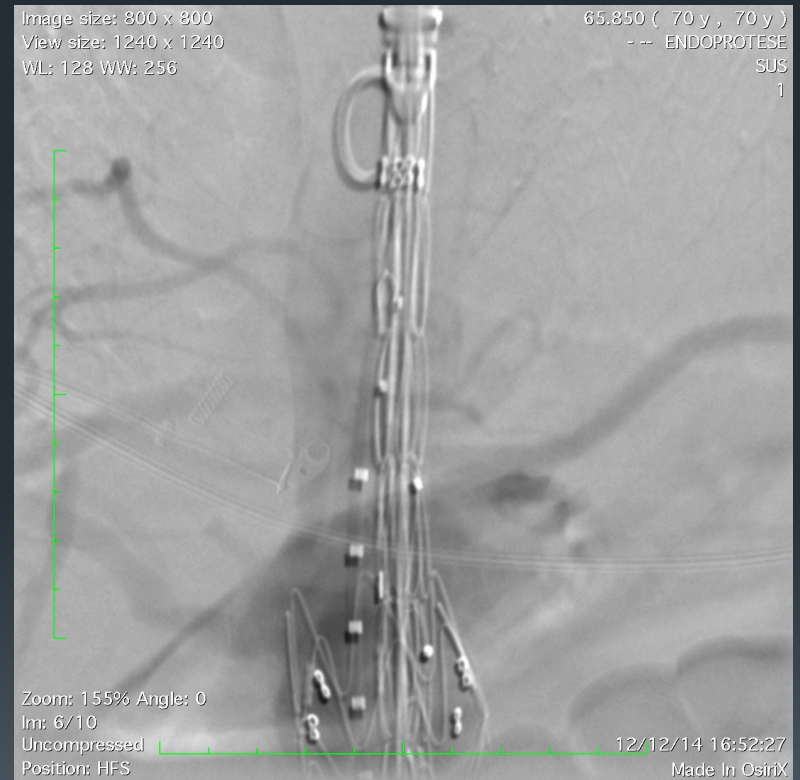
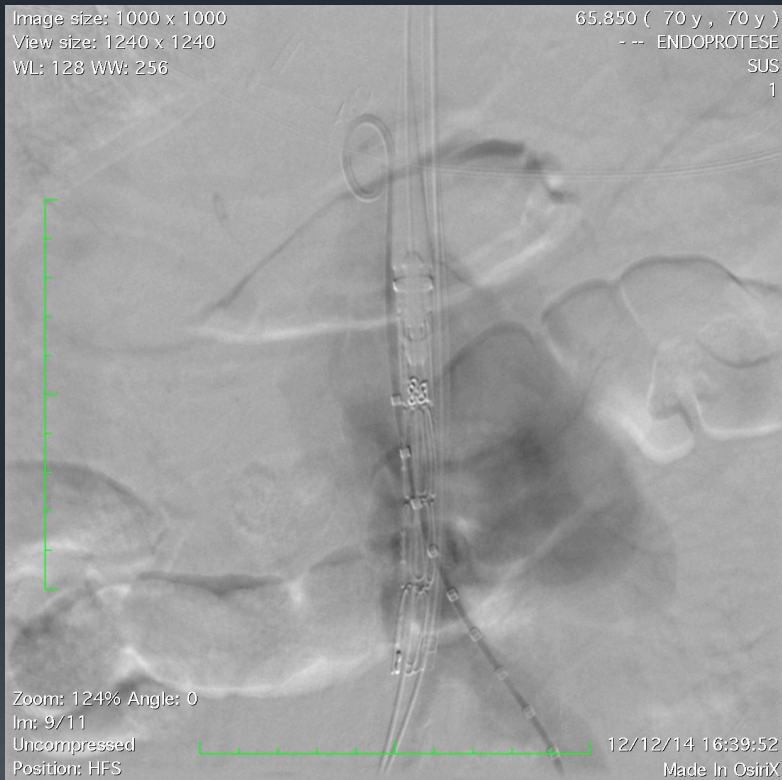


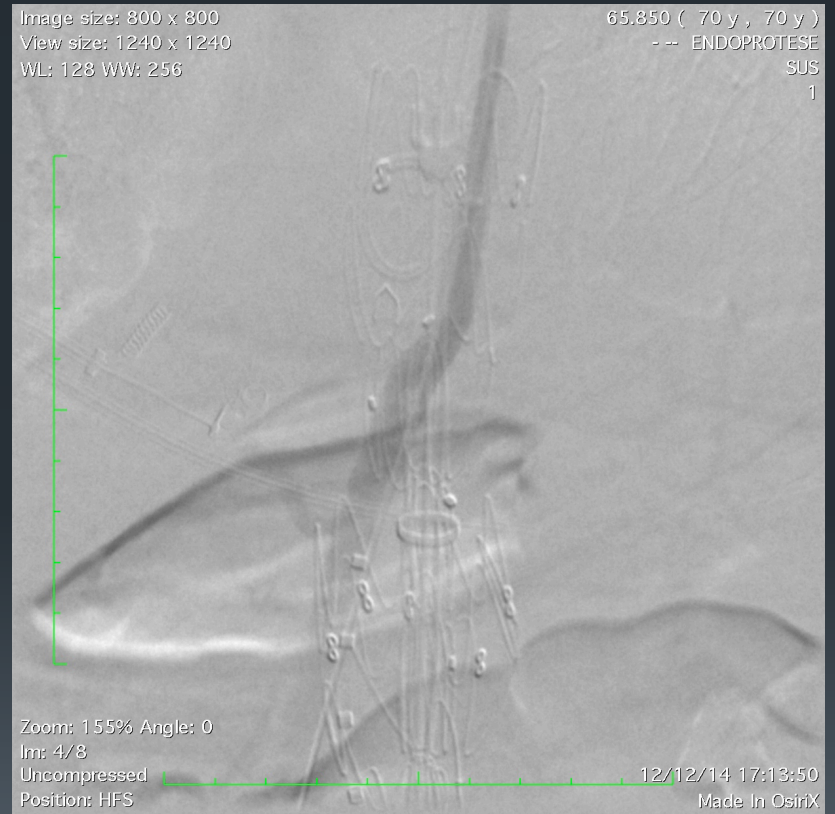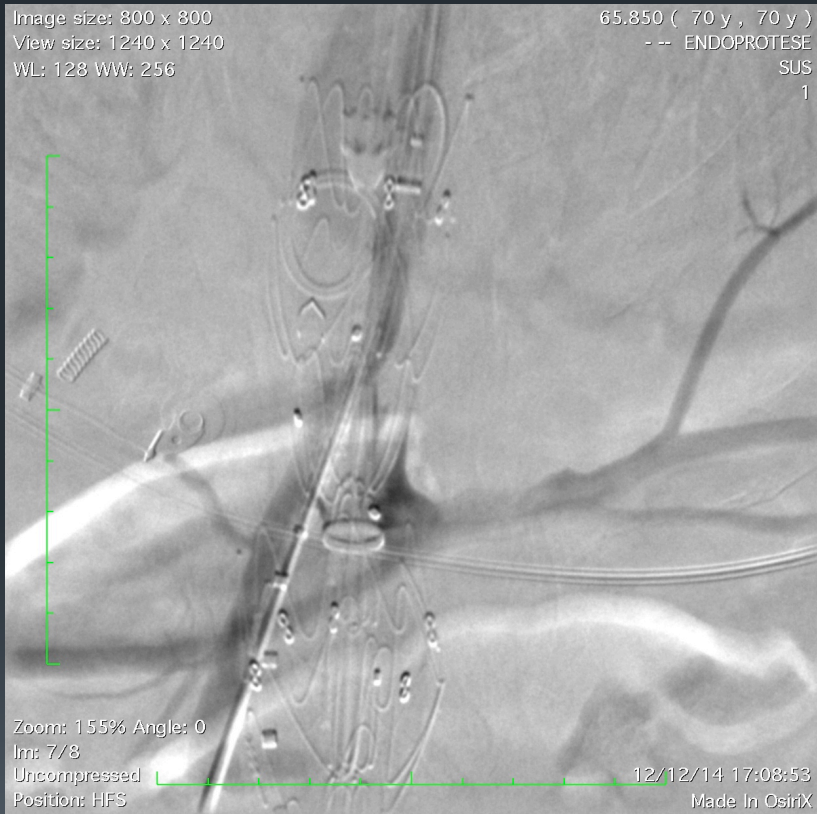# PROCEDURE



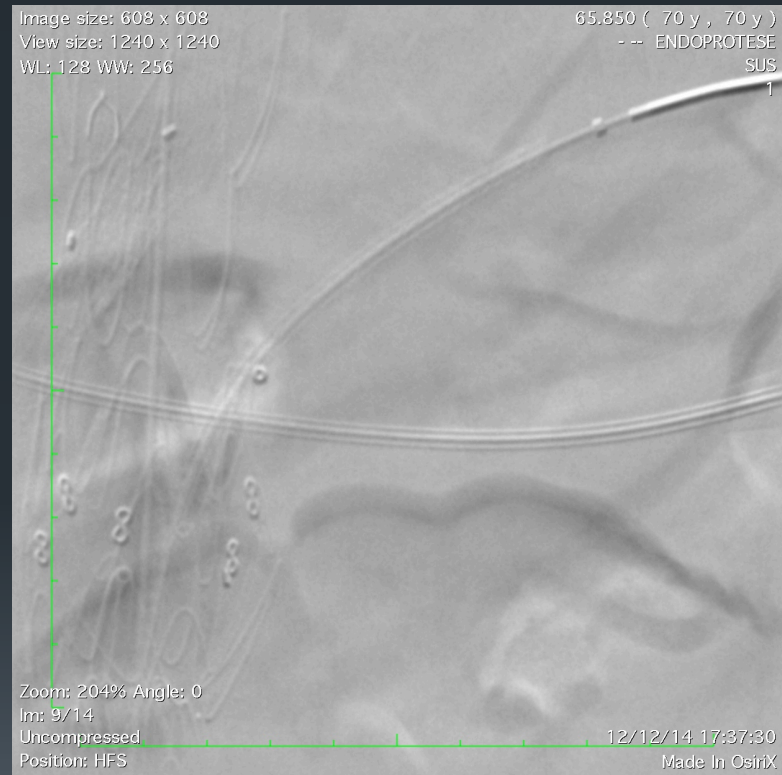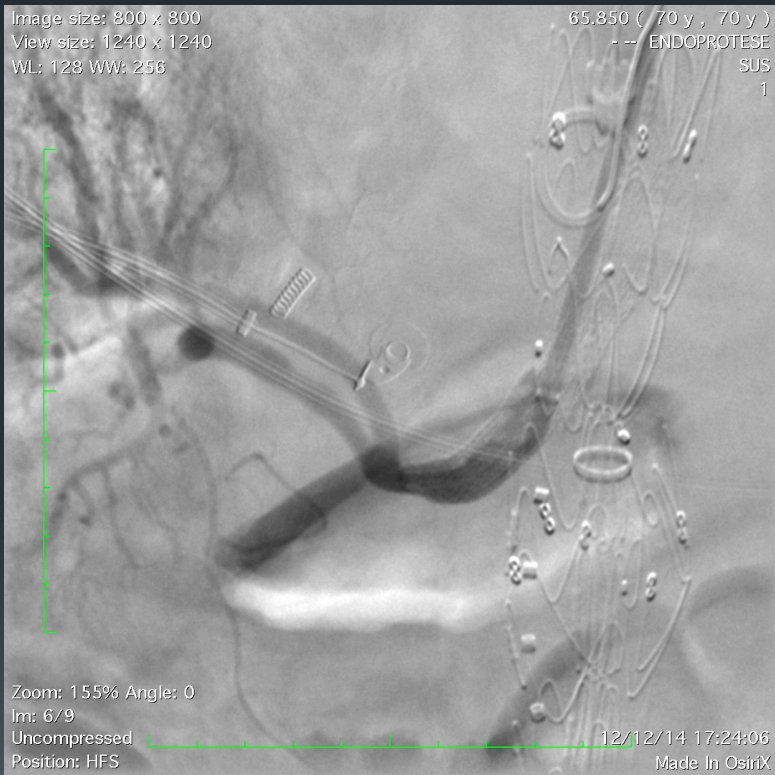# PROCEDURE



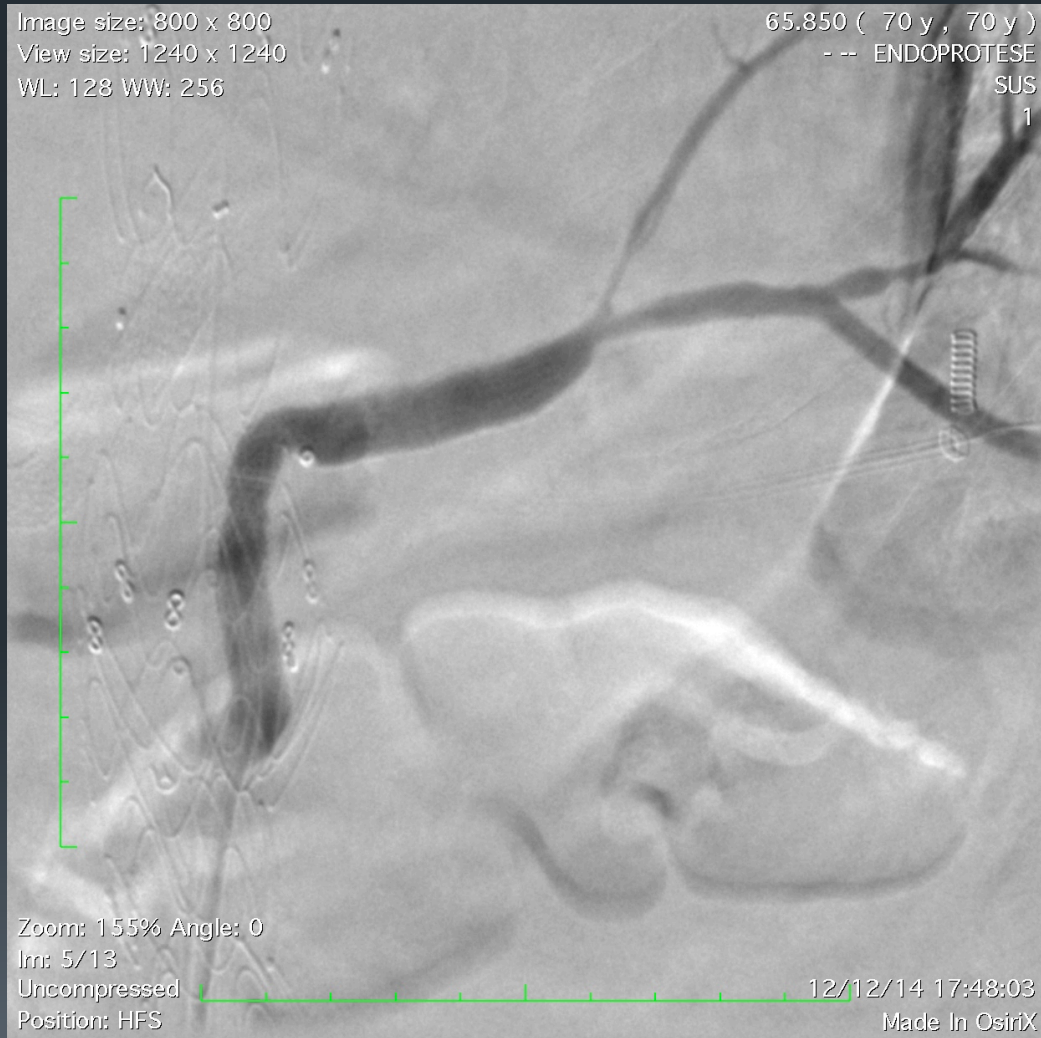# PROCEDURE SMA



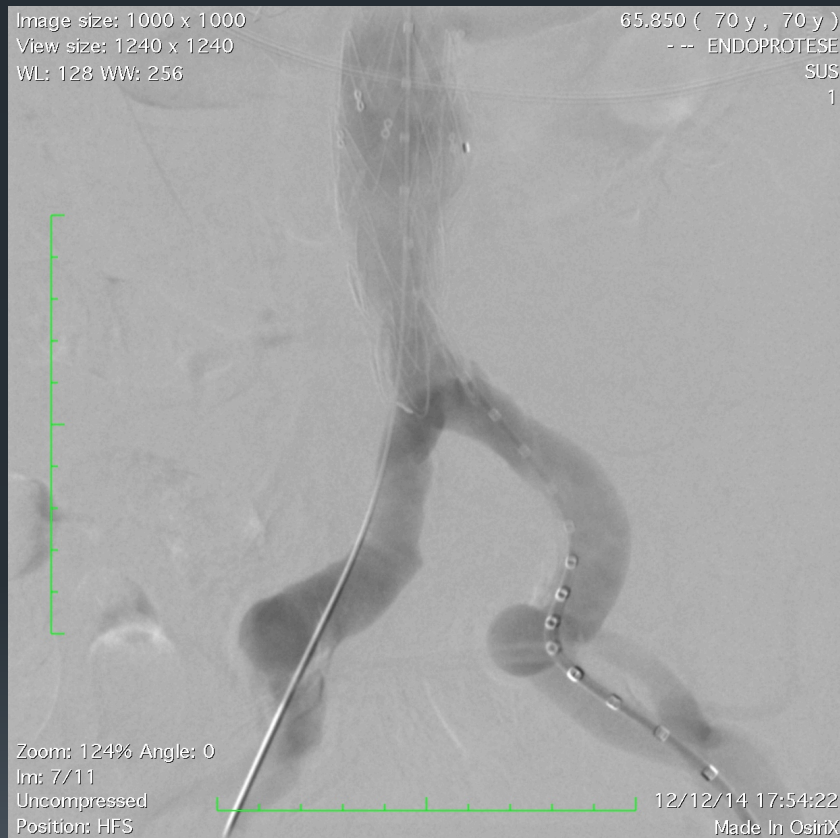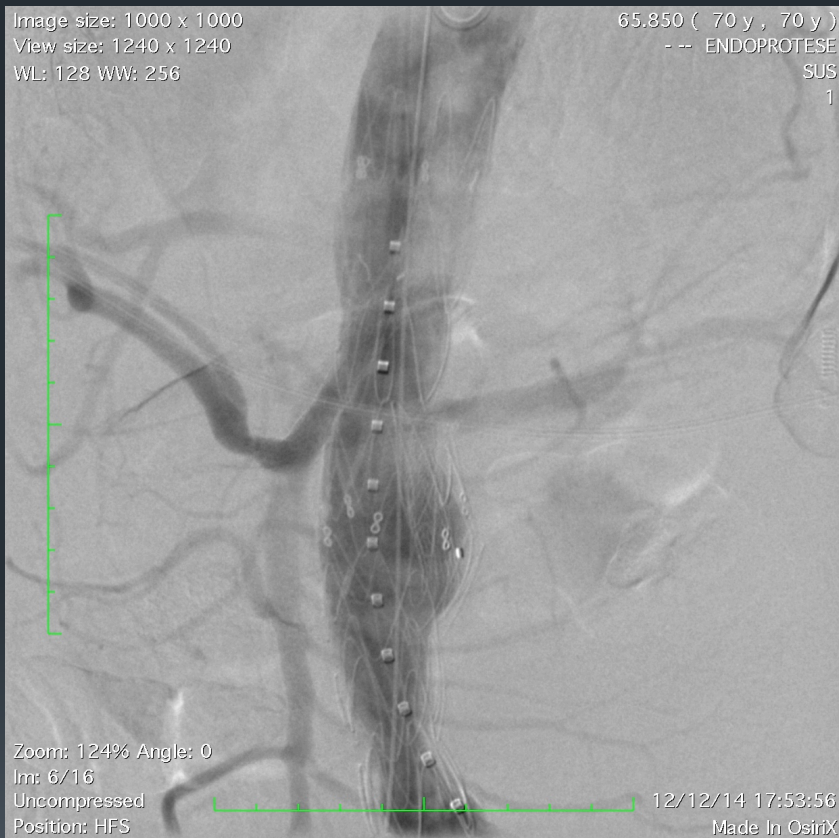# PROCEDURE RENAL ARTERIES



# PROCEDURE RENAL ARTERIES

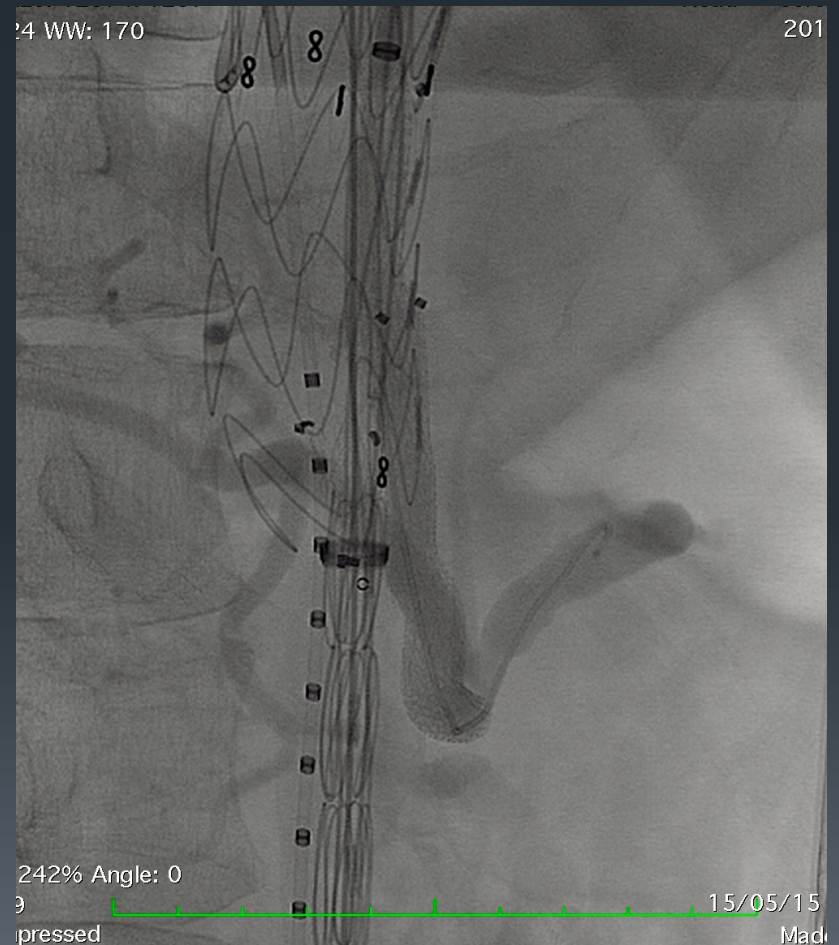
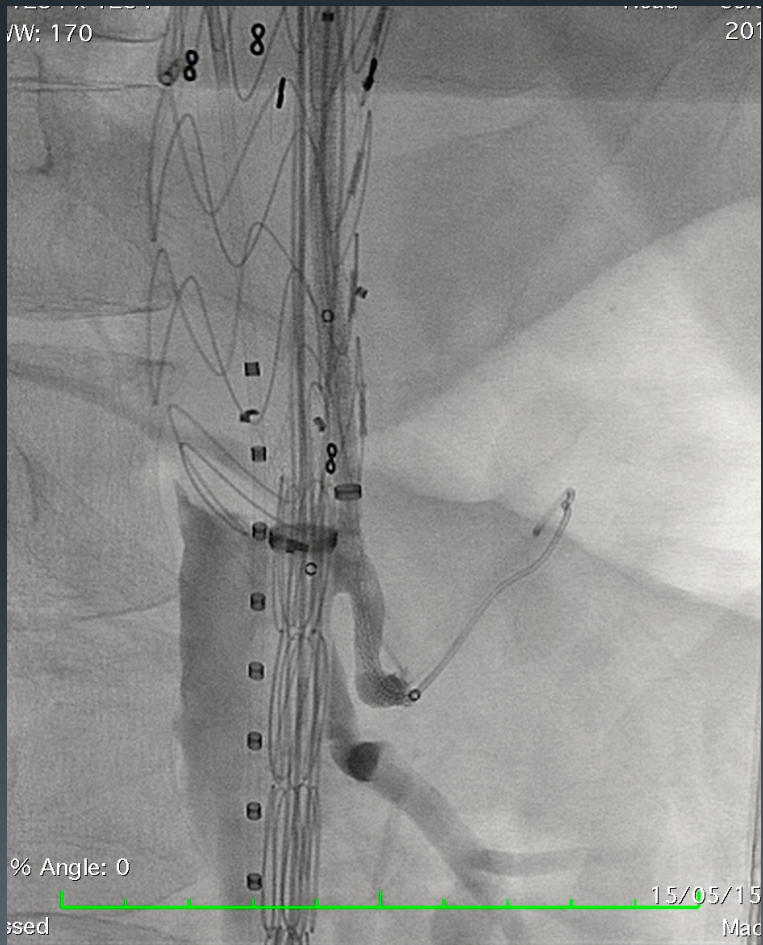

# FINAL ANGIOGRAM



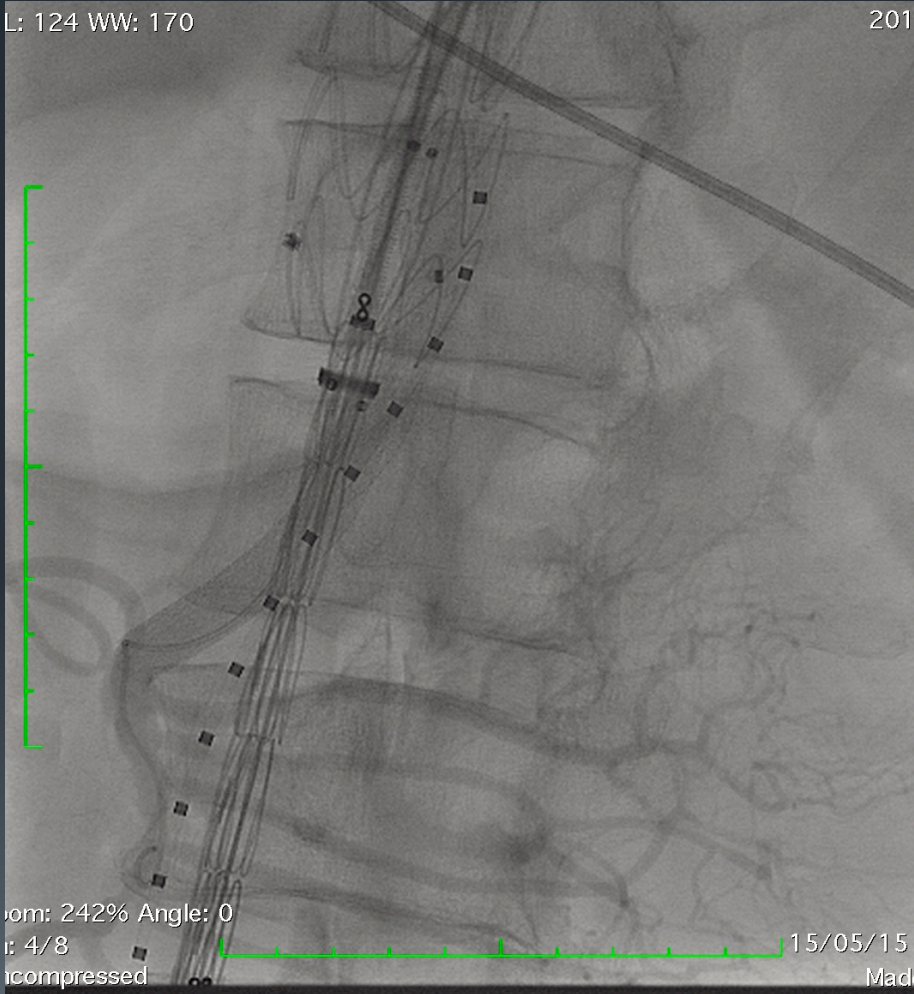
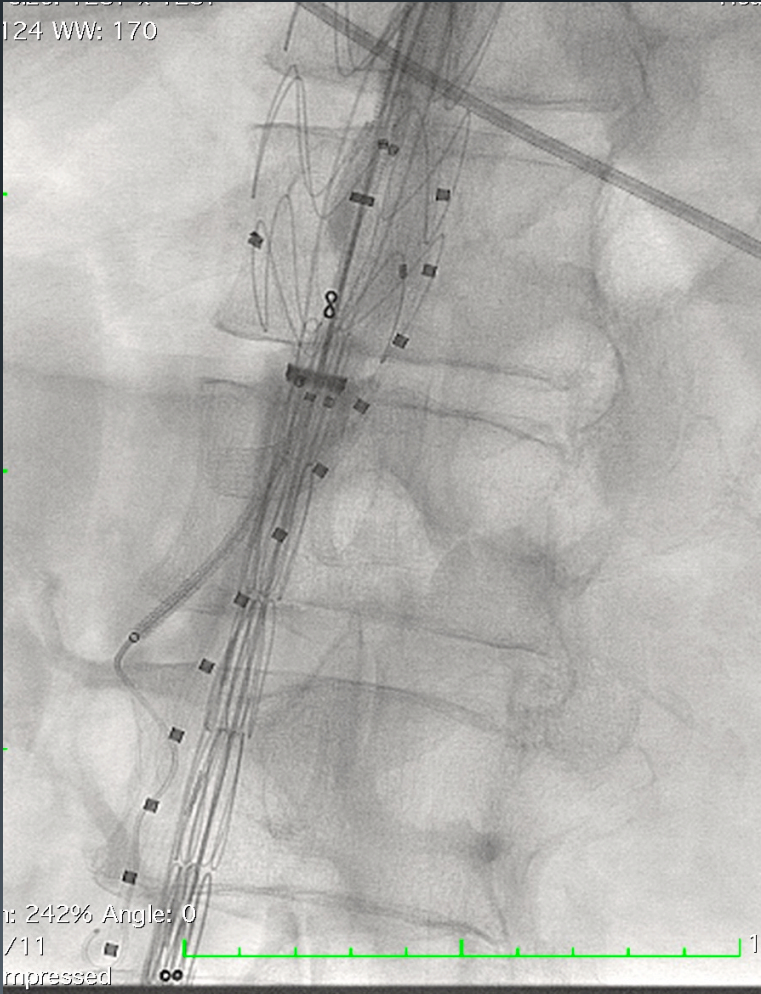
# CASE 5

## CELIAC TRUNK



# PROCEDURE

## SMA



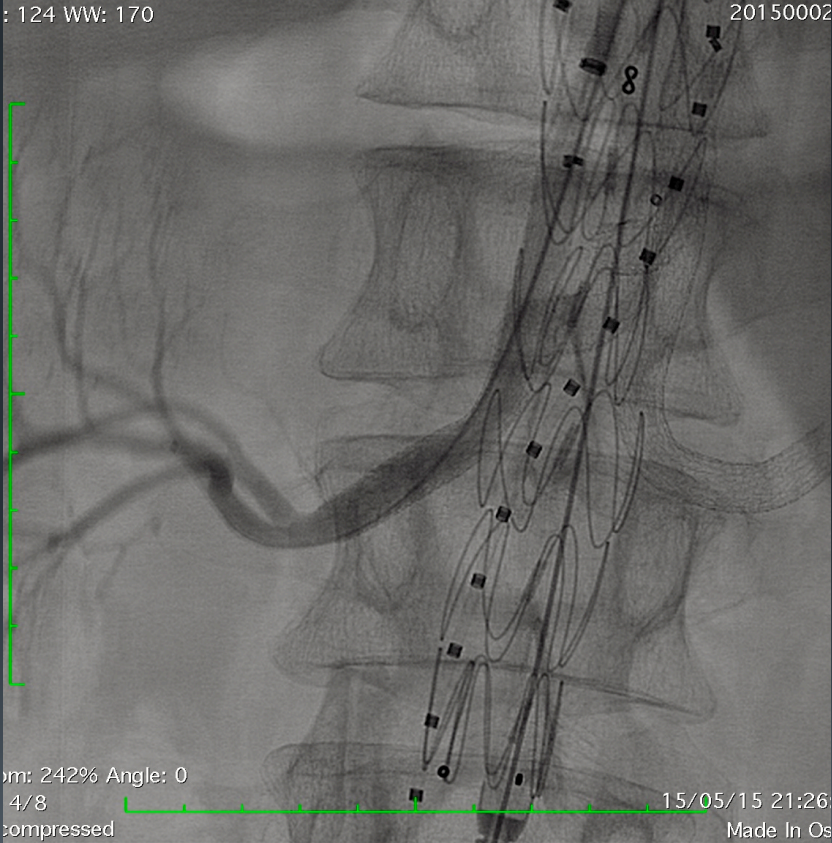
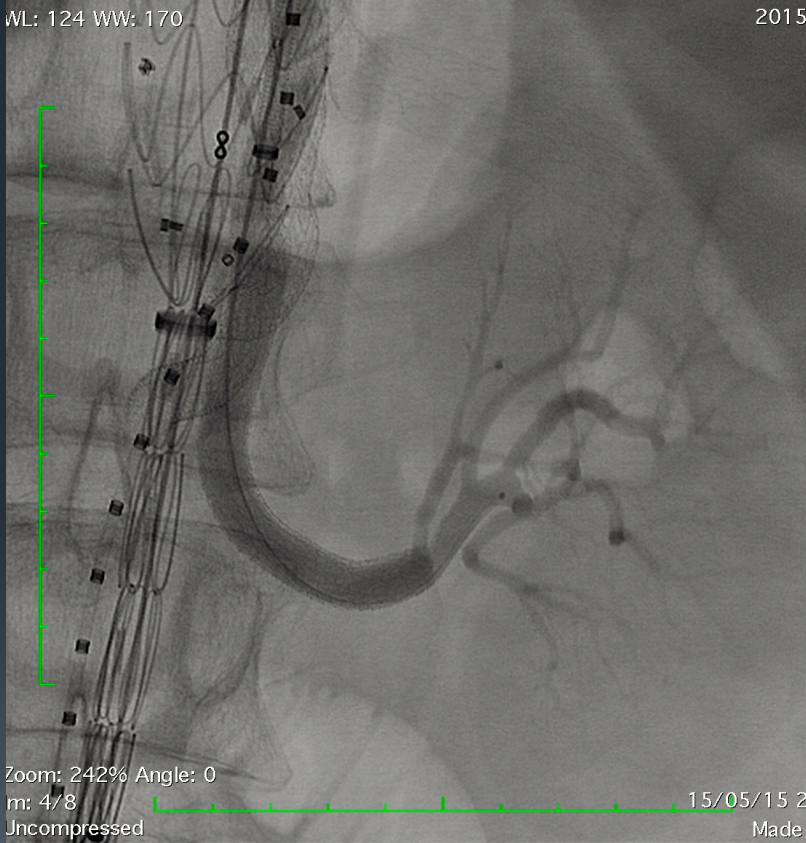


# PROCEDURE



## LEFT RENAL

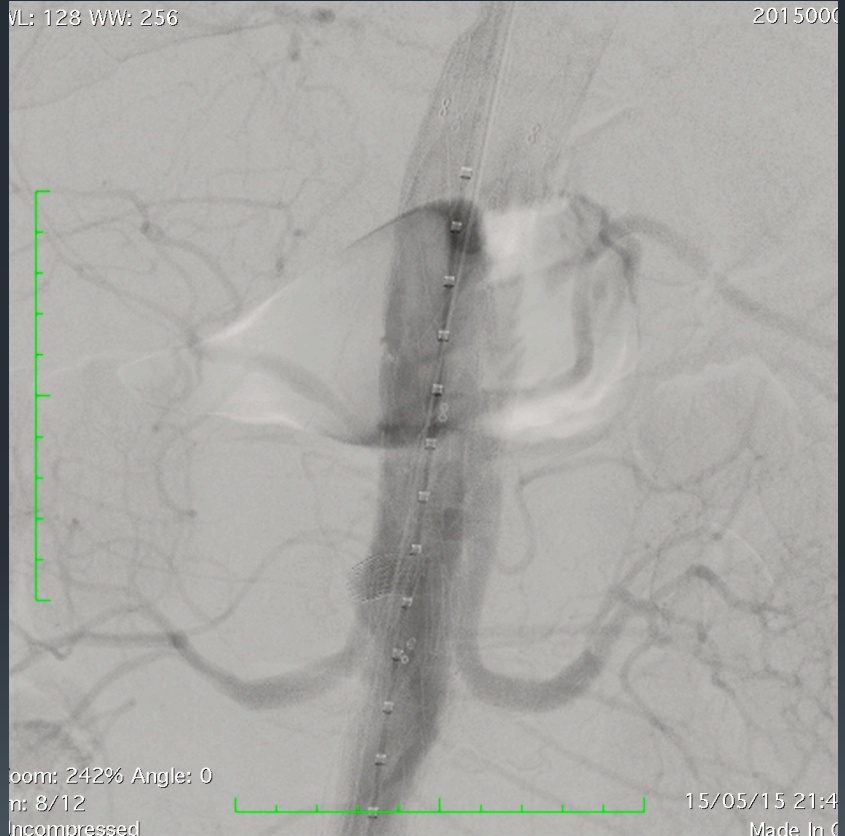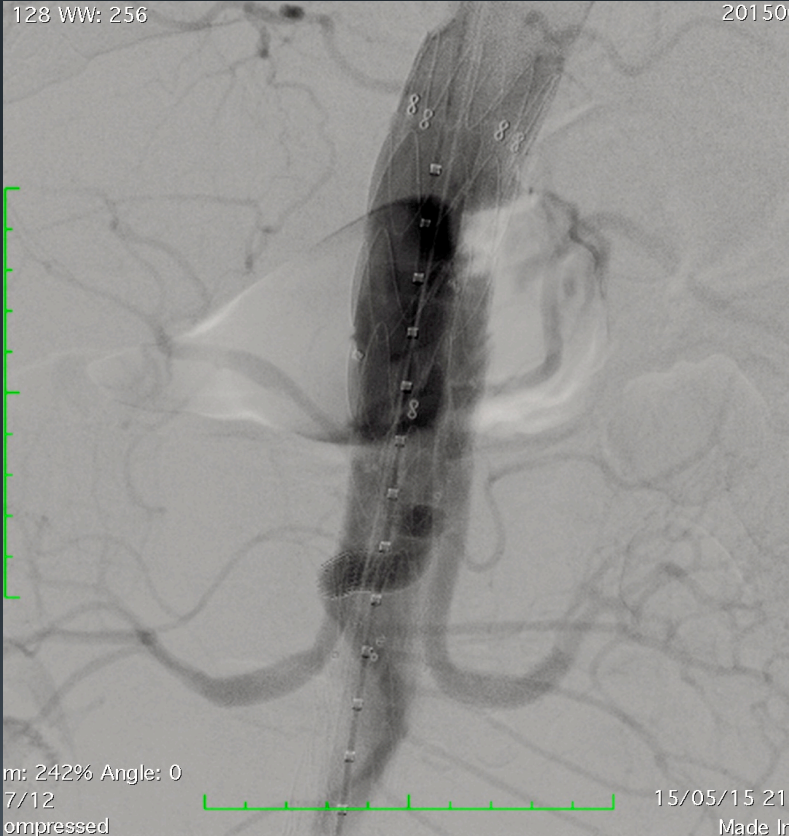## RIGHT RENAL



# PROCEDURE

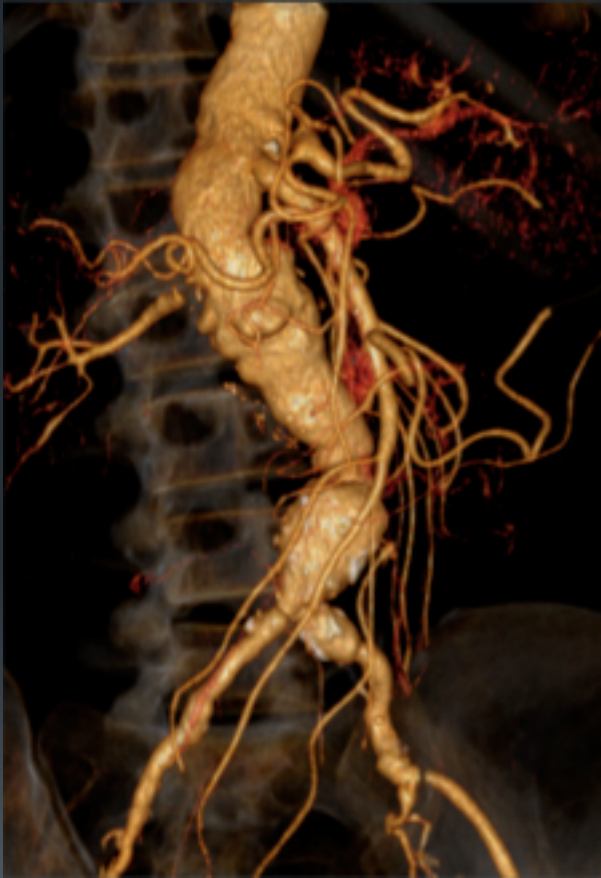

## FINAL ANGIOGRAM

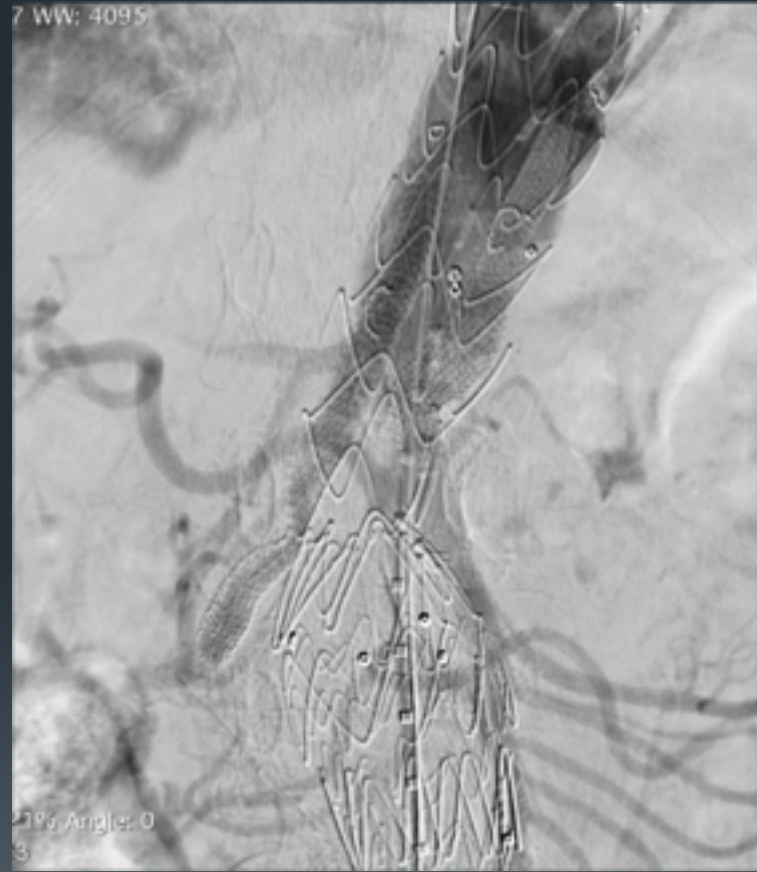


# CASE 6

PRE – OP

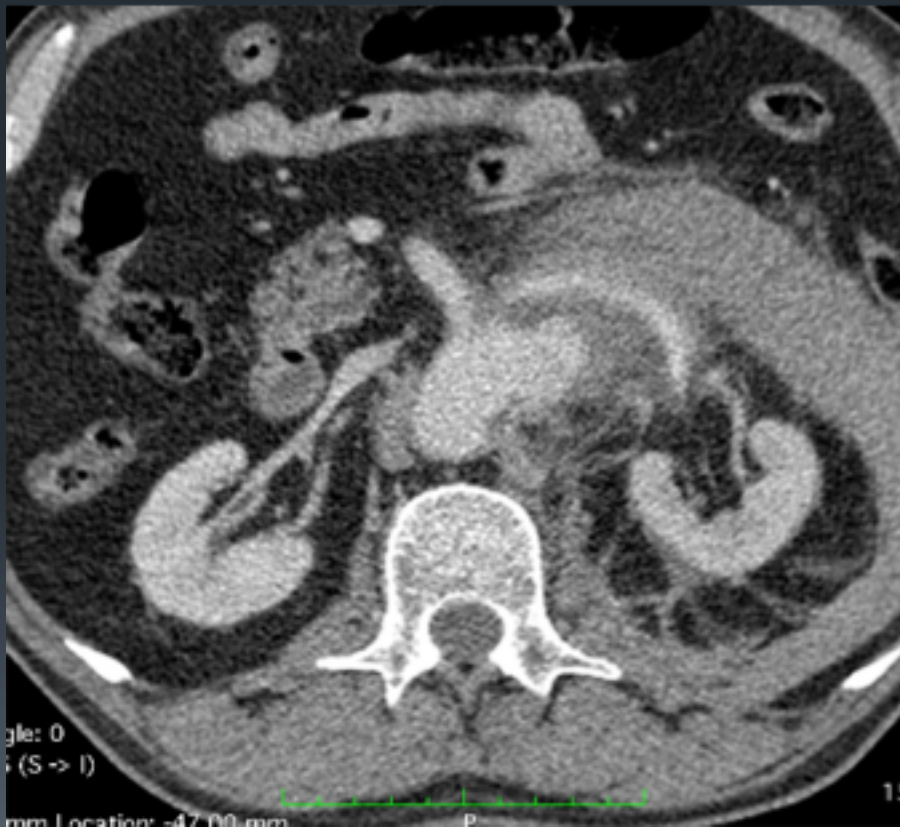


PROCEDURE



# CASE 7

## RUPTURED THORACOABDOMINAL ANEURYSM



# RESULTS

FINAL ANGIOGRAM

