



Treatment of a challenging case of acute limb ischemia with the Indigo thrombectomy system

Dr. Theodosios Bisdas, Dr. Angeliki Argyriou

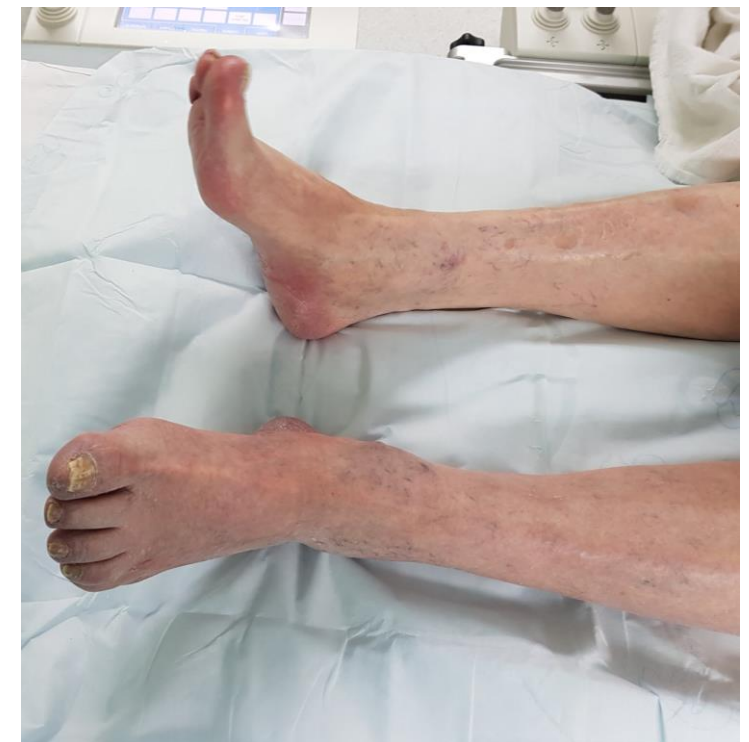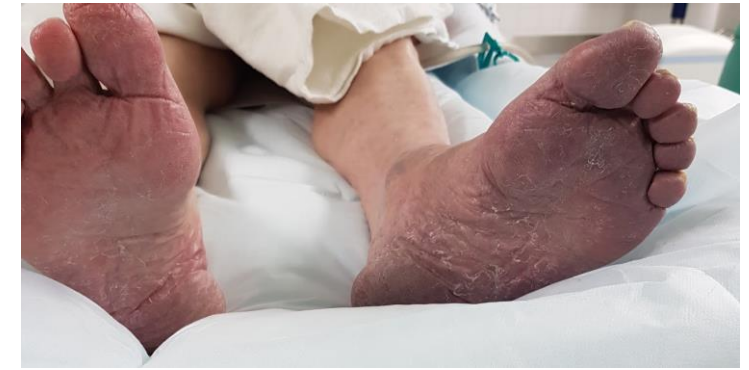Clinic for Vascular Surgery

St. Franziskus Hospital Muenster

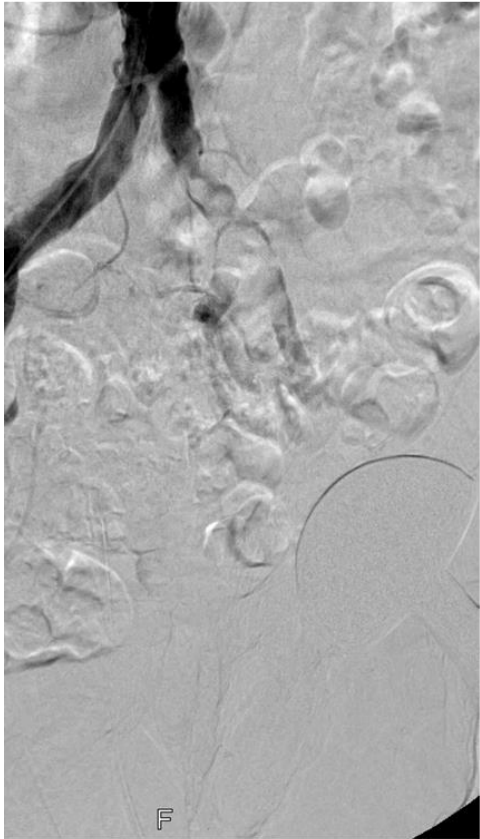
Email: th.bisdas@gmail.com

Case presentation

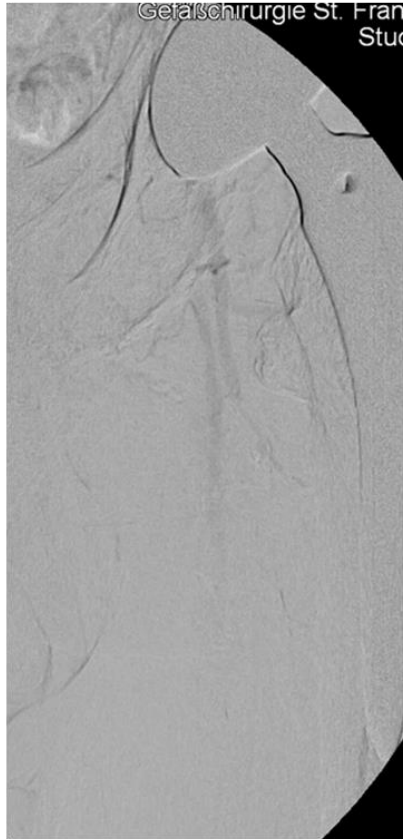- Male, 76y
- Comorbidity:
 - Atrial fibrillation (INR: 2.9 on admission)
 - Coronary artery disease
 - NYHA III
 - COPD Gold 3
 - CKD Stadium 3
- Diagnosis:
 - Acute limb ischemia left lower limb (2 days)
 - Rutherford category 3



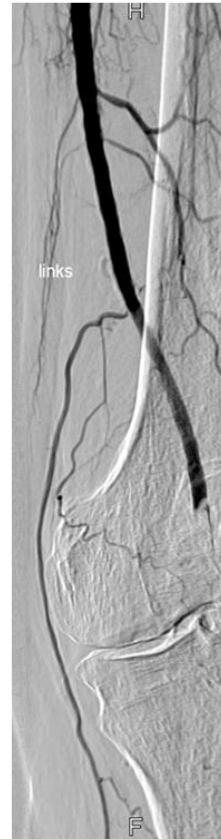Angiographic findings



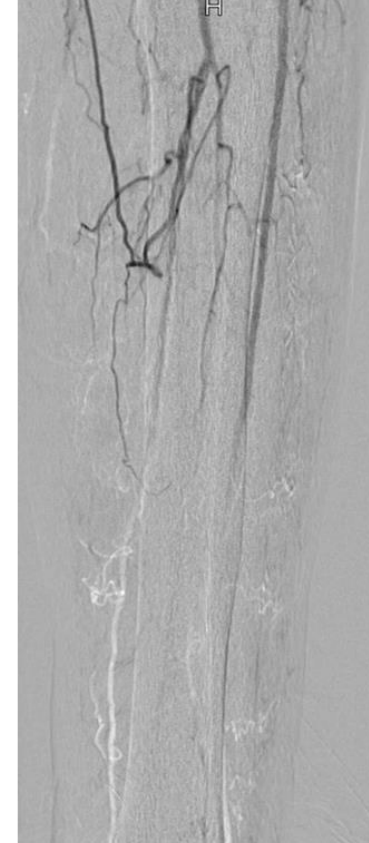Common iliac artery



Common femoral artery
Superficial femoral artery



Popliteal artery



Infrapopliteal arteries





What would you do in this case?

The patient is multimorbid with an INR of 2.9 on admission. This means that he had probably an embolic event despite adequate anticoagulation. The ischemia is 2 days old and the patient has severe pain and a neurologic deficit of the forefoot. The CT-angiography revealed no evidence of malignancy and showed a small thrombus into the left atrium.

The treatment options would be:

1. Open surgical thrombectomy
2. Lysis + second look
3. Mechanical thrombectomy \pm lysis



Our concept

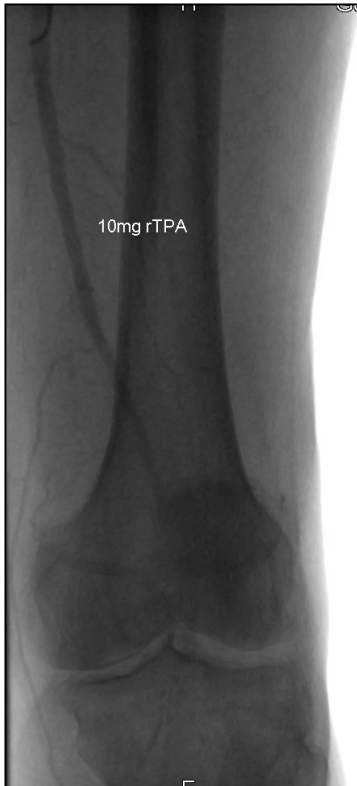Due to the multimorbid condition of the patient, the increased INR and the embolic occlusion of the infrapopliteal arteries we decided to perform an endovascular first-approach. A lysis-alone treatment was not considered safe due to the age and comorbidity of the patient as well as the location of the thrombus at the common iliac artery.

We decided to use an aspiration thrombectomy for following reasons:

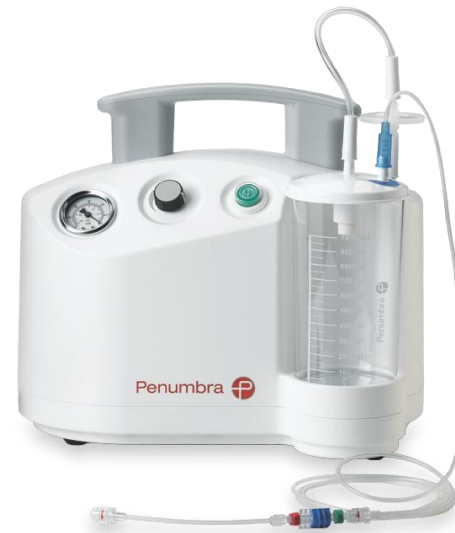
- **Age of the thrombus** (< 14 days) – For older thrombi, we prefer rotational thrombectomy
- **Chronic kidney disease** (we do not favor pharmacomechanical thrombectomy due to the volume of the saline water used and the hematuria)
- **Location of the thrombus** – (risk of vessel injury in the infrapopliteal arteries with rotational thrombectomy, probably need for both 6- and 8F rotational thrombectomy for an adequate thrombectomy at the infrapopliteal and iliac arteries respectively)



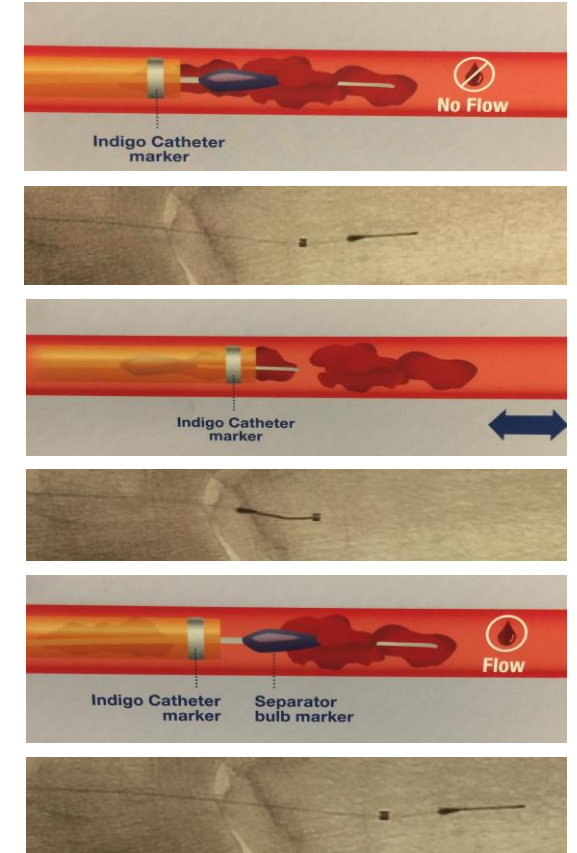

Step by step procedure



Injection of rtPA into the thrombus (wait 10 minutes)



During the waiting time, preparation of the system

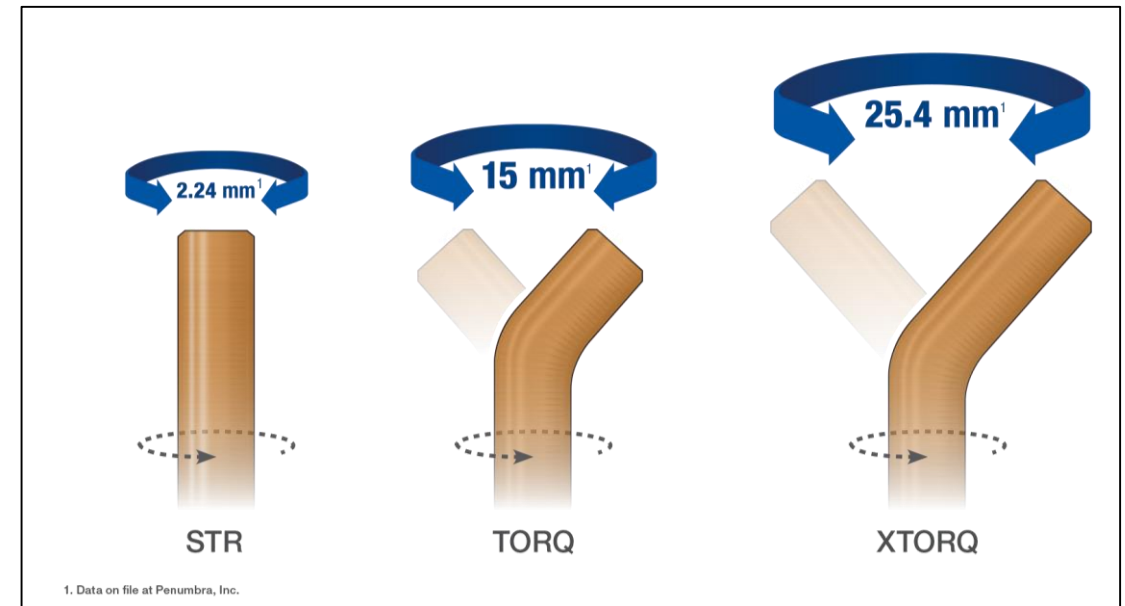
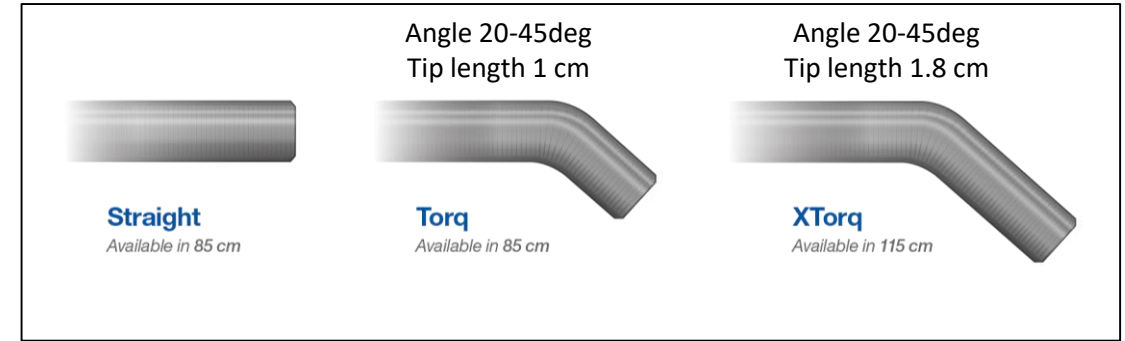
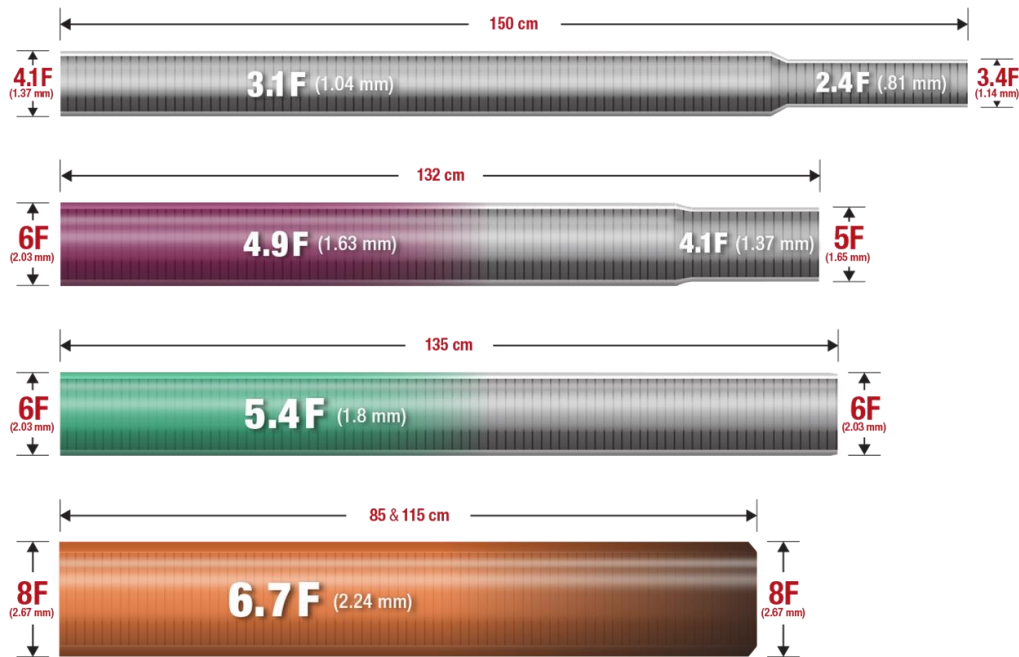


Mechanism of action



Indigo catheters

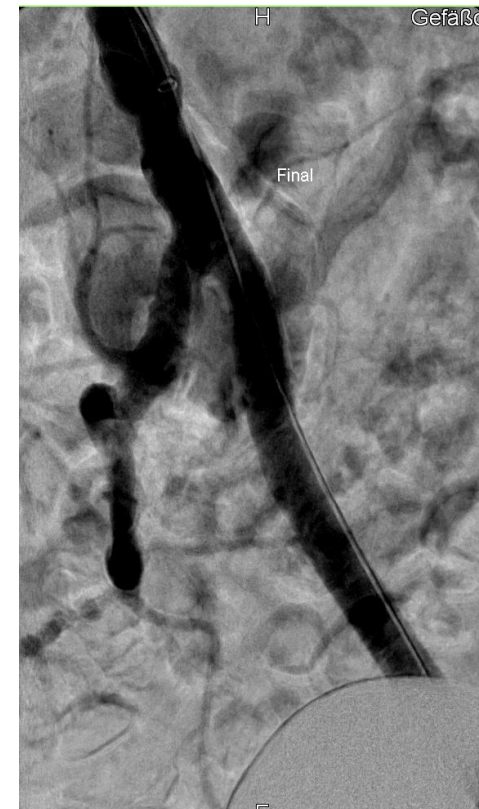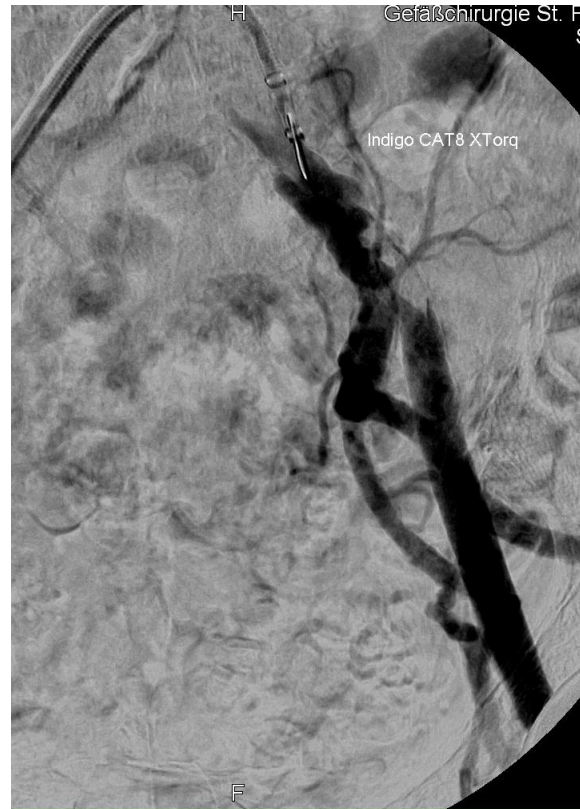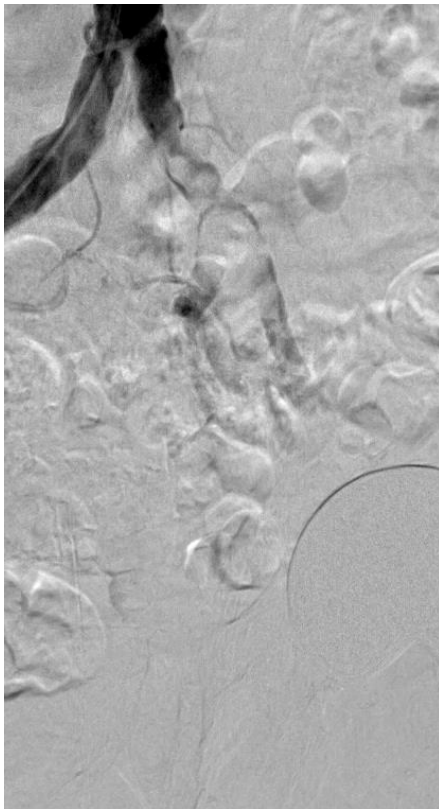
Characteristics



1. Data on file at Penumbra, Inc.

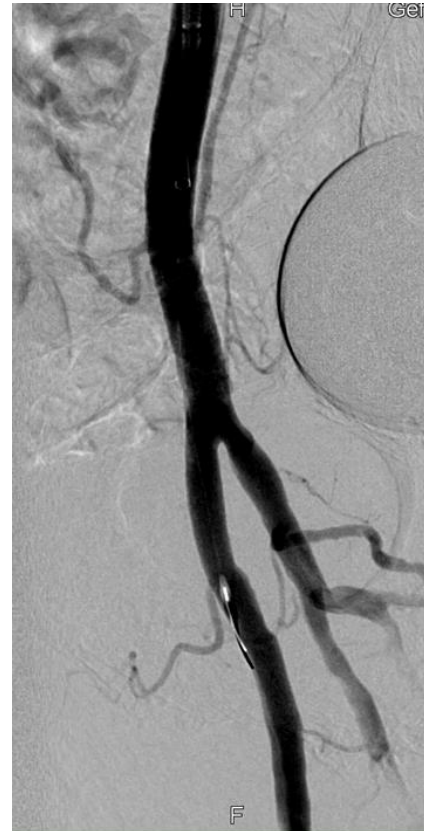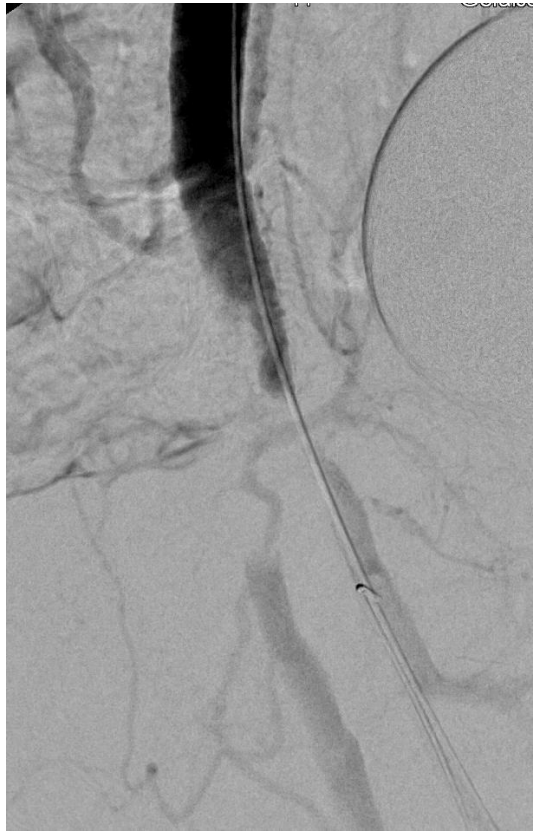Aspiration thrombectomy

Common and hypogastric iliac artery



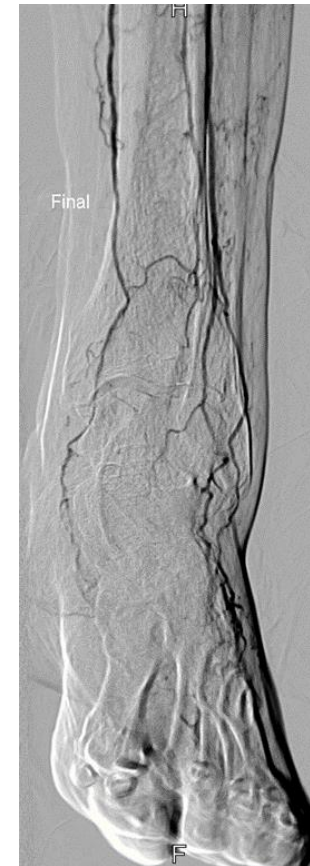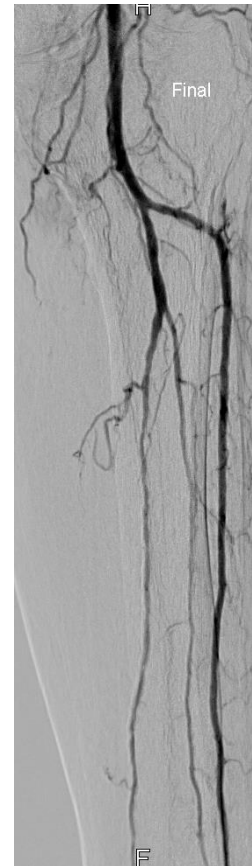
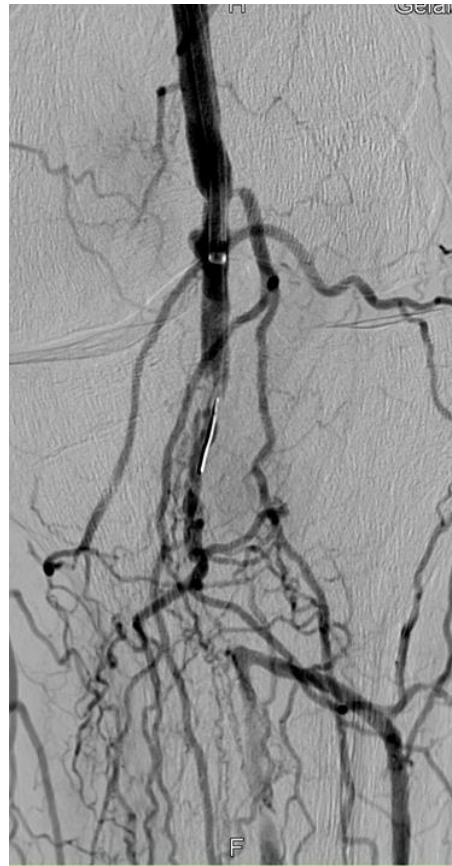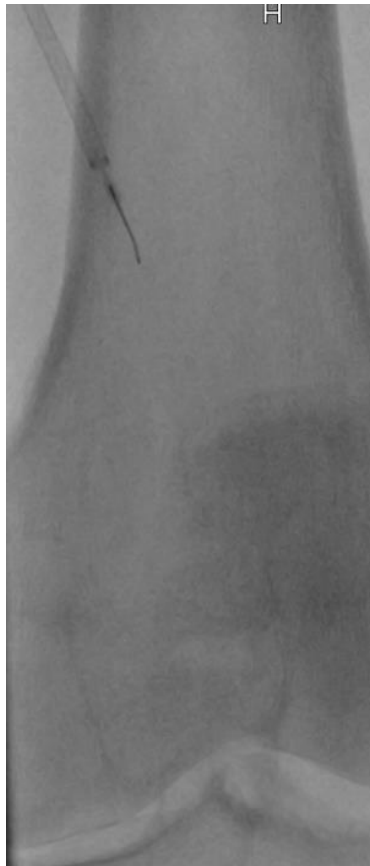
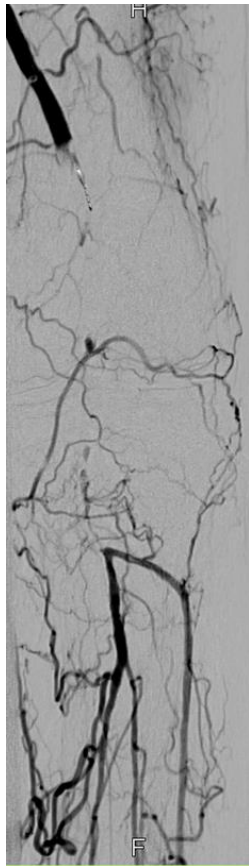
Aspiration thrombectomy

Common and deep femoral artery



Aspiration thrombectomy

Popliteal artery





Questions to Vascupedians

- Do you agree with our treatment strategy?
- Would you have done sth else?
- Do you have experience with the Indigo thrombectomy catheter?
- What is your first-line treatment strategy in acute limb ischemia
- What devices are your first choice for mechanical thrombectomy?